Abstracts

DOI: 10.5301/hipint.5000188

Cup Revision and Bone Reconstruction

GRAFT AND RETAIN: LESIONAL TREATMENT FOR OSTEOLYSIS AROUND WELL-FIXED SHELLS. MEDIUM-TERM FOLLOW-UP

Arman Memarzadeh, Dan Arvinte, Manoj Sood
Department of Orthopaedics, Bedford General Hospital, Bedford - United Kingdom

Introduction: A challenging aspect of revision hip arthroplasty is the treatment of osteolysis. A considerable number of patients with radiographic osteolysis have well-fixed components. Lesional treatment involves retaining the components, grafting the osteolytic areas and changing the bearing surface. It is particularly indicated in younger patients where more extensive surgery is not desirable unless absolutely necessary.
Objectives: The senior author has introduced this procedure into his practice in selected cases and has carefully evaluated it. We present mid-term results.
Methods: Between February 2006 and January 2011, 7 patients (8 hips) with significant osteolysis around well-fixed and orientated uncemented shells, either symptomatic or asymptomatic but radiologically progressive, underwent lesional treatment. There were 6 males and 1 female with average age of 55 (42-63). All had shells with screw(s) and a metal-on-polyethylene bearing. Average time from the index operation to revision was 16 years (9-22). The liner and screws were removed, the lytic area curetted and grafted and a new liner cemented into the shell after roughening of the back of the liner and shell. All patients were followed up clinically (OHS, WOMAC) and radiologically for an average of 5 years (3-8).
Results: Half of the patients (4 hips) showed complete resolution of the osteolytic area on the last follow-up radiographs. For the remaining half the osteolytic area has decreased in size. All patients showed improvements clinically. OHS improved from 14 (7-22) to 32 (19-41). WOMAC score was 57 (45-75) before and 32 (14-59) after surgery. None of them had re-revision.
Conclusions: The timing and appropriate treatment for osteolytic areas around a well-fixed cementless cup is controversial. Lesional treatment and changing the bearing has proved to be effective in well selected cases. We recommend this technique in cases with well-fixed and well-positioned sockets.

CEMENTED REVISION TOTAL HIP ARTHROPLASTY WITH USE OF BOTH ACETABULAR AND FEMORAL IMPACTION BONE-GRAFTING IN PATIENTS YOUNGER THAN 55 YEARS

B. Willem Schreurs, Martijn A.J. te Stroet, Wim H.C. Rijnen, Jean W.M. Gardeniers, Albert van Kampen
Department of Orthopaedics, Radboud University Medical Centre, Nijmegen - The Netherlands

Introduction: The increasing number of total hip replacements in young patients will inevitably generate a larger number of revisions in this age group.
Objectives: The purpose of this study was to evaluate the clinical and radiographic outcomes of cemented revision total hip arthroplasties performed with impaction bone-grafting on both acetabular and femoral side in patients younger than 55 years.
Methods: Between 1991 and 2007, 34 cemented total impaction bone-grafting hip revisions were performed in the first consecutive 33 patients younger than 55 years (average age 46.4 years). No patient was lost to follow-up.
Results: The average follow-up for the surviving hips was 11.7 years (range 5-21). Six hips required a re-revision of one or more components (18%): in 4 patients both components were re-revised, and in 2 only the acetabular component. The survival rate at 10-year for re-revision for aseptic loosening of any of the components was 97% (95% confidence interval (CI), 80-100%) and for re-revision for any reason 87% (95% CI, 68-95%).
Conclusions: Especially in young patients impaction bone-grafting could be a valuable technique to replenish bone stock loss because these patients have a long life expectancy and will survive their implants.

LATERAL MESH CAN BE INSUFFICIENT TO AVOID CUP LOOSENING IN LARGE SEGMENTAL DEFECTS USING IMPACTION BONE GRAFTING IN ACETABULAR REVISION SURGERY

Eduardo García-Cimbrelo, Eduardo García-Rey, Ana Cruz-Pardos
Department of Orthopaedic Surgery, Hospital La Paz, Madrid - Spain

Introduction: Cup migration and bone graft resorption are some of the limitations after acetabular impaction bone grafting (IBG) technique in revision hip surgery when used for large segmental defects.
Objective: We asked whether the use of a metallic mesh may decrease the appearance of this complication. We compared the appearance of loosening in patients with a bone defect 3A or 3B according to Paprosky.
Methods: We assessed 204 hips operated with IBG and a cemented cup according to Slooff et al between 1997 and 2004. There were 100 hips with a preoperative bone defect of 3A and 104 with a 3B. We used 142 medial and/or rim metallic meshes for uncontained defects. The mean follow-up for unrevised cups was 10.4 years. We detemined postoperative radiological cup position and acetabular reconstruction of the hip centre according to Ranawat in both groups. We assessed the appearance of radiological loosening and resorption of the graft.
Results: Postoperative cup position improved in both groups ($p<0.001$ for all parameters). Distance to the approximate centre of the hip decreased from 23.5 to 8.5 mm. Eight hips showed radiological loosening in group with a bone defect 3A and 16 in group 3B. The survival rate for loosening at 15 years was for 83.2 ± 12% for group 3A and 72.5 ± 12% for group 3B (Mantel-Cox, $p = 0.04$). The survival rate when using mesh or not at 15 years for loosening was: No Mesh 89.1 ± 14%, Medial mesh 84.9 ± 12%, Rim 79.6 ± 2%, Medial and Rim 53.9 ± 22 % (Mantel Cox, $p = 0.008$). Patients with a bone defect 3B and a rim metallic mesh had a higher risk for loosening ($p = 0.047$; Hazard Ratio: 2.36, Confidence Interval 95% (CI) 1.01-5.5, and, $p = 0.026$; HR: 3.7, CI 95%: 1.13-12.4, respectively).
Conclusions: IBG provides an improvement of the reconstruction of the rotation of the hip centre in acetabular revision surgery. Although results are good for contained or medial large defects, hips with a rim large segmental defect may need other options for reconstruction of these challenged surgeries.

SINGLE-STAGE REVISION TOTAL HIP REPLACEMENT FOR PATIENTS WITH MASSIVE BONE DEFECTS

Ayman Ebied
Department of Orthopaedics, Menofia University, Shebin El Kom - Egypt

Introduction: Staged revision for infection is highly successful in eradicating infection but associated with loss of the bone stock and other co-morbidities. Single-stage revision may provide a good alternative for patients with extensive bone loss and low-grade infection.
Methods: Single-stage revision THR was performed in 35 patients with peri-prosthetic infection but without a draining sinus. The average age for these patients was 62 years (range 45-75). According to Paprosky's classification, variable degrees of bone deficiencies were present at the acetabular (grade II to IIIB) and femoral (I to IIIA) sides. Preoperative aspiration of the hip was attempted in all patients 2 weeks before surgery. The posterior approach along with an extended trochanteric osteotomy was used in all hips. Revision THR was performed using long cementless fully porous stem and cemented polyethylene acetabular cups. Fresh frozen allograft mixed with 4 grams of antibiotic powder were impacted at the acetabular side and metal cages were used in 14 patients. Patients were prospectively evaluated using the Harris Hip Score (HHS) in addition to radiological assessment. The Paired *t*-test was used to compare pre to postoperative data and Kaplan-Meyer curve for survival.
Results: At an average 5 years postoperative all patients except 1, were free of infection (97% success rate). The extended trochanteric osteotomy had bony union in 33 hips while 2 patients had fibrous union of their osteotomies. The most commonly discovered organisms were the methicillin-resistant Staph., Klibsella and E. Coli. The bone graft has been incorporated and remodelled in all cases. None of the patients was revised or awaiting revision with a Kaplan-Meyer survival of 100% at 5 years. The HHS has improved from 29 preoperative to 79 at the latest follow-up ($p<0.05$).
Conclusions: Single-stage revision using a reverse hybrid implants is an excellent alternative that preserves the bone stock, reduces cost and time of treatment for patients with peri-prosthetic infection. Fresh frozen allograft mixed with a high dose of antibiotics can be used to overcome large acetabular defects.

NEW DEVICE FOR HEALING STIMULATION OF BONE GRAFT. CLINICAL FOLLOW-UP OF 62 ACETABULAR REVISIONS

Hampus Stigbrand, Gösta Ullmark
Department of Orthopaedics, Gävle - Sweden

Introduction: Morcellised impacted bone grafting in acetabular revision is well documented. This study describes a new technique for compression of the impacted bone graft.

Patients and method: There were 62 acetabular revisions in 59 patients, mean age 70 years (45-86). All cases had substantial acetabular bone loss. A total of 21cases had cavitary bone defects, 39 had combined cavitary and segmental defects and 2 cases had pelvic discontinuity. Any segmental defect was repaired by 0.8 mm Titanium mesh from the outside. Morcellised bone graft was impacted by dedicated impaction instruments in the cavitary defects. A 1 mm thick hemispherical and perforated titanium cup was fixed with screws on top of the graft bed for hard compression and stabilisation of the graft bed. The polyethylene cup was cemented in the perforated titanium cup. All patients were included in the follow-up. Twenty-five patients were examined by radiology and clinical examination using the d'Aubigne and Postel score at a mean of 6 years after surgery (3-16 years). Nine patients declined a doctor's appointment for follow-up examination and were assessed by telephone interview. For 14 patients who had died during the follow-up time, medical records were analysed for any further surgery of the hip during the follow-up period.
Results: No patients have had a mechanical failure of the acetabular component at follow-up. Two patients had been re-revised during follow-up, one due to infection and one due to disloctaion. In the case revised for dislocation the bone graft was assessed healed. Two patients have had early migration of the socket (4 mm and 6 mm), 1 had a non-progressive radiolucent line. Three patients have had a hip dislocation and were treated with closed reduction. We believe compression of the impacted graft bed by the screw-fixated titanium cup, will enhance stability and promote bone healing, by adding healing stimulating compression during the postoperative time period.

THE USE OF BIOTECHNOLOGIES IN REVISION OF PROSTHETIC HIP REPLACEMENT

Massimiliano Colombo, Emilio Mazza, Simone Mazzola, Emiliano Malagoli, Giorgio Maria Calori
Reparative Orthopaedic Surgery Department, G. Pini Institute, University of Milan, Milan - Italy

Introduction: The hip arthroplasty implant is currently growing up both in orthopaedic and trauma practice. This increases the frequency of prosthesis revision due to implant loosening often associated with periprosthetic osteolysis that determine the failure and lead to a loss of bone substance.
Nowadays there are numerous biotechnologies seeking to join or substitute the autologous or omologous bone use. These biotechnologies (mesenchymal stromal cells, growth factors and bone substitutes) may be used in such situations, however, the literature doesn't offer class 1 clinical evidences in this field of application.
Materials and methods: We performed a literature review using the universally validated search engines in the biomedical field: PubMed/Medline, Google Scholar, Scopus, EMBASE. The keywords used were: "Growth Factors", "Platelet Rich Plasma", "OP-1", "BMP", "BMP-2", "BMP-7", "Demineralized Bone Matrix", "Stem Cell", "Bone Marrow", "Scaffold", "Bone Substitutes" were crossed with "hip", "revision", "replacement"/"arthroplasty", "bone loss"/"osteolysis."
Results: The search led to 321 items, of these were considered relevant: as regards the growth factors 21 articles related to *in vivo* animal studies and 2 articles of human clinical use of BMPs and 1 single article on the use of PRP; as regards the mesenchymal stromal cells 2 items of application in animals; as regards the use of bone substitutes we have analysed a review of this application.
Discussion: The use of biotechnologies in hip prosthetic revisions has produced conflicting results: autologous growth factors (PRP) have definitely been proven effective in maxillofacial surgery, in animal studies the results of BMPs are inconsistent with articles that validate their use and others that do not recommend it. Clinical application has demonstrated, today, the limited use of BMP-7 in revisions with even an increased risk of early re-mobilisation, PRP appears to be rather effective only in the early stages of peri-prosthetic osteolysis. The mesenchymal cells can increase the chances of recovery and integration of the grafts but an important variable is the number of cells that are still alive after the impaction of the graft which affects their vitality. The bone substitutes appear to be safe and very useful, particularly if applied in order to implement the omologous bone, which is still the most scaffolds used in this surgery.
Conclusions: The systematic review of the literature has shown an important lack of clinical studies regarding the use of biotechnologies for prosthetic revisions. It is therefore difficult to draw guidelines that regulate the application, prospective randomised clinical studies are therefore needed to validate its effectiveness.

BOVINE HYDROXYAPATITE VERSUS SYNTHETIC IN HIP REVISION SURGERY IN OSTEOPOROTIC PATIENTS: CHROME-DENSITOMETRY TC EVALUATION AT 24 MONTHS

Daniele Vanni[1], Simone Massimi[1], Francesco Saverio Sirabella[1], Matteo Guelfi[1], Andrea Pantalone[1], Antonella Cifaratti[2], Giovanni Cannataro[2], Antonio Raffaele Cotroneo[2], Elda Andreoli[1], Alberto Belluati[3], Vincenzo Salini[1]
[1]Orthopaedic and Traumatology Department; [2]Institute of Radiology, Neuroscience and Imaging Department, "G. D'Annunzio" University, Chieti - Italy; [3]Orthopaedic and Traumatology Department, "Santa Maria delle Croci" Hospital, Ravenna - Italy

Introduction: Revision surgery of the hip often causes difficulties related to the management of bone defect, especially in the acetabulum. Although this bone defect often represents the direct cause of prosthetic failure, it can be worsened by an accidental iatrogenic removal of bone material that can occur while removing the prosthesis. In addition, another problem related to the advanced age of the patients is too often underestimated, i.e. osteoporosis. In fact, this disease accounts for a global bone loss, often pre-existing the bone defect itself.
Objectives: Given the different biological and mechanical properties, the purpose of this study is to assess whether there are significant differences between bovine hydroxyapatite (Orthoss®) and synthetic one in the management of bone loss in revision hip surgery in osteoporotic patients.
Methods: Female patients with type II or type III acetabular defect according to Paprosky and with primary osteoporosis diagnosed through DEXA (T-score <-2.5) were enrolled in the study.
Patients were randomly divided into 2 homogeneous samples. Bovine HA and synthetic HA were used in patients of group A and B (control), respectively. Clinical (according to Harris Hip Score) and radiographic (according to the Benson classification) follow-up were performed at month 1, 3, 6, and 12. At month 24 a CT scan with 3D reconstruction and analysis of chrome-densitometry was obtained. The data were analysed by mean of the Kaplan-Mayer curve (results yielding a p-value <0.05 were considered statistically significant).
Results: Based on the Harris Hip Score, there were no statistically significant differences between the 2 groups (p<0.05) up to 12 months, while at month 24, patients in group A showed higher scores. This data can be explained on the basis of the CT results. The 3D reconstructions and chrome–densitometry interpretation showed a better recovery of the bone defect and a consequent more effective osseointegration in group A.
Conclusions: The immediate purpose of revision surgery is to obtain a primary stability of the system. The availability of bone substitutes of non-human origin with macroscopic and microscopic features similar to the homologous graft, represents an important option for treatment of bone defects in revision surgery of the hip. This is even clearer when a bone defect is associated with a poor bone quality. These 2 factors, together, are responsible for an unfavourable synergy that threatens the success of the implant. Although the immediate filling of the cavitary defect may seem a relatively simple aim, the restoration of an acceptable quality of the local bone and osseointegration can be more difficult.
The accessibility to a material easily available, such as hydroxyapatite of bovine origin, suitable for being both "bone graft" and "bone graft substitute", able to allow a proper management of bone defect and, above all, good for a proper osseointegration, represents and essential resource for a good outcome in the medium- and long-term.

MASSIVE STRUCTURAL ALLOGRAFT IN REVISION TOTAL HIP ARTHROPLASTY, MINIMUM FIVE-YEAR FOLLOW-UP

Dariush Savadkoohi, Arash Alirezaei, Mersad Moosavi, Babak Siavashi
Tehran University of Medical Sciences, Sina Hospital, Tehran - Iran

Introduction: One way for filling of acetabular defects in revision total hip arthroplasty is structural allograft with advantages and disadvantages.
Purpose of study: To evaluate the results of the placement of a massive structural allograft in conjunction with a revision total hip arthroplasty.
Materials and methods: A total of 17 patients were evaluated with radiography and clinical exams at a minimum of 5 years after using structural allograft for acetabulum reconstruction.
Results: Ten hips had needed no additional operation, 2 hips had needed a repeat revision but the structural allograft was intact at the repeat revision, and 5 hips had had failure of both the prosthesis and the allograft. The result was considered successful when the hip score had increased at least 20 points, the cup was stable, the allograft had united, and no additional operation was necessary. According to these criteria, the rate of success was 60%.

Conclusions: The findings of the present study support the use of a structural allograft in the presence of massive loss of bone in order to achieve the goals of a revision hip replacement.

EARLY STABILITY AND INGROWTH OF 3D TRABECULAR TITANIUM IN REVISION ACETABULAR RECONSTRUCTION

Amit Patel, Thomas Hayes, Paul Whittingham-Jones, Neil Davies, Tim Waters
The Hip and Knee Unit, West Hertfordshire Hospitals NHS Trust, Hertfordshire - United Kingdom

Introduction: 3D titanium shells and augments have a trabecular ingrowth surface. These demonstrate a high coefficient of friction and large resistance to shear, both enhancing initial stability. The ability to add face changing liners means that anteversion and inclination can be altered after optimum bone fixation has been achieved. Augments can be pre-assembled to the shell allowing the relatively easy insertion of a monobloc construct.
Objectives: To demonstrate positive short- to medium-term outcomes with trabecular titanium in acetabular revision.
Methods: We present 119 consecutive acetabular revisions performed since 2011 using a trabecular titanium system. Pre- and postoperative clinical, radiological and outcome score were assessed at one to three years follow-up.
Results: A total of 119 acetabular revisions were identified. The indications for revision were aseptic loosening (87) infection (19), dislocation/instability (6), metallosis (5) and impingement (2). External augments were used in 19 cases and face changing liners in 41 cases.
At 1- to 3-year follow-up there were no cases of aseptic loosening either clinically or radiographically.
Four cases were subsequently revised for infection (3) and dislocation (1).
The mean preoperative Oxford Hip Score was 24 (IQR 13-33) with a postoperative mean score of 36 (IQR 13-46).
Conclusions: Uncemented acetabular reconstruction relies on initial stability and an ingrowth or ongrowth surface to allow osseointegration. Our large case series of acetabular revision using trabecular titanium shows promising early results. The ability to build a monobloc construct with augments and accurately trial, speeds up the procedure. Face-changing liners, following optimum seating of the component, adds to the versatility of this system.

TANTALUM AUGMENTS FOR THE MANAGEMENT OF SEVERE BONE DEFECTS IN ACETABULAR RECONSTRUCTIONS

Mattia Loppini[1], Guido Grappiolo[2], Umile Giuseppe Longo[1], Francesco Traverso[2], Giuseppe Santoro[2], Giuseppe Mazziotta[2], Emanuele Caldarella[2], Vincenzo Denaro[1]
[1]Department of Orthopaedic and Trauma Surgery, Campus Bio-Medico University, Rome - Italy; [2]Department of Hip Diseases and Joint Replacement Surgery, Humanitas Research Hospital, Milan - Italy

Introduction: Management of severe acetabular bone defects is challenging. The use of tantalum acetabular implants has widely increased because of tantalum excellent biomechanical properties and biocompatibility.
Objectives: To assess the clinical and radiological findings of tantalum-coated cups and tantalum augments in the management of Paprosky type III defects.
Methods: Between February 2005 and January 2011, 64 patients (23 male, 41 female) (65 hips) undergoing acetabular reconstruction with tantalum augments associated with cementless tantalum-coated cups were retrospectively included. Average age was 62.8 years (range 26-86). Bony defects were Paprosky type IIIA in 50 and type IIIB in 15 hips. Average follow-up was 56 months (range 35-105).
Results: The average HHS increased from 39.1 (range 24-52) preoperatively to 89.5 (range 61-100) after surgery ($p<0.0001$). Clinical outcome after surgery was rated as very satisfactory and satisfactory by 55% and 35% of patients, respectively. The average flexion changed from 80° (range 45-100°) before surgery to 115° (range 80-130°) at the last follow-up ($p<0.0001$); abduction changed from 25° (range 10-45°) to 40° (range 20-50°) ($p<0.0001$); adduction changed from 15° (range 0-30°) to 30° (range 15-45°) ($p<0.0001$); internal rotation changed from 10° (range 0-20°) to 20° (range 10-35°) ($p<0.0001$); and external rotation changed from 20° (range 5-30°) to 35° (range 20-45°) ($p<0.0001$). Five (7.7%) hips underwent revision of acetabular components, with a cumulative success rate of 92.3%. Four cases of aseptic loosening (6.2%), and 1 of recurrent instability (1.5%) were reported. Mild/moderate heterotopic ossifications were found in 15 (23%) hips. None required surgical removal.
Conclusions: The use of cementless tantalum-coated cups and augments represents an effective management of Paprosky type III defects in acetabular reconstruction providing a good clinical and radiological outcome in the mid-term.

FIVE-YEAR CLINICAL OUTCOMES AND SURVIVORSHIP OF A THREE-DIMENSIONAL POROUS TITANIUM SHELL IN REVISION TOTAL HIP REPLACEMENT

Rama Ramakrishnan[1], Malkani Arthur[2], Geoffrey Westrich[3], Robert Molloy[4], Eric Garling[5]
[1]Stryker Orthopaedics, Mahwah - USA; [2]SHEA Orthopaedic Group, Louisville - USA; [3]Hospital For Special Surgery, New York - USA; [4]Cleveland Clinic, Cleveland - USA; [5]Stryker Europe, Waardenburg - The Netherlands

Introduction: An acetabular component with three-dimensional porous titanium and anatomic screw holes was developed for revision total hip arthroplasty (THA) in order to provide more reliable fixation that allows the cup to be positioned anatomically.
Objectives: To assess the mid-term clinical and radiographic outcomes, patient reported satisfaction scores, and survival rates of the revision acetabular shell.
Methods: In a prospective multicentre study, 226 revision cases (222 patients) were implanted with a Trident Tritanium Revision cup (Stryker, Mahwah, NJ). Patients with minimum 2 year follow-up were included in this analysis (136 patients, 72 men and 64 women). The mean duration of follow-up was 3.75 years (range 2-5). Mean patient age was 63.7 years, Body Mass Index was 28.5, and 94% had one or more co-morbid medical conditions. In all, 48.5% had Paprosky Type 2 defects and 26.1% had Type 3A defects. Screws were used in 96% of patients and augmentation in 42% of patients.
Results: Mean Harris Hip Score improved from 56.0 preoperatively to 85.6 at 5 years. Excellent or good results were seen in 73% at 5 years. Mean Short-Form -36 Physical Component score improved from 33.8 preoperatively to 43.1 at 5 years. The mean Lower Extremity Activity Scale (LEAS) score was 8.3 preoperatively and 10.2 at 5 years. There were 8 acetabular shell re-revisions reported in the overall study population, 5 of which were for infection, 2 for aseptic loosening and 1 for recurrent dislocation. Kaplan-Meier survivorship for the overall study at 5 years was 94.1% with all-cause revision as the endpoint and 97.5% when aseptic loosening was used as the endpoint.
Conclusions: Next generation acetabular components with highly porous titanium and anatomic screw holes provide for predictable midterm biologic fixation and improved clinical function compared to many historic outcomes. Further follow-up of this cohort will determine if this form of fixation is durable over time.

ACETABULAR REVISION FOR MAJOR PELVIC PROTRUSIO. INDICATIONS FOR AN EXTRA PERITONEAL APPROACH

Jacques Tabutin[1], François Gouin[2], Olivier Gastaud[1], Jean-Alain Epinette[3], Patrice Mertl[4]
[1]Department of Orthopaedic Surgery, Centre hospitalier, Cannes - France; [2]Department of Orthopaedics, Hotel Dieu, Nantes - France; [3]Clinique Médico-Chirurgicale, Bruay-Labuissière - France; [4]Orthopaedic Service, CHU Amiens, Amiens - France

Introduction: In major pelvic protrusio, intra-pelvic elements may be in jeopardy. In severe cases a sub-peritoneal approach might be necessary.
Objectives: We aimed at delineating its indications.
Methods: From a multicentric study collecting 255 cases of protrusios greater than 15 mm, we selected the cases in which such a complementary approach was needed, with the modalities of imaging and the operative strategy.
Results: There were 20 cases (17 men, 3 women) aged 66 (34-85). In all cases an angio CT scan has demonstrated the absence of a bone layer, the deviation of the iliac vessels, their proximity with the cup reinforcement ring or screws. The sub-peritoneal approach, protecting the vessels, was done by a vascular surgeon before the procedure (17 cases), as a first step of the procedure (2 cases), or as an emergency due to bleeding (1 case). No secondary bleeding, ischaemia or venous thrombosis was observed. This allowed for a safe acetabular reconstruction through the usual hip approach, except 2 cases of reconstruction through the iliac approach.
Conclusions: An extra-peritoneal complementary approach to control the iliac vessels was rarely judged necessary (7.8% of cases). It was usually reserved for superior and centred medial protrusio. Generally in major protrusios, there is a thick pseudo membrane at the bottom of the acetabular, separating from the pelvis. When it is a thin bone layer, the reconstruction procedure may be conducted through the hip. If an haemorrhage happens, controlling the bleeding

may be difficult. A two-separated steps procedure remains easy for the vascular surgeon but needs to leave some packing in the iliac fossa and remove it afterwards, a 1-step procedure needs to swing the patient's operative position and do a wide draping. Protecting the iliac vessels is worth an extra operative time.

Resurfacing/Metal-on-Metal

IS LATERAL OPENING OF THE CUP RELATED TO PELVIC TILT ON THE SURGICAL TABLE?

José Cordero-Ampuero, Rubén Fole, Borja López-Hernando, Enrique González-Fernández, Pablo Peñalver, Alfonso Maldonado
Department of Orthopaedic Surgery, Hospital Universitario La Princesa, Madrid - Spain

Introduction: Surgical table and floor are the usual references for positioning the cup. This is correct if pelvis is perpendicular to them (tilt 0°). But if shoulder girdle is wider than pelvic girdle, pelvis will be tilted towards the feet. And if shoulder girdle is narrower than pelvic girdle, pelvis will be tilted towards the head.
Objectives: To analyse pelvic tilt on surgical table ant its influence on lateral opening of the cup.
Methods: Prospective, blind, observational study.
Fifty THA patients (26 female), 1 department, multiple surgeons. Lateral decubitus, horizontal surgical table, conventional anterior (pubic) and posterior (lumbar spine) supports.
Preoperative measures: (with custom-made measuring device) width of shoulder and pelvic girdles, pelvic tilt (angle between horizontal surgical table and a line by both antero-superior iliac spines), pelvic tilt towards head or feet.
Postero-lateral approach. Theoretical position of cup intended by surgeons: 45° valgus.
Post-surgical x-ray: measure of lateral opening of cup.
Results: 21/50 (4 males): pelvic girdle 27 mm wider than shoulder girdle (female phenotype), pelvic tilt 1 ± 7° towards head, theoretical risk of horizontal cup. Radiographic lateral opening of the cup: 43 ± 10º.
3/50 (2 males): pelvic girdle width similar to shoulder girdle, pelvic tilt 7 ± 2° towards feet, theoretical risk of vertical cup. Radiographic valgus of cup: 43.8°.
26/50 (18 males): shoulder girdle 23 mm wider than pelvis (male phenotype), pelvic tilt 1 ± 5° towards feet, theoretical risk of vertical cup. Radiographic valgus of cup: 45 ± 9°.
No result is statistically significant.
Conclusions:
1) Different widths of shoulder and pelvic girdles could theoretically influence pelvic tilt of patients in lateral decubitus on surgical table.
2) But actually most patients present a minor pelvic tilt.
3) The average radiographic valgus of cups is near 45°, but the standard deviation is great and an important number is out of recommended range.

CHANGES IN BONE MINERAL DENSITY IN THE PROXIMAL FEMUR UP TO FIVE YEARS AFTER HIP RESURFACING VERSUS UNCEMENTED TOTAL HIP REPLACEMENT; A RANDOMISED CONTROLLED TRIAL

Davey Gerhardt, José Smolders, Job van Susante
Department of Orthopaedics, Arnhem - The Netherlands

Introduction: A theoretical advantage of using resurfacing hip arthroplasty (RHA) is the preservation of the femoral neck, which may facilitate future revision in especially young patients. Here for femoral bone stock should be preserved without significant femoral neck narrowing (FNN) or decrease in bone mineral density (BMD).
Objectives: To objectify the femoral BMD changes and the onset of FNN after RHA.
Methods: We present our ongoing results with a mean follow-up of 62 months (45-79), on BMD changes and femoral neck narrowing after RHA (n = 42) and small diameter metal-on-metal total hip arthroplasty (MoM THA) (n = 40) in 82 patients. Preoperatively and at 3, 6, 12, 24, 36 and 60 months the BMD was measured in Gruen zone 7 in both groups with dual energy absorptiometry (DXA), in addition the BMD in 4 regions of interest (ROI) of the femoral neck and FNN was measured in the RHA group.
Results: The BMD in the calcar region of RHA patients increased significant up to 107% of baseline levels ($p<0.001$) and this remained stable up to 60 months follow-up. In the THA patients the BMD significantly decreased in this region to 80% at 12 months ($p<0.001$) with stable levels up to 60 months follow-up. As for the 4 ROI in the femoral neck of the RHA patients at 60 months showed BMD values around baseline, between 97.7% and 99.8%. The mean FNN over 60 months follow-up was 1.2% (range -5.3%-7.0%) indicating no occurrence of clinical relevant FNN.
Conclusions: These mid-term results indicate that BMD in the proximal femur is indeed preserved after RHA. In comparison a significant decrease in BMD was observed in the calcar region after THA. The clinical relevance of this proven bone stock preserving nature of RHA has to be weight against potential disadvantages such as higher revision rates caused by specific metal-on-metal bearing problems.

ENHANCING RESISTANCE TO FRACTURE IN HIP RESURFACING - EFFECT OF PIN CEMENTATION

Ulf J. Schlegel[1], Jan Siewe[2], Peer Eysel[2], Michael M. Morlock[3]
[1]Department of Orthopaedic and Trauma Surgery, Heidelberg - Germany; [2]Department of Orthopaedic Surgery, University of Cologne, Cologne - Germany; [3]Biomechanics Section, Hamburg University of Technology, Hamburg - Germany

Introduction: Since the introduction of modern hip resurfacing systems, there has been a controversy regarding the fixation of the centring pin in the femoral component. It has been suggested that cementing the pin may increase strength of the femoral neck. This *in vitro* analysis investigated the influence of a cemented, femoral pin on resistance to fracture in the resurfaced hip.
Objectives: Aim of the study was to investigate whether pin cementation improves resistance to fracture following hip resurfacing in an *in vitro* scenario.
Methods: Five pairs of cadaveric, fresh-frozen femora underwent hip resurfacing using a high viscosity cementing technique. In one side of each pair only the inner surface of the implant was cemented, in the other side, cement was additionally hand-pressurised down the pinhole prior to implantation of the femoral component. Specimen were then mounted on a material testing machine and cyclic loading with increasing load steps was applied until fracture of the femoral neck.
Results: Fracture load was increased ($p = 0.013$) in the cemented pin group (Median = 4200 N) when compared with the cementless pin group (Median = 2800 N). The number of cycles to failure in the group with the cemented pin (Median = 8072) was likewise higher ($p = 0.01$) when compared to the group, in which the pin was not cemented (Median = 5906).
Conclusions: Cementing the pin may provide additional fixation in hips with low bone mineral density or osteonecrotic lesions, as resistance to fracture could be improved in the presented *in vitro* scenario. Although this was shown for a specific hip resurfacing system, this effect might be extrapolated to other, similar implant designs.

Withdrawn

MEDIUM-TERM RESULTS OF THE RECAP HIP RESURFACING SYSTEM - A SINGLE SURGEON'S SERIES

Manish Kiran, Sunil Santhapuri, Dan Arvinte, Manoj Sood
Bedford Hospital, Bedford - United Kingdom

Introduction: Hip resurfacing arthroplasty (HRA) is performed for hip arthritis in active individuals. The functional results and the level of metal ions generated depend on the implant design.
Objectives: To study the outcome of a consecutive single surgeon's series using the ReCap HRA system.
Methods: This is an ongoing prospective study. HRA was performed in active males under 65 years with good bone quality and in pre-menopausal females with adequate bone density proven by a DEXA scan. A pinless femoral jig was used. Defects after femoral head preparation were autografted. Radiographs were analysed for acetabular inclination, notching, neck thinning and change in implant position. Pre-op and follow-up Oxford hip and UCLA scores were recorded.
Results: A total of 72 HRAs were performed in 66 patients with a male: female ratio of 1.64:1 and a mean age of 54.7 years. At a mean follow-up of 5.96 ± 1.33 years there was one revision procedure in this series giving a survivorship of 98.61%. The mean theta angle was 38.21 ± 4.27° and stem-shaft angle was 139.98 ± 6.65°. Femoral neck thinning was observed in 2 cases. It stabilised at 2 years. There was no femoral notching or implant migration. There was a significant improvement in Oxford Hip Score from 15.77 ± 4.33 to 45.67 ± 4.43 ($p<0.001$) and UCLA score from 3.14 ± 0.74 to 7.07 ± 1.16 ($p<0.001$). All patients returned to their normal level of activity. We did not observe any significantly abnormal cobalt or chromium levels at follow-up. One hip developed avascular necrosis at 3 years, with acceptable metal ion levels and no evidence of adverse reaction to metal debris, and was revised to a ceramic-on-ceramic bearing.
Conclusions: The application of strict selection criteria and precise surgery with attention to implant orientation in HRA appear to produce acceptable results. The ReCap hip resurfacing system demonstrated good medium-term results in a cohort of active patients, whom we will continue to monitor in the longer term.

CLINICAL OUTCOMES WITH CORMET HIP RESURFACING ARTHROPLASTY FROM AN INDEPENDENT CENTRE AT A MINIMUM FOLLOW-UP OF 5 YEARS

Rajan Maheshwari[1], Anand Kirwadi[2], Antony Cooper[3], Andrew Bruce[1], Sanjeev Madan[4], Madhavan Papanna[5]
[1]Department of Orthopaedics, Doncaster Royal Infirmary, Doncaster - United Kingdom; [2]Department of Radiology, STH NHS foundation Trust, Sheffield - United Kingdom; [3]Department of Orthopaedics, Doncaster Royal Infirmary, Sheffield - United Kingdom; [4]Department of Orthopaedics, Doncaster Royal Infirmary and Sheffield Teaching Hospitals, Sheffield - United Kingdom; [5]Department of Orthopaedics, Sheffield - United Kingdom

Background: Hip resurfacing with metal-on-metal bearing has been used as an alternative to traditional total hip arthroplasty, especially in young and active patients. Benefits of the procedure include preservation of proximal femoral bone stock and lower dislocation rates when compared to conventional total hip arthroplasty.
Methods: One hundred and ten patients had 116 cormet hip resurfacings under the care of the senior authors between March 2002- January 2009. This was a retrospective study design.
Results: Between March 2002 and January 2009 a total of 116 consecutive Cormet hip resurfacings were implanted in 110 patients at our centre. There were 76 males and 34 females, with 60 right sided, 44 left sided and 6 bilateral procedures. The mean age was 60 ± 7 (49-72) years. The main indication for surgery was primary osteoarthritis. The outcomes measures were Oxford hip scores, SF-12 Health Survey and implant survival. Overall survival was 93.1% at average follow-up of 6.0 ± 1.2 years.
Conclusions: Our study is comparable with published data on Cormet HRA device, but in mid- or long-term when compared with THA the results are unsatisfactory. Further, senior authors are of a opinion that hip resurfacing arthroplasty is not an acetabular bone preserving procedure.

FIVE-YEAR, PROSPECTIVE STUDY OF METAL ION RELEASE FOLLOWING METAL-ON-METAL TOTAL HIP ARTHROPLASTY WITH AN ALGORITHM FOR MANAGEMENT

Scott Slagis, Nebojsa Skrepnik
Tucson Orthopaedic Institute, Tucson - USA

Introduction: Metallic ion release may be related to bearing surface wear, and thus serve as an indicator of *in vivo* performance of metal-on-metal (MoM) articulations.
Objectives: Compare large head MoM hip components with modular MoM and metal-on-polyethylene (MoP) to determine their effects on serum metal ion levels.
Methods: A prospective controlled trial to compare the Large Head ASR (MOM-1), the Ultamet Modularity System (MOM-2), and the Pinnacle System with polyethylene liner (MOP) via clinical, radiographic, and serum metal ion concentration (Co and Cr) measures. A total of 151 patients were enrolled (MoM-1 = 97, MoM-2 = 22, MoP = 32). Clinical, radiographic and serum ion assessments were performed pre-op, and post-op at 6, 12, and 24 months for all patients and 60 months for MoM-1 patients. Post-revision serum ion levels were measured at 1, 3, 6, and 12 months.
Results: In the MoM-1 group,11 patients had significantly elevated ion levels at all postoperative measurements. With outliers and revisions excluded, ion levels decreased dramatically; 86 patients averaged ion levels below 5 PPB at 24 and 60 months. Among MoM-1 patients, 9 outliers required revision and their subsequent ion levels decreased dramatically. Clinical scores improved after surgery in all groups but decreased slightly in MoM-1 patients at 2 and 5 years. Average cup inclination angle did not differ significantly between groups.
Conclusions: We have 5 years of prospectively collected data comparing serum ion levels among MOM and MOP groups, plus 1 year post revision serum ion levels. Average serum ion levels were elevated at all postoperative periods in the MoM-1 group, but this is attributable to a subset of outliers that required revision. We present an algorithm to diagnose and manage patients with MoM THA with evidence that serum ion levels do decrease post revision.

Complications in THA

HYPERTROPHY OF THE TENSOR FASCIAE LATAE MUSCLE AS A COMPLICATION AFTER HIP ARTHROPLASTY. REPORT OF 6 CASES

Juan Miguel Rodriguez-Roiz[1], Jenaro Angel Fernández-Valencia[1], Xavier Gallart[1], Xavier Tomas[2], Guillem Bori[1], Sebastián García-Ramiro[1], Josep Riba[1]
[1]Department of Orthopaedics and Trauma Surgery, Hospital Clinic of Barcelona, University of Barcelona, Barcelona - Spain; [2]Department of Radiology, Hospital Clínic of Barcelona, Barcelona - Spain

Introduction: Hypertrophy of the tensor fasciae latae muscle (HTFLM) is a rare complication after hip arthroplasty, and could be the cause of pain and/or palpable mass.
Objective: To evaluate a series of patients presenting HTFLM after hip surgery.
Methods: We present a retrospective review of all the cases diagnosed of HTFLM at our hip unit from January 2008 to January 2014. Type of surgery performed, symptoms that caused the study and imaging technique characteristics as well as final functional result using Merlé D´Aubigne Score were reviewed.
Results: Six hips (5 patients) were identified. During that period 1,285 primary total hip arthroplasties (THA) were performed, as well as 482 revision hip arthroplasties (RTHA). Five cases occurred after a THA (0.4%), and one case after RTHA (0.2%). The mean age was 62.3 years (range 35-72). Two patients were male, 3 female. All cases presenting HTFLM were operated using Hardinge approach except for one case (Röttinger approach). The diagnosis was established 31.3 months (range 11.9-51.5) after the index procedure. Three cases presented palpable mass and trochanteric pain and 3 complained of lateral hip pain without palpable mass. HTFLM was confirmed by the measurement of the cross sectional area by magnetic resonance imaging (MRI) in two cases, and computerised tomography (CT) in 4 cases. Gluteus minimus and medius showed hypotrophy/atrophy in all the cases. Mean Merlé D´Aubigné Score was 16.6 (range 13-18) at 38 months (range 17.8-59.2) after the index procedure.
Conclusions: Hypertrophy of the tensor fasciae latae after hip arthroplasty is a benign condition that could be mistaken as a tumor when presents as a palpable mass, and must be taken into account for the differential diagnosis of lateral hip pain in a patient with a THA. Although HTFLM has been described as indirect sign of abductors tears, none of the patients in the present series showed abductor tears.

ABDUCTOR BIOMECHANICS CLINICALLY IMPACT THE TOTAL HIP REPLACEMENT DISLOCATION RATE

Eduardo García-Rey, Eduardo García-Cimbrelo, Ana Cruz-Pardos
Department of Orthopaedic Surgery, Hospital La Paz, Madrid - Spain

Introduction: Factors related to the patient, to the implant and to the surgery have been associated to the rate of dislocation for total hip replacement (THR).
Objectives: We ask if the position of the cup and the reconstruction of the abductor mechanism actually lower the THR dislocation rate.
Methods: We assessed 1,414 uncemented primary THRs operated between 2000 and 2014. Radiological cup position was assessed using the acetabular abduction angle, the vertical and the horizontal distance of the cup. Anteversion was measured according to Wilmer and Ing and the reconstruction of the rotation centre of the hip according to Ranawat. The radiographic reconstruction of the abductor mechanism was measured using the lever arm and the height of the greater trochanter.
Results: There were 33 dislocations (2.3%) and 11 hips were revised for recurrent instability (0.8%). Adjusted multivariate regression analysis revealed that a higher postoperative acetabular abduction angle and a higher distance to the anatomic rotation hip centre had a higher risk for dislocation ($p = 0.005$, Hazard Ratio (HR): 1.054, Confidence Interval (CI) 95% 1.016-1.093, and $p = 0.014$, HR: 1.046, CI 95% 1.009-1.084, respectively). We also observed that hips with a higher lever arm had a lower risk for dislocation ($p \leq 0.0001$, HR: 0.927, CI 95% 0.891-0.963).
Conclusions: A proper reconstruction of the hip is essential to decrease the risk for dislocation after primary THR. The weakness of the abductor muscles of the hip may be one of the most important causes for dislocation.

HIGH RISK OF EARLY PERIPROSTHETIC FRACTURES AFTER PRIMARY HIP ARTHROPLASTY USING A CEMENTED, TAPERED, POLISHED STEM - AN OBSERVATIONAL PROSPECTIVE COHORT STUDY ON 1,404 HIPS FOLLOWED FOR A MEAN OF 4 YEARS

Cyrus Brodén[1], Sebastian Mukka[2], Olle Muren[3], Thomas Eisler[3], Henrik Boden[3], Andre Stark[3], Olof Sköldenberg[3]
[1]Department of Orthopaedics, Danderyds Hospital and Karolinska University Hospital, Stockholm - Sweden; [2]Department of Orthopaedics Sundsvall Hospital, Stockholm - Sweden; [3]Department of Orthopaedics, Danderyds Hospital, Stockholm - Sweden

Purpose: The aim of this study was to describe the rate and characteristics of periprosthetic fractures (PPF) in a consecutive cohort of patients treated with a cemented, collarless polished and tapered femoral stem (CPT).
Patients and methods: In a single-centre prospective cohort study, we included 1,404 hips in 1,349 patients (72% females, mean (SD) age 82 (8) years) with primary osteoarthritis (OA) or a femoral neck fracture (FNF) (368 vs 1036) as indication for surgery. Hip-related complications and repeat surgery were assessed after average 4 (range, 1-7) years. A multivariate Cox- regression analysis was used to evaluate risk factors associated with PPF.
Results: A total of 47 hips (3.3%) sustained a periprosthetic fracture at median 7 (2-79) months postoperatively; 87% were comminute Vancouver B2 or complex C-type fractures. The fracture rate was 3.8% for FNF patients and 2.2% for OA patients, OR 5.5 CI 95% (3.8-19.9). Patients >80 years had a higher fracture risk OR 3.3 (1.9-7.6) in both groups.
Interpretation: We found a high incidence of very early PPF in this patient group associated with the CPT stem compared to historical controls. Possible explanation might be that the polished tapered stem act as a wedge, splitting the femur after a direct hip contusion.

REMOVAL OF RESTRICTIONS FOLLOWING PRIMARY THA WITH POSTEROLATERAL APPROACH DOES NOT INCREASE EARLY DISLOCATION

Henrik Husted[1], Anders Troelsen[1], Kristian Stahl Otte[1], Thue Oersnes[1], Steen Ladelund[2], Kirill Gromov[1]
[1]Department of Orthopaedic Surgery; [2]Clinical Research Centre, Copenhagen University Hospital Hvidovre, Copenhagen - Denmark

Background: Patient education and mobilisation restrictions are often applied in an attempt to reduce the risk of dislocation following primary THA. Currently, there are no studies investigating the safety issue of removal of mobilisation restrictions following THA performed using a posterolateral approach. In this retrospective non-inferiority study, we investigate the rate of early dislocation following primary THA in an unselected patient cohort before and after removal of postoperative mobilisation restrictions.
Methods: From The Danish National Health Registry, we identified patients with early dislocation in two consecutive and unselected cohorts of patients, who received primary THA in our institution from 2004-2008 (n = 947) and from 2010-2013 (n = 1,154). Patients in the first cohort were mobilised with functional restrictions following primary THA, while patients in the second cohort were allowed unrestricted mobilisation. Risk of early dislocation (within 90 days) was compared in the 2 groups and non-inferiority analysis with a 1% non-inferiority margin was performed. We also identified reasons for early dislocations in the two groups.
Results: Hypothesis of inferiority by a minimum 1% increase in absolute risk of early dislocation, dislocation within 30 days and multiple dislocations could be discarded. Risk of early dislocation (2.9% vs 3.4%), dislocation within 30 days (2.0% vs 2.1%) and multiple dislocations (1.2% vs 1.8%) was insignificantly reduced in patients mobilised without restrictions. Risk of dislocations that potentially could have been avoided if mobilisation restrictions were observed was similar in both groups (0.4% vs 0.4%).
Conclusions: Removal of mobilisation restrictions from the mobilisation protocol following primary THA performed with a posterolateral approach does not seem to lead to increased risk of early dislocation.

HOW TO DECREASE CUMULATIVE DISLOCATION RISK WITH A CHARNLEY-TYPE PRIMARY TOTAL HIP ARTHROPLASTY. A COMPARATIVE REVIEW OF 320 IMPLANTS WITH A FOLLOW-UP OF MINIMUM 10 YEARS

Jacques Henry Caton[1], Jan Louis Prudhon[2]
[1]Department of Orthopaedics, Lyon - France; [2]Clinique des Cedres, Grenoble - France

Introduction: Mid- and long-term follow-up of Charnley total hip arthroplasty (THA) demonstrated good functional results with 85% survivorship at 25-year follow-up. However dislocation still remains an unsolved problem. Dislocation may occur all along the patient and implant life. The aim of this study is to answer the question: does Dual Mobility Cup (DMC) decrease the dislocation risk?
Method: We report comparative results at 10 years of follow-up of 2 groups of primary cemented Charnley-type THA, 1 with a standard polyethylene cup (group 1, n = 215) and the other one with a DMC (group 2, n = 105).
Results: In group 1, 26 dislocations (12.9%) occurred. In group 2 only one dislocation (0.9%) occurred. This dislocation was successfully reduced by closed reduction, without any recurrence. This difference was statistically significant ($p = 0.0018$). In group 1, reason for revision was recurrent dislocation in 21 cases. Five patients have been revised for other reasons. The global revision rate was 12.9%. In group 2, 2 patients needed revision surgery for aseptic loosening. The global revision rate was 2.1%. This difference was statistically significant ($p = 0.0054$). The goal was reached for the patients of group 2 who had more risks factors of dislocation (age, aetiology, ASA and Devane scores) than those of group 1. When using a DMC, we observed a low rate of dislocation in primary THA (0.9%). This surgical choice seems to be a secure and effective technique in Charnley-type THA, especially in a high risk population.

REVISION THR WITH DUAL MOBILITY CUPS: A GOOD CHOICE TO REDUCE DISLOCATION RATE

Manoj Puthiya Veettil, Christopher Rennie, Douglas Dunlop
University Hospital Southampton NHS Trust, Southampton - United Kingdom

Introduction: Revision THR is a major surgical intervention with varying levels of complexity. Apart from infection, dislocation remains the most important determinant for a good long-term outcome. An implant less subject to dislocation may be able to address some of the aetiological factors while increasing the mechanical resistance to dislocation. Dual mobility concept has the benefit of an effective large head, a non-constrained liner and an increased primary range of motion arc. Various studies with larger series have showed dislocation rate varies from 0-1.5% in primary THR and up to 3.5% for revision surgeries when compared to 1-7% for primary THR and up to 30% with the conventional implants.
Objectives: To find out the incidence of dislocation in revision total hip arthroplasty with dual mobility cups.
Materials and methods: This is a retrospective analysis of 45 patients (36 females and 9 males) who underwent revision THR between 2006-2012 for aseptic loosening with subsequent instability or recurrent dislocations. Mean age at the time of operation was 77.6 years (59-96) with an average follow-up of 52.22 months (12-106). Five patients died due to unrelated causes. Though there was no history of dislocations in those patients they were excluded from the study.

There were 38 single-stage and 2, two-stage revision THR with 6 patients had both components and 34 had only acetabulum revised. Intraoperatively, 18 patients found to have intact abductors, 3 patients had no abductors, 6 patients had dehisced abductors and the remaining 10 had no records of the status of their abductor tendons. A posterior approach was used in all cases.
Results: There were no signs of radiological loosening of the cup or dislocations reported until the last follow-up.
Conclusions: Dual mobility cups may reduce the chance of recurrent dislocation. The overall benefit is the improved patient outcome due to increased primary arc and a stable joint.

FRACTURE OF THE CERAMIC INSERT IN TOTAL HIP ARTHROPLASTY

Ricardo Fernandez-Fernandez[1], Pablo Diaz-Freire[1], Fernando Oñorbe-Sanfrancisco[2], Enrique Gil-Garay[1]
[1]Orthopaedic Surgery, La Paz University Hospital, Madrid - Spain; [2]Orthopaedic Surgery, Infanta Leonor Hospital, Madrid - Spain

Introduction: Alumina Ceramic liners are increasingly used in patients undergoing total hip replacement. Our purpose was to analyse the association between incomplete seating of the ceramic liner and fracture of the ceramic insert.
Methods: We prospectively reviewed 89 hips in 84 patients who had undergone primary total uncemented hip arthroplasty using ceramic-on-ceramic bearing between January 2010 and January 2013. There were 30 women and 54 men, with an average age of 53 years (range 25-73). Preoperative diagnosis included 57 cases of osteoarthritis, 14 cases of osteonecrosis, 5 cases of DHD, 5 cases of Perthes disease, 4 cases of rheumatoid arthritis and 4 cases of post-traumatic arthritis. The minimum follow-up time was 12 months (average 28 months). We investigated whether incomplete seating was present in postoperative radiographs. Cup positioning, restoration of hip centre and osteointegration was also evaluated at 3, 6, 12 months and annually after the index procedure. Clinical evaluation was assessed according to Harris Hip Score.
Results: Six (6.74%) of 89 hips had evidence of incomplete seating. Of these, 2 developed a fracture of the ceramic liner. We found an association between incomplete seating and fracture of the ceramic liner ($p<0.001$). One of these inserts was revised; the other patient is asymptomatic and has refused surgery. Another hip has been revised for infection. No implant has been revised for aseptic loosening and all the cups show radiographic signs of osteointegration. Harris Hip Score improved from 39,6 points preoperatively to 98.8 points at last follow-up ($p<0.001$). There were 4 intraoperative femoral fractures treated successfully by cerclage wiring. There was 1 dislocation treated by closed reduction.
Conclusion Ceramic-on-ceramic hips are a good option in primary total hip arthroplasty for young patients. Wear properties of ceramic bearing provide a durable option. Ceramic is subject to fracture and incomplete seating of the liner is associated with fracture of the ceramic insert.

Primary THA Various

EPONYMS IN ORTHOPAEDIC SURGERY, APPROACHES TO THE HIP

Matthijs Somford[1], Daniël Hoornenborg[2], Jan-Joost Wiegerinck[3]
[1]Department of Orthopaedic Surgery, MST, Enschede - The Netherlands; [2]Department of Orthopaedic Surgery, Slotervaart hospital, Amsterdam - The Netherlands; [3]Department of Orthopaedic Surgery, AMC, Amsterdam - The Netherlands

Introduction: After the low-friction arthroplasty by John Charnley was no longer confined to specialised hospitals but commonplace in general orthopaedic practice, the issue remained how to most optimally reach the hip. Various approaches were already known and others were developed later. The names of the authors of these approaches remain in a lot of cases connected to the approach. These eponyms are commonly used without always the full knowledge of the background of the man behind the eponym and the way the technique was developed.
Methods: By evaluating the original articles in which the approaches are described we ascertain the original description and technique. By various sources, for instance relatives, colleagues or sometimes foundations raised in their honour, we obtain the (short) biography of the people whose name is connected to the approach.
Results: Our research covers the biographies of colleagues Smith-Peterse, Watson-Jones, Hardinge, Charnley, Moore and Ludloff. The eponymous approaches are shown and described after the short biography on each individual. The biography also encompasses the time and circumstances in which the approach was discovered and described
Conclusions: This study shows that without the work of our colleagues we cannot proceed in our profession. The invaluable work of the people discussed is a substantial part of our daily practice and without it we would not be able to perform our surgery the way we do today. An understanding and knowledge of the people who dedicated themselves to developing the orthopaedic surgery to the high standard it has today is the least honour we should give them.

THE EFFECT OF ORTHOPAEDIC SURGERY ON THE INTRINSIC PROPERTIES OF SURGICAL GLOVES

Ali Abdulkarim, Andrew Moriarity, Eoin Sheehan
Midland Regional Hospital, Tullamore, Ireland, Tullamore - Ireland

Introduction: Surgical gloves function as a mechanical barrier that reduces transmission of body fluids and pathogens from hospital personnel to patients and vice versa. The effectiveness of this barrier is dependent upon the integrity of the glove. Infectious agents have been shown to pass through unnoticed glove microperforations which have been correlated to the duration of wear. Varying factors may influence the integrity of the glove such as the material, duration of use, activities and fit. Studies have recommended changing gloves 90 minutes into a general surgical operation, however there are no known EBM recommendations in orthopaedic surgery.
Objectives: The aim of our study was to determine whether the intrinsic properties of sterile surgical gloves can be compromised when exposed to common orthopaedic materials in the operating theatre.
Methods: A total of 20 unused sterile surgical gloves (neoprene and latex) were exposed to blood, bone shavings and cement over 15, 30 and 60 minute intervals. Following each time point, the palmar surface and finger tips of each glove was analysed under the scanning electron microscope (SEM), and were tested for changes in contact angle and tensile properties.
Results: Exposure to cement caused a significant increase in both the neoprene and latex glove porosities at 15 min but no significant further changes at any later time points. The latex gloves had a greater increase in pore diameter than the neoprene gloves. Exposure to cement for 15 min duration significantly decreased the tensile strength of both latex and neoprene gloves. Exposure to either blood or bone shavings did not cause any significant changes in the latex or neoprene glove properties.
Conclusions: This study provides evidence that exposure to cement, a common orthopaedic material, can disrupt the intrinsic properties of the surgical gloves worn in the operating theatre. This can lead to micro or macro perforations putting both the patient and operating room personnel at risk of contamination.

QUALITY OF OUTCOME DATA IN TOTAL HIP ARTHROPLASTY: CUMULATIVE RESULTS FROM CLINICAL STUDIES AND JOINT REGISTRIES OVER 5 DECADES

Christof Pabinger[1], Anna Bridgens[2], Andrea Berghold[1], Paul Wurzer[1], Nikolaus Böhler[3], Gerold Labek[4]
[1]Medical University of Graz, Graz - Austria; [2]The Royal London Hospital, London - United Kingdom; [3]AKH Linz, Linz - Austria [4]Medical University of Innsbruck, Innsbruck - Austria

Background: There have been recent concerns raised regarding the quality of specific hip implant, but there is no previous review of published clinical studies assessing revision rates of all current hip implants since their market introduction 5 decades ago. We evaluated all clinical studies available on current hip implants, and analysed data regarding revision rate and whether a possible developer bias could be found, which has previously been observed with knee arthroplasty.
Methods: Following a systematic review of peer reviewed clinical studies, the clinical studies of all current implants from market introduction in 1962 up to now were compared with arthroplasty registries. The rate of revision of the implant for any given cause was evaluated.
Results: A total of 54 different hip arthroplasty systems were included in the analysis. We followed 92638 primary implants with 4473 revisions over 5 decades. For 28 of the implants (52%), there is insufficient data published regarding revision. In 16 implants (30%) no study with revision for any cause was found. The remaining 10 implants (18%), each had more than 100 revisions published. For 4 of these implants single independent authors were found to significantly bias the literature. The overall revision rates per 100 observed component years from

clinical studies (and joint registries) are 0.4 (0.5) for stems, 0.7 (0.7) for cups and 1.4 (2.1) for resurfacing systems.
Conclusions: In 82% of the current hip implants used, there is a lack of clinical evidence available regarding revision rate and outcome. Inexplicably high revision rates were only published by specific independent users.
Level of Evidence: Level I: Economic and Decision Analyses-Developing an Economic or Decision Model Sensible costs and alternatives; values obtained from many studies; multiway sensitivity analyses

A NATIONWIDE REGISTRY STUDY ON CHARNLEY CLASS AND HEALTH RELATED QUALITY OF LIFE AFTER TOTAL HIP REPLACEMENTS: WOMEN IN CLASS C FAIL TO A HIGHER DEGREE TO IMPROVE THEIR MOBILITY DIMENSION

Max Gordon[1], Paolo Frumento[2], Olof Sköldenberg[1], Meridith Greene[3], Göran Garellick[4], Ola Rolfson[5]
[1]Department of Clinical Sciences at Danderyd Hospital, Karolinska Institute, Stockholm - Sweden; [2]Institute of Environmental Medicine (IMM), C6, Karolinska Institute, Stockholm - Sweden; [3]Harris Orthopaedic Laboratory, Massachusetts General Hospital, Boston - USA; [4]Swedish Hip Arthroplasty Register, Gothenburg - Sweden; [5]Department of Orthopaedics, Institute of Clinical Sciences, Sahlgrenska Academy, University of Gothenburg, Gothenburg - Sweden

The Charnley classification is a comorbidity categorisation tool for walking that organises patients into 3 classes: A) 1 involved hip; B) 2 involved hips; and C) other severe comorbidities. Although this simple classification is a known predictor for health related quality of life (HRQoL) after total hip replacements (THR), there is uncertainty regarding whether A and B should be grouped together and if there are any interactions.
We selected a nationwide cohort of patients from the Swedish Hip Arthroplasty Register operated with THR due to primary osteoarthritis between 2008 and 2010. We modelled the EQ-5D index and the EQ VAS against the self-administered Charnley classification. Confounding was controlled for by preoperative HRQoL values, pain, sex, and age.
We found that each class differs regarding its impact on HRQoL one year after surgery and that it was not useful to split class B. Furthermore we found an interaction between sex and Charnley class C for the EQ-5D index where females in this category failed to improvement in the mobility dimension.
Our results suggests that the self-administered Charnley classification should be used in its full capacity and that it may be interesting to devote special attention to women in Charnley class C.

IS THERE A ROLE FOR THE UNCEMENTED THOMPSON HEMIARTHROPLASTY? A CONSECUTIVE SERIES OF 1,445 CASES

David Morley, Anup Pradhan, Ian Starks, Peter Gallacher, Philip Roberts
University Hospital of North Staffordshire, Stoke on Trent - United Kingdom

Intracapsular fractures account for 60% of femoral neck fractures, of which 80% are displaced. Controversy remains over the implant that should be used to treat these fractures. The Thompson hemiarthroplasty was first reported prior to the use of bone cement. However, much of the literature focuses on its use as a cemented implant.
All patients undergoing hip hemiarthroplasty using a Thompson prosthesis in our institution between April 2005 and December 2010 were identified. This cohort was cross-referenced with patients undergoing revision surgery up to December 2011. Primary outcome was revision to total hip arthroplasty (THA), revision hemiarthroplasty, or excision arthroplasty. Survival rates were calculated.
During the stated period, 1,472 Thompson hemiarthroplasties were performed, of which 1,445 (98.2%) were uncemented. 76% of patients were female and mean age was 82 years. Mean operative time in the uncemented group was 57 minutes and 82 minutes in the cemented group. Thirty-day mortality was 7.1% and 1-year mortality was 28.1%. A total of 46 (3.2%) patients in the uncemented group required revision surgery. 15% of revisions occurred within 30 days of surgery, and 62% within 1 year. Reasons for revision were infection (n = 12), acetabular erosion (12), loosening (9), fracture (7), erosion and loosening (4), dislocation (1) and intraoperative complication (1). Twenty-seven patients underwent revision to THA, 14 to excision arthroplasty, and 5 to revision hemiarthroplasty. The cumulative survival rate was 97.7% at 1 year and 95.2% at 5 years.
This is the largest consecutive series of uncemented Thompson hemiarthroplasties. It is the first reporting survivorship. Five-year cumulative survival rate is comparable with that for the Austin Moore prosthesis.
We feel the uncemented Thompson hemiarthroplasty, with low revision rate, acceptable mortality and survival rates, and the potential for less complex revision, remains a suitable option in a proportion of neck of femur fracture patients.

CEMENTLESS TOTAL HIP ARTHROPLASTY: A BILAYER COATING TO ENSURE CUPS SURVIVAL RATE AS GOOD AS STEMS

André Ferreira
Clinique du Parc Lyon, Lyon - France

Introduction: For uncemented total hip arthroplasty (THA) addition of a hydroxyapatite layer is used in France for nearly 30 years. Survival rate of symmetrical straight stems with hydroxyapatite stabilised by corner effect is good (>95% at 10 years), however survival rate of cups is usually less than 85%.
Objectives: To support osseous fixation of the implant, the placement of an under-layer between the prosthetic substrate and the hydroxyapatite coating makes it possible to obtain a surface landscape that will serve as an "anchoring volume" for newly formed bone. We have previously validated bilayer manufacturing by *in vitro* tests, which proved that surface preparation (corundum blasting) does not change the implant's mechanical properties and that vacuum spraying doesn't affect implants properties, as already described in literature.
Methods: An exploratory study with 150 consecutive THA from June 2001 to March 2005 was done. Radiological and clinical endpoints were evaluated at maximum follow-up.
Results: With an average follow-up of 65 months, no fixation failure was demonstrated from a clinical standpoint. Only 5 revisions were observed, due to infection (1), dislocation (2), neck fracture (1) and impingement (1). Improvement of average PMA score was very significant (from 9.5 to 17.8, $p<0.05$). For stems, the mean Engh score was 23.2. For cups, no migration and no loosening according to Engh criteria were observed. Radiological parameters collected in our study demonstrated an equivalent survivorship of stems comparing to literature and no difference between stems and cups.
Conclusions: In medium-term, a bilayer coating is clinically effective at providing reliable and reproducible cementless tertiary fixation that begins when hydroxyapatite is resorbed as well for acetabula cups and stems and could ensure stability even when mechanical locking is not predominating. THA global survivorship could then be improved.

TWO-YEAR OUTCOMES OF A MULTICENTRE PROSPECTIVE DENSITOMETRIC STUDY ON TRABECULAR TITANIUM™ PERIACETABULAR OSSEOINTEGRATION

Alessandro Bistolfi[1], Leo Massari[2], Araldo Causero[3], Filippo Castoldi[4], Gaetano Gigliofiorito[2], Carlotta Pari[2], Andrea Francescotto[3], Paolo Rossi[4], Davide Deledda[4], Piermario Tosco[4], Pierpaolo Grillo[1], Giulia Carli[5], Silvia Burelli[5]
[1]AO Citta della Salute e della Scienza, Torino - Italy; [2]University of Ferrara, S. Anna Hospital, Ferrara - Italy; [3]University of Udine, S. Maria della Misericordia Hospital, Udine - Italy; [4]Department of Orthopaedics, University of the Studies of Turin, Turin - Italy; [5]Lima Corporate, Villanova di San Daniele del Friuli - Italy

Introduction: Trabecular Titanium™ is an advanced cellular solid designed to mimic the trabecular bone morphology. Its highly porous structure and lower flexural rigidity aid in implant-to-bone stress transfer, minimising the potential for stress shielding and bone resorption.
Objective: Aim of this prospective study is to evaluate osseointegration around Trabecular Titanium™ acetabular cups via dual-emission x-ray absorptiometry (DXA).
Methods: A total of 89 patients (91 hips) underwent primary total hip arthroplasty with DELTA-TT cups (Lima Corporate). Bone Mineral Density (BMD) was determined by DXA according to DeLee and Charnley 3 Regions of Interest (ROI) at 7 days, 3, 6, 12, 24 months. Radiographic and clinical analysis (Harris Hip Score HHS, SF-36) was performed preoperatively and at the same time-points.
Results: Median BMD initially decline from baseline at 7 days (ROI I: 1.44 [1.21-1.67]; ROI II: 1.23 [0.99-1.49]; ROI III: 1.11 [0.85-1.48] g/cm^2) to 6 months (ROI I: 1.27 [1.08-1.52]; ROI II: 1.14 [0.89-1.37]; ROI III: 1.05 [0.73-1.35] g/cm^2). Then, BMD slightly increased in ROI I, the most loaded area, and stabilised in ROI III. After 1 year, BMD increased in ROI II, stabilising at 2-year (ROI I: 1.30 [1.11-1.55]; ROI II: 1.12 [0.96-1.36]; ROI III: 1.04 [0.80-1.25] g/cm^2). Median HHS and SF-36 improved from 48 (39-62) and 49 (37-62) preoperatively, to 99 (96-100) and 86 (79-92) at 2 years, with 96% and 95% statistical significant increase. Radiographic analysis showed evident signs of osseointegration, with superolateral and infero-medial bone buttress, and radial trabeculae in ROI I/II. No radiolucent lines, loosening or osteolytic areas were observed. All cups were stable at 2 years without any revision or failure.

Conclusions: Evaluation of BMD and radiographic outcomes confirmed an effective periacetabular osseointegration at 2 years. Although clinical results and functional recovery are promising, longer follow-up is necessary to evaluate their survivorship.

ONE-STAGE BILATERAL TOTAL HIP ARTHROPLASTY THROUGH HARDING APPROACH: FUNCTIONAL OUTCOMES AND COMPLICATIONS

Farshad Safdari[1], Afshin Taheriazam[1], Hossein Ettehad[2]
[1]Department of Orthopaedics, Milad Hospital, Tehran - Iran; [2]Department of Orthopaedics, Guillan University of Medical Sciences, Rasht - Iran

Introduction: One-stage bilateral total hip arthroplasty (THA) is associated with several advantages including a single hospital stay, a shorter rehabilitation time, and decreased costs per patient. However, concerns about potential increased risk of perioperative complications have limited the use of this strategy.
Objectives: To investigate the outcomes and complications following one-stage bilateral THA through Harding approach
Methods: In a prospective study, 33 patients with ASA class I or II (24 males and 9 women) aged 31.4 ± 14.7 underwent one-stage bilateral THA because of bilateral severe osteoarthritis or avascular necrosis. The operation time, length of hospital stay and occurrence of any complications were recorded. The level of haemoglobin was measured pre- and postoperatively and compared. Also, the functional outcomes were measured using Merle d'Aubigne's score. The patients were followed for 16 ± 10.5 months.
Results: The operation time and the length of hospital stay averaged 156 ± 23 minutes and 5.2 ± 2.4 days, respectively. The haemoglobin level decreased significantly after operation (15.2 ± 3 mg/dL vs 12.2 ± 2.7 mg/dL; p = 0.046). There was no patient with perioperative death, deep venous thrombosis, pulmonary embolism, infection, dislocation, periprosthetic fracture or heterotrophic ossification. No patient required reoperation. One patient developed unilateral temporary peroneal nerve palsy resolved after 3 months. The Merle d'Aubigne's score improved significantly in last follow-up compared to before surgery (9.25 ± 2.9 vs 17.5 ± 0.8; p<0.001).
Discussion: As an appropriate alternative for two-stage bilateral THA, one-stage bilateral THA through Harding approach is an efficient and safe strategy for patients with ASA class I or II requiring bilateral THA.

IS PATIENT BODY WEIGHT IMPORTANT FOR THE CHOICE OF THE MATERIAL FOR THE BEARING ARTICULATION IN ARTIFICIAL HIP JOINTS?

Michael Morlock[1], Elisa Hoenig[2], Arne Hothan[3]
[1]Institute of Biomechanics, TUHH Hamburg University of Technology, Hamburg - Germany; [2]ProSystem AG, Hamburg - Germany; [3]VDI Technology Centre, Berlin - Germany

Introduction: The effect of body weight on the success of arthroplasty replacement of the hip joint is a controversial issue, particularly the question of whether the choice of bearing couple used should be adapted to individual patient characteristics.
Methods: A literature-based meta-analysis of clinical results that referred to patient weight was carried out. The friction of various material combinations under different joint forces was determined experimentally for the most common bearing articulations (28 mm diameter). For the same bearing articulations, a finite element analysis to investigate contact stresses was performed.
Results: A total of 55 papers and abstracts were identified. The literature analysis revealed an increase of unfavourable implant positioning, increased rate of dislocations, and increased rate of noise development for obese patients. The results of the friction measurements do not suggest a material choice adapted to body weight. Contact stresses increased with increasing load (weight) and increasing inclination, especially for hard-hard articulations, but stayed within the limits for the different materials.
Discussion: For obese patients the same argument applies as for patients with normal weight: provided a correct implantation situation can be ensured, ceramic-on-ceramic bearing couples should be favoured from a tribological point of view, especially due to their superior wear characteristics. If a correct implant position cannot be achieved - for example due to the more complicated implant conditions in obese patients -, a hard-soft bearing couple with a ceramic head appears to be preferable to a hard-hard bearing couple. A ceramic head should be favoured since the risk of taper issues of metallic femoral stems is reduced.

BIPOLAR HEMIARTHROPLASTY IN ELDERLY WITH FEMORAL NECK FRACTURE USING ANTERIOR APPROACH: FASTER REHABILITATION, LESS COMPLICATION

SM Javad Mortazavi, Navid Salehi
Joint Reconstruction Research Centre, Tehran University of Medical Sciences, Tehran - Iran

Femoral neck fractures in elderly patients are frequent and represent a great health care problem. Traditionally, hemiarthroplasty for these patients was associated with greater risk of dislocation and complication.
The purpose of this study was to investigate if bipolar hemiarthroplasty for elderly patients with femoral neck fracture through an anterior approach was associated with better outcome and less complications comparing to standard posterior approach.
Methods: During period of January 2010 and January 2013, we performed 45 bipolar hemiarthroplasties in 45 elderly patients with femoral neck fracture. We then compared this group of patients with 45 sex and age matched patients who received hemiarthroplasty through posterior approach.
Results: The mean age of patients was 73.4 years (62-92) in anterior approach group. There were 21 male and 24 female in each of the study and control groups. Patients in control group received higher amount of blood transfusion. In addition, dislocation rate and infection were significantly higher in posterior approach group. Finally, patients in anterior approach had significantly lower postoperative hospital stay and ambulated earlier.
Conclusions: Bipolar hip arthropalsty via anterior approach is a viable option for elderly patient with femoral neck fracture. It is associated with lower complication rate, hospital stay and faster rehabilitation.

Imaging

ARTHROPLASTY SURVEILLANCE: ARE RADIOLOGY REPORTS USEFUL?

Shyam Rajagopalan[1], Diana Perriman[1], Paul Smith[1], T. Neeman[2]
[1]Trauma and Orthopaedics Research Unit, Canberra Hospital, Canberra - Australia; [2]Australian National University, Canberra - Australia

Introduction and aims: Routine postoperative surveillance of lower-limb arthroplasty is widely recommended to identify asymptomatic failure[1]. Inclusion of x-ray review is believed to be important but our experience is that review by the surgeon is overly time consuming. This study aimed to investigate the accuracy of radiology reports and other methods of screening.
Method: One hundred and nineteen x-rays (100 patients) were prospectively reviewed by the Orthopaedic surgeon for radiolucency, osteolysis and evidence of loosening. Another 20 joints (19 patients) were taken from our database (retrospective) with surgeon reported radiolucency, osteolysis and evidence of loosening. Hip resurfacing was excluded. N = 139 joints (119 patients). Radiology reports and outcome scores (Oxford hip/knee, WOMAC and SF-12) were sought for all the patients. The sensitivity and specificity of the radiology reports were assessed against the surgeon's assessment. Model ensemble analysis (Random Forest Modelling) using Oxford, WOMAC and SF12 - knees and hips was performed to assess their predictive power to identify radiographic abnormalities.
Results: Out of 139 joint x-rays (119 patients) the radiologist's sensitivity for detecting abnormalities was 23% with a specificity was 97%. Out of 77 hips the Random Forest Model's sensitivity was 40% and specificity was 71%. Out of 62 knees, the Model's sensitivity was 50% and specificity was 88%. It was observed that Oxford Hip Score was more predictive of hip x-ray abnormalities and that WOMAC scores were predictive of knee x-ray abnormalities.
Conclusions: The results suggest that radiologists are not able to offer an adequately sensitive screening service post arthroplasty (sensitivity 23%). Random Forest Model gave us better prediction but was not optimal (sensitivity for hips 40% and that for knees 50%). Arguably x-ray review by the surgeon is still required but with more data we may be able to use the Model Ensemble method to potentially streamline future surveillance in order to reduce the number of x-rays requiring surgeon review.

1. Smith LK, Cramp F, Palmer S, Coghill N, Spencer RF. Empirical support for radiographic review: a follow-up study of total hip arthroplasty. Hip Int. 2013;23(1):80-86.

PREOPERATIVE TEMPLATING BASED ON DIGITAL IMAGING OF 100 UNCEMENTED TOTAL HIP ARTHROPLASTIES: ACCURACY AND CONCORDANCE STUDY

Ivan Perez-Coto, Fernando Lobera-Molina, Manuel Angel Sandoval-Garcia, Daniel Hernandez-Vaquero
Department of Trauma and Orthopaedic Surgery, San Agustín Hospital, Avilés - Spain

Introduction: Computer assistance is a valuable support, both in the surgery planning as during the implant placement. In the preoperative planning of total hip replacement (THR), digital templating is an accurate method of assessing the component sizes.
Objectives: Our aim was to confirm the precision and reproductibility of a computer assisted preoperative templating method based on digital image in a consecutive series of THR.
Methods: Two independent observers with different experience performed a preoperative measurement of 100 consecutive THRs. Comparing the templating with the size implanted, we analysed the reliability and the reproductibility of the method.
Results: The more experienced observer was 4-22% more accurate than the other. The exact size of the cup was predicted in the 43-60% of the cases (74-96% within ± 1 size). The exact size of the stem was predicted in the 50-61% (78-97% within ± 1 size). The Cronbach coefficient for the cup was 0.977 (intraobserver) and 0.913 (interobserver) and for the stem was 0.961 (intraobserver) and 0.821 (interobserver).
Conclusions: The accuracy was high enough within a reasonable margin with a good intra- and interobsever concordance. We believe this method is useful to predict unexpected limit sizes or to detect errors in instrumentation.

ARE ADDITIONAL ANTEROPOSTERIOR HIP RADIOGRAPHS REQUIRED FOR PRECISE TEMPLATING IN TOTAL HIP ARTHROPLASTY?

Marc Attinger, Kim Kuonen, Viktor Petrov, Klaus Siebenrock, Frank Klenke
Department of Orthopaedic Surgery and Traumatology, Berne - Switzerland

Introduction: Accurate restoration of the physiological biomechanics in total hip arthroplasty improves abductor strength and range of motion. Traditionally, preoperative templating has been performed on anteroposterior (AP) radiographs of the pelvis. More recently, AP radiographs of the hip have been recommended for an accurate restoration of the femoral offset. However, additional x-ray imaging increases the radiation exposure of the patient as AP pelvis templating is still required to restore the leg length and the centre of rotation. We therefore analysed the femoral offset obtained by AP radiographs of the pelvis and the AP radiographs of the hip. Additionally, we created a geometrical model to calculate the theoretical difference of the femoral offset obtained with AP radiographs of the pelvis as compared to AP radiographs of the hip.
Methods: In 53 patients, both anteroposterior pelvis and anteroposterior hip radiographs were obtained as preoperative radiographs for templating of unilateral total hip arthroplasty. Patients position and x-ray beam setting followed a standardised protocol to achieve reproducible projections. All images were calibrated with the KingMark® calibration system and the offset measurements were performed with the validated TraumaCAD software programme (Voyant Health, UK). A geometrical model was created to calculate the theoretical difference of the femoral offset between the AP pelvic and AP hip projection.
Results: The mean femoral offset measured on AP pelvis radiographs was 37.1 ± 4.8 mm and 38.2 ± 6.9 mm on AP hip radiographs (mean difference 1.2 ± 1.6 mm, $p<0.001$). According to our formula, the length of the depicted femoral offset is independent from the projection as long the femoral neck axis is horizonal.
Discussion: The x-ray measurements and the calculation of the geometrical model demonstrated that the difference of the femoral offset obtained with AP radiographs of the pelvis and the hip is negligible. Additional AP hip radiographs add to the patients' radiation exposure without improving the precision of preoperative templating of total hip arthroplasty. Consequently, AP hip radiographs do not seem to be required for routine total hip replacement templating.

MODULARITY AND 3D HIP PLANNING IN PRIMARY TOTAL HIP REPLACEMENT

Ulrich Rebers[1], H.G. Eleveld[2]
[1]Medical Director, International Knee and Hip Centre Malta, Sliema - Malta; [2]Fellow in Orthopaedic Surgery, St. Antonius Hospital, Gronau - Germany

Between 2009 and 2013 CT-scans were performed in a cohort of 400 patients who were to have primary THR. All patients had initial CT scans. These data were analysed using special hip plan software for preoperative planning and selection of implants. The aim of this 3D hip planning was to achieve the most accurate restoration of the hip's rotation centre, offset and the leg length to restore good function. To achieve this, the data of different implant models and stem shapes were deposited in the planning software, thus making it possible to select the appropriate prosthetic components for the reconstruction of the rotation centre, the offset and the leg length to suit every individual patient's anatomical needs. The introduction of preoperative 3D hip planning offers the possibility of a preoperative choice of implants adapted to the individual anatomical needs of a patient. In 42% of the surveyed 3D hip plans a modular stem in different versions was proposed. The survey has shown the advisability of modular implants in primary THR if accurate restoration of the hips anatomy is the aim. For that reason, preoperative 3D hip planning is recommended to enable the surgeon to identify those patients who require modular implants.

VALIDITY AND RELIABILITY OF PLAIN RADIOGRAPHIC MEASUREMENTS AFTER TOTAL HIP ARTHROPLASTY

Sarwar Mahmood[1], Sebastian Mukka[1], Saida Baea[2], Arkan Sayed-Noor[1]
[1]Department of Surgical and Perioperative Sciences, Umeå University, Sundsvall - Sweden; [2]Department of Radiology, Sundsvall Teaching Hospital, Sundsvall - Sweden

Background: In total hip arthroplasty (THA), radiographic preoperative planning and postoperative evaluation of acetabular component, femoral offset (FO) and leg length discrepancy (LLD) require good validity, interobserver reliability and intraobserver reproducibility.
Purpose: 1) Evaluate the validity of the Sundsvall method of FO measurement (femoral axis - pelvic midline) by compring it to a standard FO measurement method (femoral axis - hip rotational centre - tear drop point); 2) Evaluate the interobserver reliability and intraobserver reproducibility of measurement of FO (as mentioned above), LLD (inter tear drop line - lesser trochanter), acetabular cup inclination (on AP view theangle between the cup rim and trans-ischial line) and anteversion (on lateral view the angle between the face of acetabulum and a line perpendicular to the horizontal plane).
Methods: Ninety patients with primary unilateral osteoarthritis (OA) were included in this prospective study. On postoperative radiographs FO by the Sundsvall method, FO by a standard method, LLD, acetabular cup inclination and anteversion were measured. The interobserver reliability and intraobserver reproducibility were made by 3 independent observers. The validity and degree of prediction of Sundsvall method are measured by comparing its results with the standard method.
Results: The interobserver reliability of all measurements was excellent (>0.80), except for LLD which was substantial (0.79). The intraobserver reproducibility of all measurement was excellent (>0.80). The validity of the Sundsvall method compared to the standard method was good with a positive correlation.
Conclusions: The Sundsvall method is as reliable as the standard method. The evaluated radiographic measurement methods have the required validity and reliability to be used in clinical practice.

CHANGES OF PELVIC TILT AFTER TOTAL HIP REPLACEMENT; EVALUATION BASED ON RADIOSTEREOMETRIC ANALYSIS UP TO 7 YEARS

Bita Shareghi, Johan Kärrholm
Department of Orthopaedics, Sahlgrenska University Hospital, Mölndal - Sweden

Introduction: The pose of the prosthetic components after operation with total hip replacement (THR) is commonly evaluated on conventional radiographs. Any change of pelvic tilt after the operation in the supine position and between the supine and standing position in the postoperative period will influence validity of the measurements.
Aim: To assess the change in pelvic tilt angel in the supine and standing positions.
Patients and methods: Stereo radiographs of 55 (55 hips, 55 yrs) patients with primary or secondary osteoarthritis who underwent THA between 1998 and 2005 were studied. Tantalum markers inserted into the acetabular during the operation were utilised for the purpose of this study. All hips had been examined supine and standing postoperatively, at 6 months, 1, 2 and 7 years after surgery. The measurements and analysis of all radiographs were performed with UmRSA Digital measure and UmRSA Analysis 6.0. Pelvic rotations about the transverse axis (anterior/posterior pelvic tilt) were analysed.
Results: The mean change of pelvic tilt in the supine position during the follow-up varied between -2.4 ± 3.0° (range -10.5-4.24°) to -2.9 ± 2.7° (range -8.75-5.25°) without any difference up to 7 years. The change of pelvic tilt from the supine to

the standing position tended to increase with time. At 6 months an anterior tilt was observed (3.5° ± 3.7°, range -3.41-12.2°) which had increased to 6.5 ± 3.9° (range -1.80-17.8°) at years. The female patients showed a larger anterior tilt from the supine to the standing position (p = 0.02). There was no difference for pelvic tilt in the supine position between the genders (p = 0.17).
Conclusions: We did not find any differences in pelvic tilt in the supine position during the follow-up. The anterior tilt increased from the supine to the standing position in all cases. Females showed a higher difference in anterior tilt between supine and standing position.

DOES ROBOTIC-ASSISTED COMPUTER-NAVIGATION AFFECT ACETABULAR CUP POSITIONING IN TOTAL HIP ARTHROPLASTY IN THE OBESE PATIENT? A COMPARISON STUDY

Christine Stake[1], Parth Lodhia[1], Jon Hammarstedt[1], Alexandra Petrakos[1], Kevin Dunne[1], Benjamin Domb[2]
[1]American Hip Institute, Westmont - USA; [2]Hinsdale Orthopaedics and American Hip Institute, Westmont - USA

Background: Studies have shown challenges of acetabular cup placement during total hip arthroplasty (THA) in obese populations. Robotic-assisted computer-navigation can be accurate and reproducible for acetabular cup placement.
Purpose: This study examines the accuracy of acetabular cup inclination and version with respect to the Lewinnek and Callanan safe zones in the obese patient with robotic-assisted computer-navigation.
Methods: A total of 105 patients underwent robotic-assisted computer-navigation THA with posterior approach. For class I obesity, 59 patients had BMI <30 and 46 patients with BMI ≥30 were compared. Stratified by class II obesity, 93 patients had BMI <35 and 12 patients with BMI ≥35.
Results: The BMI <30 group had a mean acetabular cup inclination of 39.86° and version of 16.78°. The BMI ≥30 group had a mean acetabular cup inclination of 40.04° (p = 0.77) and version of 16.95° (p = 0.82). Stratified by class II obesity, the BMI<35 group had a mean acetabular cup inclination of 39.80° and version of 16.87°. The BMI ≥35 group had a mean acetabular cup inclination of 41.02° (p = 0.195) and version of 16.73° (p = 0.905).
Conclusions: Robotic-assisted computer navigation provides accurate and reproducible placement of the acetabular cup within safe zones for inclination and version in the obese patient.

DEFINING THE ANATOMIC RANGE OF SHORT-STEM IMPLANTATION - CALCARGUIDED RESTORATION OF INDIVIDUAL CCD-ANGLE

Mark-Predrag Kovacevic, Karl Phililpp Kutzner, Philipp Rehbein, Joachim Pfeil
Orthopaedic Department, Wiesbaden - Germany

Introduction: Short-stem prostheses are an emerging group of implants in total hip replacement. However their use is often limited to a certain population. Most short stems have limitation in restoring high offset type as well as extreme varus and valgus hips. New calcarguided and metaphyseal-filling short stems could widen the spectrum of indication.
Goal: The aim of the study is to evaluate the CCD-bandwidth and radiological changes of CCD-angle in patients with a new neck-preserving short stem.
Method: Prospective inclusion of 114 consecutive patients with unilateral hip disease eligible for short-stem implantation. Preoperative digital templating approved the implantation of optimys short stem (Mathys, Switzerland) in all patients. One hundred and nine hips were available for radiologic measurement. We analysed postoperative changes regarding the individual CCD-angle using standardised radiographs of the plain pelvis.
Results: Digital preoperative templating approved implantation of the optimys short stem prosthesis in all 114 patients. Four patients were lost to follow-up, 1 patient suffered intraoperative femoral perforation and was implanted a standard stem. Patients' CCD-angles varied from 115° to 147° (av. 130.3°), CCD-angles in templating varied from 124° to 137.4° (av. 130.8°). The postoperative measurements showed CCD-angles from 117.9° up to 146.7° (av. 131.4°).
Conclusions: Preoperative templating confirmed the optimys short stem in all patients for restoring individual anatomy. The accuracy of postoperative reconstruction of the individual hip geometry is remarkably high for varus hips as well as for valgus hips indicating a wide range of indications regarding CCD-angle. The results support our experience of high coverage of the short stem over all our patients.

EFFECT OF FEMORAL OFFSET LOSS ON MUSCLE MOMENT ARMS IN TOTAL HIP ARTHROPLASTY: A 3D BIOMECHANICAL ANALYSIS

Hannes A. Rüdiger[1], Valerie Parvex[2], Alexandre Terrier[2]
[1]Department of Orthopaedics, University of Lausanna - CHUV, Lausanne - Switzerland; [2]Laboratory of Biomechanical Orthopaedics, Ecole Polytechnique Fédérale de Lausanne EPFL, Lausanne - Switzerland

The importance of an accurate femoral reconstruction for a good functional outcome is well documented. However, quantitative data on the effect of offset changes on muscle moment arms are scarce. The purpose of this study was to calculate the impact of a loss of 20% of femoral offset on abductor moment arms in a 3D numerical model of the hip.
Methods: Preoperative CT scans of 15 patients undergoing total hip arthroplasty were used to build 15 patient-specific finite elements models. Each model included the pelvis, the femur, a total hip prosthesis, and the gluteus medius, minimus and maximus. The femur and pelvis were assumed rigid, as the prosthesis. A hyperelastic deformation law was used for the muscles. In each case, abductor moment arms were calculated during passive flexion-extension and abduction-adduction within a range of motion observed during a gait cycle. These muscle moment arms were calculated in two cases: 1) an ideal anatomical reconstruction of the hip; 2) a reconstruction of the hip with 20% loss of femoral offset. Assuming that 20% loss of femoral offset might result in a maximum loss of abductor moment arm of the same distance in millimeters, the changes of moment arms from case 1 to case 2 were normalised with this effect value for each patient, and reported as a percentage.
Results: Among all patients, the anatomical femoral offset was 37.9 ± 7.4 mm. A loss of 20% of femoral offset corresponded to a loss of 7.6 ± 1.5 mm (from 5.5 to 10.3 mm). In average, a loss of 20% of offset led to a loss of abductor moment arm of 58%. This effect was more pronounced for the gluteus medius than for the gluteus minimus. In average, a loss of 20% of offset led to a loss of flexion moment arm of 25%. Of note, the 20% offset decrease could change some muscle fibres from an agonist to an antagonist action during flexion. In contrast, for abduction, all muscle fibres maintain agonist after a 20% offset loss.
Conclusions: In summary, the loss of muscle moment arm was approximately half the loss of the femoral offset. In addition, some muscle fibres became antagonist. Therefore, a 20% loss of femoral offset might have a negative impact on proprioception.

EFFECT OF ACETABULAR REAMING TECHNIQUE ON DISPLACEMENT OF THE CENTRE OF ROTATION

Janjaap Kats, Jacco Van Doorn, Geert Meermans
Department of Orthopaedics, Lievensberg Hospital, Bergen Op Zoom - The Netherlands

Introduction: The goal of total hip arthroplasty (THA) is to restore normal hip anatomy. Correct restoration of the offset leads to improved abductor strength, better range of motion, less impingement, increased stability, less polyethylene wear, and less aseptic loosening. Traditionally, reaming of the acetabulum is initiated directly medial to the floor and followed by sequentially larger reamers which could lead to loss of acetabular offset.
Objectives: The goal of this study was to compare displacement of the centre of rotation (COR) using this conventional reaming technique with a technique in which the cup is not deliberately medialised and the acetabulum is reamed immediately peripherally and referenced of the rim.
Methods: We compared two cohorts of 50 patients with primary osteoarthritis that underwent THA. In the first cohort (group F) the acetabulum was reamed to the floor followed by sequentially larger reamers. In the second cohort (group P) the acetabulum was reamed peripherally, starting with a reamer the same size as the native femoral head. Reaming was done until sufficient subchondral or cancellous bone has been exposed to ensure bone in growth. In all patients a hemispherical cementless porous coated acetabular component was used. Postoperative anteroposterior pelvic radiographs were analysed for acetabular floor depth (FD) (teardrop to femoral head) and displacement of COR.
Results: The mean preoperative FD (7.9 and 7.7 mm), vertical (13.2 mm and 11.7 mm) and horizontal offset (91.0 mm and 92.4 mm) were similar in both groups. Pre- and postoperative vertical and horizontal offset (mean 14.1 mm and 90.3 mm respectively) were similar in group P, but significantly different in group F (mean 16.0 mm and 87.0 mm respectively; p<0.001). The mean displacement of the centre of rotation medially was 0.7 mm (range -2-3) for group p and 5.5 mm for group F (range -2-13). In group F, there was a strong correlation between the FD and medial displacement of the COR (r^2 = 0.85; p<0.0001).

Discussion: Reaming the acetabulum to the floor can lead to significant displacement of the COR medially and superiorly. In patients with greater FD, surgeons should ream the acetabulum more conservatively to avoid inadvertent medialisation of the COR.

THE INFLUENCE OF HIP CIRCUMFERENCE ON CUP INCLINATION ANGLE

Geert Meermans[1], Ilja Goetheer-Smits[1], Robert Lim[2], Jacco Van Doorn[1], Janjaap Kats[1]
[1]Department of Orthopaedics; [2]Department of Radiology, Lievensberg Hospital, Bergen op Zoom - The Netherlands

Introduction: Malpositioning of the acetabular cup has been linked to an increased rate of dislocation, liner fracture, and increased wear.
Objectives: The aim of this study was to compare the operative inclination angle (OI) and the postoperative radiological inclination angle (RI). The influence of patient morphology on pelvic tilt and cup inclination angle and the usefulness of a radiograph in lateral decubitus position were determined.
Methods: One hundred consecutive patients undergoing uncemented primary total hip arthroplasty in the lateral decubitus position using a posterior approach were included. The cup was inserted and OI was measured with the aid of a digital inclinometer. Six weeks postoperatively anteroposterior standing and lateral decubitus pelvic radiographs were made. RI on both radiographs and pelvic tilt in lateral decubitus were measured by 2 evaluators blind to the OI. After the first 25 patients, surgeons were given feedback on cup position. The results of RI of the subsequent cohorts of 25 patients were compared.
Results: The mean OI was 25.5° (SEM 0.57) which was significantly different from the mean RI of 37.6° (SEM 0.70) ($p<0.0001$). The difference between the radiographic and operative inclination angle (ΔRI-OI) ranged from 3.8 to 19.8°. The mean pelvic tilt was 4.0° (SEM 0.6) of adduction. Linear regression analysis demonstrated that RI was positively correlated with OI ($r^2 = 0.44$, $p<0.0001$). Pelvic tilt was negatively correlated with hip circumference ($r^2 = 0.20$, $p = 0.002$) and ΔRI-OI ($r^2 = 0.37$, $p = 0.0001$). When taking into account pelvic tilt in lateral decubitus as part of ΔRI-OI, the mean difference was 8.2° (range -7.9 to 20.2°) ($p<0.0001$). The mean OI and RI were significantly greater in the first cohort (27.0° and 39.0°) compared with the next cohorts of 25 patients (23.9°and 36.3°) ($p = 0.006$ and 0.02 respectively). There was a greater variance in RI in the first cohort compared with the next cohorts (range 27-50° and 30-44°) ($p = 0.03$) and more cups were placed outside the inclination angle safe zone (6 versus 0; $p = 0.009$)
Discussion and Conclusions: The mean ΔRI-OI was 12.1°. Pelvic tilting in the frontal plane measured on a lateral decubitus pelvic radiograph accounted for part of this difference. In patients with a larger hip circumference there was less pelvic tilt in the frontal plane and less ΔRI-OI. Surgeons using the posterior approach in lateral decubitus should aim for a lower OI in order to achieve the target RI, especially in patients with a smaller hip circumference.

INCIDENCE OF PSEUDOTUMORS IN 'HIGH RISK' CERAMIC-ON-POLYETHYLENE TOTAL HIP ARTHROPLASTY SCREENED WITH MARS MRI

Dirk Das[1], Jorgen Wullems[1], Koen Brakel[2], Rob Nelissen[3], Walter van der Weegen[1]
[1]Department of Orthopaedic Surgery; [2]Department of Radiology, St. Anna hospital, Geldrop - The Netherlands; [3]Department of Orthopaedic Surgery, Leiden University, Leiden - The Netherlands

Background: Recent studies using metal-artifact reducing sequence software for magnetic resonance imaging (MARS-MRI) in metal-on-metal total hip arthroplasty (MoM-THA) revealed high percentages of soft tissue changes around the hip. Most studies addressed this pathology as adverse tissue reactions to metal debris including pseudotumours. Case reports on these pseudotumours have also been reported conventional THA bearings. However, there is no baseline information on such abnormalities in non-MoM THA.
Objective: To establish baseline data on occurrence and details of pseudotumours or other abnormalities in a cohort of patients with ceramic-on-polyethylene (CoP)-THA with high pseudotumour risk.
Methods: A cross-sectional study in a cohort of 50 CoP-THA (3 subgroups; Group 1: 8-12 years follow-up and a high wear rate (>0.2 mm per year), n = 20; Group 2: 5-8 years follow-up (FU) and a high wear rate, n = 20; Group 3: 1-5 years FU and history of persistent complaints but with adequate THA positioning and no clinical signs of infection, n = 10). Clinical examination, blood analysis and MARS-MRI scanning was done in all patients.
Preliminary results: Currently, 36 MRI scans were performed (group 1: 20, group 2: 9, group 3: 7). Only 8 were normal (22%). Extensive acetabular cysts were seen in 12 scans (33%), trochanteric cysts were seen in 9 cases (25%). Except for one, all these were seen in patients with >8 years FU. In 10 scans fluid in the iliopectineal bursae (28%) was observed. Five scans showed fluid in the trochanteric bursae (14%). There were only 2 cases with cysts that resembled pseudotumours as seen in MoM-THA (6%). The remaining 14 cases will be completed in April 2014.
Conclusions: MARS-MRI scanning in CoP-THA shows a high percentage of pathology (78%), however only 6% resembled pathology seen in MoM. MARS-MRI can clearly address intra-osseous cysts and soft tissue surrounding the hip. Pseudotumour-like abnormalities are also seen in CoP-THA but less than with MoM-THA.

Short Stems

PRIMORIS: A NEW SHORT FEMORAL NECK PROTHESIS - DESIGN RATIONALE AND 1-2 YEARS CLINICAL RESULTS

Poul T. Nielsen[1], Gordon Blunn[2], Mogens B. Laursen[1]
[1]Northern Ortopaedic Division, Aalborg Universitetshospital, Aalborg - Denmark; [2]University College London, RNOHT, Stanmore, London - United Kingdom

Introduction: The Primoris femoral stem was designed to preserve bone and maintain normal stress to the proximal femur, thereby minimising stress-shielding and maximise the potential for successful possible future revision.
The implant is anchored in the femoral neck and metaphysis without diafysial involvement and differs from other neck prothesis by:
a) elliptical shape to fit the inner neck dimensions;
b) on top of Ti-porous-coating electrochemically deposited hydroxy apatite (Bonemaster®);
c) the surgical technic aims to enhance initial implant stability by compaction of neck and metaphyseal cancellous bone.

Objectives: As part of stepwise introduction to monitor the early clinical and radiographic results in a pilot series.
Methods: A prospective cohort study of 52 patients (φ ≤55 years, φ ≤65 years) with end-stage non-inflammatory osteoarthritis and no anatomical abnormality. Clinical data (HSS score and verbal satisfaction score) were collected regularly and compared with patients who in a previous study had a conventional femoral stem (Bimetric®).
Results: Two patients were excluded during surgery (one major neck deformity, one insufficient bony support). One neck fracture (not compromising implant stability). One was revised in the follow-up period (aseptic loosening). The mean HSS score increased from 54 (median) preoperatively to 95 at 1 year and 95 at 2 years (20 patients). These results favourably compared with the Bimetric group. Assessed from plain radiographs one implant migrated >5 mm (case revised). Patient satisfaction was high (94%).
Conclusions: In this first publication of a new neck and metaphyseal anchored femoral hip implant we found the early clinical results encouraging and favourably comparable to the clinical results with a conventional uncemented femoral implant. As part of the stepwise introduction process this clinical step I study justifies further clinical evaluation before the implant is introduced in a wider population.

PERIPROSTHETIC BONE MINERAL DENSITY AFTER TOTAL HIP ARTHROPLASTY WITH AN AMISTEM OR QUADRA FEMORAL COMPONENT PERFORMED BY A MINIMALLY INVASIVE ANTERIOR APPROACH (AMIS): A PROSPECTIVE RANDOMISED CLINICAL DUAL-ENERGY X-RAY ABSORPTIOMETRY STUDY

Gerasimos Petridis[1], Martin Nolde[1], Jürgen Beck[2], Michael Scherer[3], Thomas Perneger[4]
[1]Department of Orthopaedics and Traumatology, Munich - Germany; [2]Department of Orthopaedics and Traumatology, Dillingen a.d. Donau - Germany; [3]Department of Orthopaedics and Traumatology, Dachau - Germany [4]Department for Medical Statistics, Geneva - Switzerland

Background: This prospective 12 months dual energy x-ray absorptiometry (DEXA) study evaluated differences in periprosthetic bone mineral density in 40 patients undergoing cementless total hip arthroplasty (THA) by a minimally invasive anterior approach (AMIS), using Medacta AMIStem or Quadra stems. Both stems are straight rectangular: AMIStem shows a reduced lateral flare and length in comparison to Quadra.
Objectives: The main goal of the study is to verify if the bone mineral density is equivalent with the AMIStem and Quadra femoral component.

Materials and methods: Forty patients were allocated randomly to the Quadra andAMISstem groups. Three patients were lost to follow-up and revision surgery was performed on 1 patient due to periprosthetic fracture after a car accident. Patients were examined clinically and underwent DEXA preoperatively and at 1 week, 6 weeks, 6 months and 1 year after THA. Patients enrolled had one lower limb arthroplasty and no osteoporosis.
Results: The Harris Hip Score increased significantly for Quadra stem from 54.3 ± 11.8 to 95.0 ± 6.1 and AMIStem from 45.3 ± 13.6 to 96.3 ± 7.3. The High Activity Hip Score increased significantly for Quadra stem from 6.3 ± 2.3 to 10 ± 2 and AMIStem from 6.4 ± 2.3 to 10.5 ± 2.4. Considering 0.15 mg/cm^2 as acceptable treatment difference, bone mineral density for AMIStem and Quadra groups was statistically equivalent with maybe higher values for Gruen zones R2 and R7 at 6 months and 1 year for AMIStem group. A limited remodelling process with slight bone loss in the proximal calcar region R7, as expected after implantation of uncemented components, was observed for both stems.
Conclusions: The study demonstrates that the 2 stems are statistically equivalent in all zones at any time-point, with the exception of Gruen zone R2 and R7, for which a positive trend for AMIStem was recorded after 6 months and requires further investigations to be confirmed.

PROMISING MIGRATION PATTERN AT 1-YEAR FOLLOW-UP OF THE SHORT PRIMORIS FEMORAL STEM

Mogens Berg Laursen[1], Janus Duus Christiansen[1], Gordon Blunn[2], Poul Torben Nielsen[1]
[1]Northern Ortopaedic Division, Aalborg University Hospital, Aalborg - Denmark; [2]University College London, RNOHT, Stanmore - United Kingdom

Introduction: In order to save proximal bone stock in primary total hip arthroplasty (THA), short femoral stems are introduced.
Objectives: Designed for perfect fit within the femoral neck, the Primoris® femoral stem has been released for clinical studies in coherence with the stepwise introduction of new implants. This is the preliminary report of the Radio Stereometric Analysis (RSA) results after 1-year follow-up (FU).
Methods: We carried out a prospective cohort study of 52 patients scheduled for surgery with the femoral neck-preserving Primoris® stem. Migration was analysed by RSA, and the Harris Hip Score, UCLA activity score, WOMAC, EQ5D health questionnaire and Oxford hip scores were recorded.
Results: Two patients were excluded intraoperatively and 1 patient was revised due to aseptic loosening after 3 months, leaving 47 patients for analysis. Further 2 patients were excluded from the RSA analysis due to technical problems. RSA showed minor micromotion of the stem: mean subsidence was 0.35 mm (precision: 0.10) and mean rotation around the longitudinal axis was 0.10º (precision: 0.64) after 1 year.
Conclusions: The stems showed very small migration - as it is characteristic for stable uncemented implants. If they stay stable until the 2-year FU, we will go on with a multi-centre study.

THE SILENT "NECK ONLY" HIP PROSTHESIS - SHORT-TERM 3-YEAR OUTCOME RESULTS

Milad Ahmadi, Steven Ross, Colin Holton, Jon Conroy
Department of Orthopaedics, Harrogate Hospital, Harrogate - United Kingdom

Introduction: Bone saving hip arthroplasty is a reasonable option for younger active patients, as they are potential candidates for subsequent revision arthroplasty.
Objectives: This prospective study reviewed patients that underwent total hip replacements using the Silent hip "neck only" prosthesis performed over a 2-year period at a district general hospital in the UK. The follow-up was a minimum of 3 years.
Methods: The Silent hip "neck only" prosthesis was performed in 40 patients. Ceramic-on-ceramic bearing was used in all cases. Results were analysed using pre- and post-operative UCLA, NAHS and SF12 scores.
Results: All patients other than one who required revision secondary to loosening had successful outcomes. One patient was treated with oral antibiotics for a superficial wound infection. No patients reported squeaking due to the ceramic bearing surfaces.
Average follow-up was 3.5 years and mean age of 46.6 years at time of operation.
Comparison of pre- and post-operative results revealed an improvement in the NAHS from a mean of 34.2 to 91.1, with multiple patients scoring 100. There was an increase in average UCLA activity rating and an improvement in SF12 score postoperatively.
Conclusions: The Silent hip "neck only" prosthesis is a safe and effective implant in patients with adequate femoral neck bone stock with good outcome.

FIVE-YEAR RESULTS OF THE METHA SHORT HIP STEM FEMORAL FOR THA IN YOUNG PATIENTS

Fritz Thorey[1], Stefan Budde[2], Matthias Lerch[2], Henning Windhagen[2]
[1]ATOS Hospital for Special Surgery, Heidelberg - Germany; [2]Department of Orthopaedic Surgery, Hannover Medical School, Hannover - Germany

The Metha short stem (Aesculap B|Braun, Germany) represents a short neck preserving stem with very proximal metaphyseal anchoring along the calcar and the lateral proximal femur. Until today more than 50,000 Metha short stems are implanted. Furthermore varus/valgus and ante-/retroversion can be chosen by different tapers. Despite theoretical advantages known from the Mayo short stem, there are no clinical long-term results so far. In this study, our clinical experience and first results were presented using the Metha short stem in younger patients.
One hundred and fifty-one patients (77 female, 74 male) with a mean age of 53.2 ± 11.5 years underwent THA (73 left hips and 78 right hips). Indications for THA were osteoarthritis (71%), avascular femoral head necrosis (13%), dysplasia (8%), secondary osteoarthritis (5%), and fracture after resurfacing (3%). The mean follow-up was 5,1 ± 0.4 years. All patients were followed with radiographs and clinical scores.
We found a significant increase in all clinical outcome scores (Harris Hip Score, HOOS). In 70 patients a 135° and in 81 patients a 130° CCD-angle taper was used. In 148 patients a 0°, in 2 patients a -7.5°, and in 1 patient a + 7.5° antetorsion taper was chosen. In radiological analysis we observed no bone loss in the calcar region and no radiolucent lines above 2 mm at the lateral proximal femur. In two patients the stem had to be revised due to subsidence above 10 mm.
In this study the results of a short femoral neck preserving stem for THA are presented. The clinical results showed a significant increase of HHS and HOOS and therefore good/excellent results. Early complications were rare. However, long-term follow-up is needed to analyse the survival of this relatively new short-stem endoprosthesis.

MORE THAN 10 YEARS EXPERIENCE WITH SHORT STEMS IN THA YOUNGER PATIENTS

Steffen Oehme
Department of Orthopaedics, Eckernförde - Germany

Objectives: More and more younger patients need primary hip replacement. Specially for these patients short-stem prostheses have been developed; short stems with fixation, bone incrow and loading only in the proximal parts of the femur. Using these prostheses in primary operation, later on, the first revision can be done with the so-called standard prosthesis.
Methods: We have experience with more than 1,800 short stem prostheses type MAYO from 2001 to 2011 and with 300 FITMORE stems from 2011 till now. The indication for operation in this group of patients is different to the older patients group; the younger patients need hip replacement because of rheumatic diseases, dysplasia or femoral head necrosis. Mean age of these patients is below 50 years. Implantations have been done by an modified Watson Jones approach. We developed a minimal invasive operation technique to provide any trauma to the gluteal muscles. All the cases we have done are under clinical and radiological follow-up.
Results: Reporting all our cases according to the Harris-Hip-Score, we saw good and excellent results; the good functional results were reached in a short period of time after the operation. We have seen less complications in comparison to the group of patients with our standard hip stems. 95% of the operations have been done without any incision to the gluteal muscles; the mean length of skin incision has been less than 8 cm. The x-ray follow-up shows in none of our cases any osteolysis in the region of the calcar femoris. Conclusions: With short-stem hip prostheses good and excellent results can be reached; especially in cases of younger patients these stems should be used. The primary hip replacement therefore can be done with a minimum of bone lost at the calcar and with a maximum of atraumatic operation technique to the soft tissue around the hip joint.

FEMORAL NECK RESECTION LEVEL AND HIP GEOMETRY RESTORATION IN THREE DIFFERENT TYPES OF TOTAL HIP FEMORAL STEM

Blaz Mavcic, Peter Brumat, Vane Antolic
University Medical Centre Ljubljana, Department of Orthopaedic Surgery, Ljubljana - Slovenia

Introduction: Femoral neck resection level can have a profound influence on leg length discrepancy and hip geometry restoration at hip arthroplasty (THA). It is not clear, how the femoral neck resection level correlates with the proximal femoral shape and leg elongation at hip arthroplasty in different types of femoral stem.
Objectives: Our aim was to analyse the influence of femoral neck resection level on hip geometry restoration in three different types of total hip femoral stem.
Methods: The study included a series of 70 consecutive patients with unilateral primary total hip arthroplasty (21 Implantcast-EcoFit with metaphyseal fit, 29 EndoPlus-Zweymüller with distal fit, 20 Link-SPII with cemented fixation and collar) who were operated by a single experienced surgeon through posterior approach. Age at operation, gender, radiographic measurements of canal-flare index, femoral neck resection level and pre/postoperative leg-length discrepancy were obtained from pelvic radiographs.
Results: There was no correlation between femoral resection level and postoperative leg-length discrepancy in any of the three gorups. In the EcoFit group ($r = -0.52$; $p = 0.02$) and the Zweymüller patients ($r = -0.40$; $p = 0.03$) we found significant bivariate correlation of the femoral neck resection level with lower canal-flare-index, but not in the cemented LinkSPII group. In multiple logistic regression model for leg elongation >1 cm at THA, younger age was the only independent risk factor while the canal-flare-index, femoral neck resection level and implant type had no significant impact.
Conclusions: Patients with stovepipe medular canal have higher femoral resection levels at uncemented THA. The impact of the femoral resection level on leg elongation or posteoperative leg-length discrepancy is not considerable. Younger age is an independent risk factor for larger leg elongations regardless of the proximal femoral shape or the implant type used.

Anterior Approach

A RETROSPECTIVE STUDY OF PATIENTS UNDERGOING TOTAL HIP REPLACEMENT WITH DIRECT ANTERIOR APPROACH (AMIS)

Arcangelo Russo[1], Filippo Mendolia[1], Emilia Lo Giudice[2], Tiziana Di Leo[3], Carmela Madonia[4]
[1]Department of Orthopaedic and Traumatology; [2]Department of Anaesthesiology; [3]Department of Physiatrics, Umberto I Hospital, Enna - Italy; [4]Psychology department, University Kore, Enna - Italy

Introduction: The anterior approach hip surgery is a technique known for decades. In recent years, some surgeons have selected a direct way to perform the hip can lead to a saving tissue and bone can limit blood loss and postoperative pain and speed up recovery times especially in the short term.
Purpose: The purpose of the study is to evaluate the results obtained after remote surgery for hip replacement with direct anterior approach (called AMIS by French scholars who designed it). This study has involved certain professions, which are formed by a team of orthopaedic physicians, anaesthetists and psychologists.
Materials and methods: We performed a retrospective study of a group of patients operated on in 2013. They underwent implantation of a hip prosthesis 60 patients, 25 patients with anterior direct access. The patients had a mean age of 69 years (range 82-50). In the preoperative clinical evaluation was made through the card HOOS (Hip Disability and Osteoarthritis Outcome Score), postoperative pain response was monitored by NRS (Numerical rate scales). Parallel with the preoperative tests for hip replacement surgery, patients were assessed the state of physical and mental health, related to the perception of quality of life (QOL) through the administration of questionnaires SF-36 and Geriatric Depression Scale administered preoperatively, with the aim to determine the criteria for inclusion or exclusion that have governed the homogeneity of the group of patients involved in the study. In the follow-up at six months of surgery, the patients were re-administered the SF-36 questionnaire The anaesthetic techniques used were: general anaesthesia in 16 cases; spinal anaesthesia in 3 cases; spino-peridural anaesthesia in 3 cases and blended anesthesia in 3 cases. The management of postoperative pain was carried out in the case of general anaesthesia and spinal anaesthesia through an elastomeric pump with morphine continuous infusion, while in the case of spino-epidural anaesthesia and blended anaesthesia with epidural catheter with Naropin. All patients underwent the same rehabilitation protocol and subsequently re-evaluated at 6 months and a year by administering the scale HOOS again.
Results: The average score obtained in the clinical evaluation through HOOS preoperatively was 13.6 (range 0-34.4), in the assessment at 6 months the mean score was 87.52 (range 21.9-100), in the evaluation after one year, the average score is maintained at the same level. The postoperative pain control has been shown in the media the following results: to 0h NRS 1, to 12h NRS 1.5, to 24 h NRS 2, in the 2nd day NRS 2, in day 3 NRS 2. The most common side effects were headache in one case and nausea and vomiting in two patients who had morphine by continuous infusion.
Conclusions: This study performed only on patients with anterior approach (AMIS) has shown that with this surgical technique you have a good control of postoperative pain in the first three days post-surgery, a rapid functional recovery beginning in the second day of walking already, a quick resumption of activities of daily living and working with consequent improvement in the overall quality of life. Finally, in the psychological evaluation of patients postoperatively, showed an improvement in overall well-being related to health, in most domains of the SF-36.

MID-TERM OUTCOME OF PRIMARY TOTAL HIP ARTHROPLASTY OF THE TRIDENT/ACCOLADE SYSTEM (STRYKER®) USING THE DIRECT ANTERIOR APPROACH

Kersten Berndt, Atul Sukthankar, Patrick Zingg, Claudio Dora
Uniklinik Balgrist, Zurich - Switzerland

Introduction: In 2004 we introduced the direct anterior approach (DAA) for primary total hip replacement (THR) using Trident/Accolade (T/A) system.
Objectives: Since some implants appear more suitable for minimally invasive techniques we aimed to study the cohort of 142 patients treated with T/A through DAA. Moreover we studied the learning curve of the senior author and the institution.
Methods: Retrospective consecutive series of the first 151 primary THR with T/A between July 2004 and February 2006. Survival after 5 years was calculated by Kaplan Meier curve. Outcome was evaluated after at least 5 years including: subjective hip value (SHV), WOMAC and Harris hip score (HHS) and standard a. p. pelvis x-ray. Complications were investigated by chart review.
Results: One hundred and forty-two patients with 151 THR were enrolled. Fifteen patients (18 THR) died during follow-up (FU). Nine patients (10 THR) were lost for FU. Remaining 118 patients (123 THA) were interviewed, 87 patients (92 THA) had a clinical and radiological FU after an average of 80 months. Cumulative 5-year survival (5-JSR) with respect to implant revision for any reason was 94.7%, for implant revision for aseptic loosening it was 98.3 %. For the first 20 operations 5-JSR was 81.2%. 5-JSR for prosthesis implanted by 4 junior surgeons after the senior author had performed 30 operations was 97.8%. Mean SHV was 85.5%, WOMAC averaged 1.35 points; and mean HHS was 94.2 points at FU. Femoral radiolucent lines were present in 6.6 % and HO in 29%, 88% grade one.
Conclusions: Survival and outcome is comparable to results of other studies evaluating T/A and in accordance with the Australian implant registry data after a learning period. The learning curve of a single surgeon is transferrable to other surgeons. T/A is a safe implant used with DAA after a learning curve of 20-30 operations.

QUANTIFICATION OF SURGICAL TRAUMA: COMPARISON OF POSTEROLATERAL SURGICAL APPROACH AND ANTERIOR MINIMALLY INVASIVE (AMIS) FOR TOTAL HIP ARTHROPLASTY BASED ON MARKERS OF INFLAMMATION (INTERLEUKINS). PRELIMINARY REPORT

Ferdinando del Prete[1], Alessandro Petrini[1], Mariangela Manfredi[2], Francesca Meacci[2]
[1]Department of Surgery, ASL 10, Ospedale San Giovanni di Dio s.c. Ortopedia e Traumatologia, Firenze - Italy; [2]Depatment of Medicine, Laboratory of Immunology, ASL 10, Ospedale San Giovanni di Dio, Firenze - Italy

Introduction: Total hip arthroplasty is one of the most frequently used in elective orthopaedic surgery, with minimally invasive methods being more and more frequently described to perform this operation. Unfortunately, to date, the expected benefit (decreased tissue damage) of these minimally invasive techniques has not been objectively measurable. The physiological response to local tissue damage including the skin, subcutaneous tissue, muscle, and bone induces a local inflammatory and systemic reaction designed to maintain the immune balance of the organism and stimulate the repair process. We prospectively analysed the inflammatory response after total hip arthroplasty was

performed using 2 different approaches: posterolateral and anterior minimally invasive (AMIS).
Objectives: The goal of this study was to measure and compare the systemic inflammatory response of patients who were operated on using 2 different techniques, the anterior minimally invasive and the posterolateral. Cytokine levels were used as markers of inflammatory response with the hypothesis that the anterior minimally invasive approach should produce lower levels of circulating cytokines when compared with the posterolateral approach, based on lower local tissue trauma. The secondary objective was to evaluate the functional recovery of patients at 1 year after surgery.
Methods: Having obtained the permission of the ethics committee and patient consent - any patient who met the required standard for hip replacement, who had not had prior hip surgery, who had made use only of anti-prostaglandin or opiates such as anti-inflammatory painkillers in the last 15 days prior to surgery, was considered for enrollment. Patients who had not suspended the anti-inflammatory therapy with steroid drugs or cyclooxygenase-2 (COX-2) in at least 15 days, had cardiovascular disease requiring pre-operative treatment, had immune diseases such as rheumatoid arthritis, required an arthroplasty to treat a fracture, had had prior hip surgery, a clinical history of infection or current infection at the time of intervention or who required cemented prosthetic components, were excluded. The enrollment to one group or the other was perfomed in a pseudo-randomised way. In order to obtain two homogenous groups of patients, preoperative data such as age, sex, comorbidities, and medications such as antiplatelet-anticoagulant and anti-inflammatory, BMI, ASA was collected. Also collected was perioperative data such as duration of surgery, bleeding, transfusions performed, length of the incision, type of anaesthesia, details of the prosthesis, intraoperative complications, VAS of pain, length of hospitalisation. Tests were performed on the levels of cytokines (IL6, IL10, IL8, TNF alfa) on plasma from venous blood sampling 1 hour before and 1 hour after the intervention, and subsequently 24 hours and 3 days after surgery, for example serum creatine kinase (CK) and C-reactive protein (CRP). By measuring the levels of these markers before and after surgery, we could compare the increment reported between the two different groups of patients.
Rating the function through the WOMAC score: pre-op, 4 weeks, 1 year. Evaluation of the patient's ability to forget about the hip replacement through Joint Forgotten Score: 4 weeks, 1 year. Also, radiographic evaluation of the pelvis: immediate post-op, 4 weeks, 1 year.
Results: Preliminary results of the study are presented. The post-operative levels of IL6 are encouraging for the AMIS group, in combination with a rapid functional recovery.
Conclusions: The results of our work seem to indicate that invasiveness can be measured according to the systemic inflammatory response resulting after local tissue damage. In agreement with other authors, the correct enrollment of patients is mandatory, especially with regard to the use of an anti-inflammatory steroid and COX2 that alter the systemic inflammatory response.

SHORT-TERM RESULTS WITH THE AMIStem IMPLANTED VIA ANTERIOR APPROACH IN PRIMARY TOTAL HIP ARTHROPLASTY: INFLUENCE OF SURGEON EXPERIENCE

Panyiotis Christofilopoulos[1], Amanda Gonzalez[1], Guido Garavaglia[2], Constantinos Roussos[1], Robin Peter[1], Anne Lübbeke[1], Pierre Hoffmeyer[1]
[1]University Hospitals of Geneva, Department of Orthopaedics and Trauma, Geneva - Switzerland; [2]Hospital of Bellinzona, Department of Orthopaedics and Trauma, Bellinzona - Switzerland

Introduction: The AMIStem for total hip arthroplasty (THA) has been used at our institution since April 2009. Studies reporting about the AMIStem are lacking.
Objective: To evaluate short-term complications and risk of revision according to surgeon experience with the anterior approach, and 2-year clinical outcomes.
Methods: We conducted a prospective cohort study including all primary THAs with an AMIStem implanted via an anterior approach between April 2009 and June 2013. We evaluated complications (infection, dislocation, intra- and periprosthetic fractures), all cause revision over the whole study period (end of study December 2013), and clinical outcomes at two years follow-up (FU). Surgeon experience was divided into experienced ≥50 THAs vs in training <50 THAs.
Results: Seven hundred and twenty-eight AMIS stems were included (55% women, mean age 67 yrs., mean BMI 26.4, primary OA 76.9%). With respect to complications, there were 9 intraoperative fractures, 7 dislocations within 6 months postoperative, 5 infections and 5 periprosthetic fractures. Over the study period 13 (1.8%) THAs required revision at a mean FU time of 5.6 months. Causes of revision were: recurrent dislocation (n = 2); mechanical reason (n = 3); infection (n = 4); and periprosthetic fracture (n = 4). The overall short-term complication rate was 2.4% for an experienced surgeon and 5.4% for a surgeon in training (risk difference (RD) 3%, 95% CI 0-6). The risk of revision was 0.4% vs 4% (RD 3.6%, 95% CI 1.2-5.9) comparing the experienced surgeon to the one in training. Of 210 eligible patients, 148 attended the 2-year FU visit. Clinical evaluation showed a mean Harris Hip Score of 92.2. Most frequent pain locations were groin (9.9%), trochanter (9%) and/or back (10.8%). 37.7% of the patients were very active (UCLA 7-10), and 90.5% were satisfied or very satisfied (VAS 7-10).
Conclusions: THA with the AMIStem implanted via an anterior approach showed good short-term results. Surgeon experience substantially influenced the incidence of complications and revision.

WITHDRAWN

THE ANTERIOR SUPINE INTERMUSCULAR APPROACH FOR TOTAL HIP ARTHROPLASTY: REDUCING THE COMPLICATION RATE BY IMPROVING THE PROCEDURE

Stephan Vehmeijer, Yvon den Hartog, Nina Mathijssen, Sebastian Peters
Department of Orthopaedic Surgery Reinier de Graaf Hospital, Delft - The Netherlands

Introduction: The literature, in general, makes numerous positive claims on the anterior supine intermuscular (ASI) approach because it uses both an intermuscular and internervous planes. However this approach is also technically demanding and it has its own unique set of specific complications. In our hospital the ASI approach for THA was introduced in September 2007.
Objectives: This study describes specific complications noticed during the first cases operated by anterior approach for THA in our hospital, and specific adjustments that were applied on the procedure to prevent these complications.
Methods: We retrospectively analysed the differences between the first 252 patients who were operated by a standardised approach, and 248 patients who were operated after adjustments were implemented on the procedure. Injury of the lateral femoral cutaneous nerve (LFCN), fractures of the greater trochanter and dislocation of THA were specific complications that were noticed during the first procedures.
Results: Prevalence of injury of LFCN decreased from 7.9 %, to 0.8 % ($p<0.001$), fractures of the greater trochanter decreased from 5.6% to 0.8% ($p = 0.003$), and dislocation decreased from 3.6% to 1.6% ($p = 0.169$).
Conclusions: After applying adjustments on the procedure, specific complication rates for the anterior procedure decreased significantly.

ANTERIOR MINIMALLY INVASIVE SURGERY (AMIS) - WHAT WE LEARNED IN THE PAST 7 YEARS

Ivo Bricman, Stanislav Ovnic
Department of Orthopaedics and Traumatolgy, Slovenj Gradec - Slovenia

Introduction: Minimally invasive operative approaches for the hip surgery has gained a lot of attention in the last decade. Anterior approach is one of them.
Objectives: Since May 2007 and until March 2014 in a regional hospital two orthopaedic surgeons conducted 148 primary and 1 revision AMIS surgery. The operative technique had to be learned and the learning curve is slow. Are there any differences in operative technique, early postoperative ambulation, limb lengthening after 7 years of experience with AMIS technique?
Methods: Retrospectively we analysed all 149 patients, 47 male and 102 female. Mean age was 68; 52 years (range 45, 07-82, 96). The following parameters were analysed: operative blood loss; drainage from operative wound; volume of blood reinfusion by OrthoPAS® system; volume of blood transfusion; duration of surgery; duration of hospitalisation; postoperative limb length equality; and intraoperative and postoperative complications.
Results: We had 3 major intraoperative complications in the first 2 years; 1 periprosthetic fracture of femur and 2 protrusions of acetabular cup. Low-grade infection was the reason for two-stage revision surgery. The data showed reduced intraoperative blood loss: 736 ml/ patient in 2007 compared to 307.27 ml/patient in 2014. The need for blood transfusion was significantly reduced: 365.71 ml of blood transfusion in 2007 compared to 31.5 ml of blood transfusion per patient in 2014. Duration of surgery (87.77 minutes in 2007 compared to 55.45 minutes in 2014) and duration of hospitalisation (12.05 days in 2007 compared to 8.9 days in 2014) were diminished. Postoperative limb length discrepancy was 0.47 cm/patient in 2007 compared to 0.22 cm/ patient in 2014.
Conclusions: After learning curve and 7 years of experience with AMIS technique our results shows that the operative blood loss, need for transfusion, duration of operation and hospitalisation and postoperative limb length discrepancy were significantly reduced. The main reason to continue with AMIS technique is the preservation of hip musculature and that for significantly less postoperative pain, earlier rehabilitation and satisfied patients.

THA Revision Various

Withdrawn

REVISION STRATEGY IN THA CERAMIC FRACTURES

Fritz Thorey
ATOS Hospital for Special Surgery, Heidelberg - Germany

Ceramic fracture is usually related to the propagation of subcritical cracks, which are favoured by stress concentration zones caused by imperfections either at the surface or within the material including pores, in homogeneities, scratches and micronotches. Multiple factors are responsible to be cause of ceramic fracture; these factors can be categorised to manufacture factor, surgical factor and patients' factor. The complication rate of ceramic components in total hip arthroplasty (THA) is very rare and reported with 0.02-0.002% for ceramic ball head and 0.027% for inserts. However, in case of a ceramic fracture the patients need a careful treatment to avoid complications.
In this study the authors analyse the literature concerning ceramic fractures in THA. Furthermore, 91 patients who underwent revision THA were in included in a study using a ceramic revision head (BIOLOX option). The mean age of the patients was 64.1 years with an average follow-up of 2.1 years. Indications for revision surgery were cup loosening, noises, early infection, and ceramic fracture/damage. In all patients the stem was left in situ. We analysed the demographic data, Harris Hip Score (HHS), and Pain Score (VAS) to determine patient satisfaction and complication rate.
In the recent literature the use of ceramic-on-ceramic and ceramic-on-polyethylene are recommended in cases of ceramic fracture. A metal ball head should be avoided in any case due to metallosis and an increase of serum metal ion levels. When leaving the stem inside, a revision ceramic ball head (BIOLOX option) should be used. In our own study there were no complications after using a revision ceramic ball had in all patients at the time of follow-up.
In cases of ceramic fracture CoC or CoP should be used. Especially in revision cases with damaged taper or after ceramic fracture the use of this revision ball head should be considered. However, long-term studies are necessary to analyse the outcome of this revision system.

Withdrawn

FUNCTIONAL OUTCOME OF REVISION ARTHROPLASTY FOR FAILED METAL-ON-METAL TOTAL HIP REPLACEMENTS DUE TO ADVERSE REACTION TO METAL DEBRIS; IS THERE A RELATION WITH METAL IONS LEVELS?

Hafiz Javaid Iqbal, Esther Jackson-Taylor, Waheeb Alazzani, Elizabeth Clatworthy, Alun John
University Hospital of Wales, Cardiff - United Kingdom

Aims: We aimed to assess the pain, functional outcome, survivorship and complications following revision Arthroplasty for failed metal-on-metal (MOM) total hip replacements (THR).
Methods: We reviewed the outcome of a single-surgeon series of revision arthroplasties for failed MoM THRs due to adverse reaction to metal debris (ARMD). Oxford Hip Score (OHS) and EQ-5D-3L questionnaire were used to assess the functional outcome. Exclusion criteria included less than 12 months post revision follow-up and revision for failed resurfacings.
Results: From January 2009 to December 2013, the senior author performed 140 revision arthroplasties for failed MoM Hips. After application of excluding criteria, 106 revision arthroplasties in 100 patients (62 women, 38 men, mean age 65 years) were suitable for this study. At a mean follow-up of 20 months (12-48), the mean OHS was 28.7. Pain improved in 61% patients. Others had either the same (22% patients) or worse pain level (17% patients) as compared to pre-revision pain. A majority of patients were in level 2 for all the EQ-5D-3L dimensions. The mean VAS on EQ-5D-3L was 58.7. The overall complication rate was 16%. There were 4 superficial and 3 deep infections. Dislocations occurred in 8(7.5%) patients. There were 6 (5.7%) re-revisions related to either multiple dislocation (3), Infection (2) or periprosthetic fracture (1). Survivorship free from further revision for any cause was 94.3% at 48 months. There was no significant difference in pre-revision levels of serum cobalt ($p = 0.525$) or chromium ($p = 0.436$) between patients whose pain improved or did not improve after the surgery.
Conclusions: Revision surgery for failed MoM hip replacement due to ARMD helps improve pain and quality of life. However the results of revision for this indication are poor when compared to the results of revision hip surgery for other indication. Patients and surgeons need to be aware of the potential for on-going pain following these operations.

WHICH WAY TO PERFORM ACETABULAR REVISION - REINFORCEMENT CAGE OR JUMBO CUP?

Tomaz Silvester, Andrej Prlja, Klemen Ravnihar
Department of Orthopaedics, General Hospital Jesenice, Jesenice - Slovenia

Introduction: Acetabular revision is challenging procedure which demands experienced surgeon. Bony defects are of different degrees, so are different surgical options for revisions. With jumbo cups contact to host bone can be enlarged and sufficient stability can be achieved. Reinforcement cage can be used as a bridging implant even for very large acetabular defects.
Objectives: The clinical and radiological results of the patients who underwent acetabular revision for moderate to severe bone defects were evaluated. Special emphasis was undertaken to evaluate the newer procedure-use of jumbo cups compared to traditionally used reinforcement cage.
Methods: We reviewed 63 patients for whom acetabular revisions were undertaken by using either Burch Schneider (BS) reinforcement cage (17 patients) or cementless jumbo cups (diameter larger than 62 mm in women and 66 in men, 46 patients). The mean follow-up period was 46 months (range 17-84). Acetabular defects were classified according to Paprosky (from Type 2A to 3A, in two cases 3B) and according to AAOS Score (41 patients Type II,20 patients III and two patients IV). Clinical results were assessed using AAOS lower extremity core and pain score.
Results: The mean AAOS lower extremity core and pain score increased postoperatively for 27 and 41 in jumbo cups group and for 29 and 37 in BS reinforcement cage group. So far there were no implant failures. As for complications-in jumbo cups group 4 re-revisions were needed for dislocation (8,7%) and 1 for early loosening (2%). In BS reinforcement cage group there was 1 dislocation (5,8%). Postoperative radiographs showed in all cases stable implant and in jumbo cups group firm implant to host bone attachment.
Conclusions: Our experience with uncemented jumbo cups for acetabular revisions is very good. With proper sizing of the cup optimal contact with host bone can be achieved, thus use of BS reinforcement cage being reserved only for large pelvic bone loss or discontinuity.

TRABECULAR TITANIUM IN HIP REVISION SURGERY

Francesco Benazzo, Marco Cefalì, Marta Medetti, Loris Perticarini
Ortopedia e Traumatologia, Policlinico San Matteo, Pavia - Italy

Introduction: Trabecular titanium (TT) showed good osseointegration and osteoinduction in preclinical studies. The Lima Delta TT revision cups are One and Revision, which is characterised by a caudal hook and fins. Both allow internal modularity and cranial TT augmentation.
Objectives: The aim of this prospective study is to evaluate the short-term clinical and radiographic outcomes of acetabular revision cups in TT.
Methods: Between December 2008 and March 2013 we performed 60 cup revisions, 33 with the Revision cup and 27 with the One cup. In 20 cases (3.3%) stem revision was associated. The mean age of patients was 69.6 years (range 29-90). Causes of revision were: aseptic loosening in 48 cases; periprosthetic acetabular fractures in 5 cases; recurrent dislocation in 5 cases; infection in 2 cases. In 52 cases bone grafts were used to fill cavitary defects (AIR 1-4). Hemispheric TT augments were used in 13 cases with the same aim. Internal modules were used in 39 cases to restore correct offset. The average follow-up was 30 months (range 12-61).
Results: Mean Harris Hip Score (HHS) was 39.9 preoperatively and 82,7 at last follow-up. We had no intraoperative complications. Perioperatively we had 1 case of dislocation with implant removal and 1 case of implant substitution.
We had 2 cases of superficial infection, one of which required revision of the surgical wound. 4 patients suffered dislocation episodes (1 recurrent); none of them required revision. We had 1 case of asymptomatic aseptic loosening, which did not require intervention. In the remaining cases no radiographic evidence of radiolucent lines was noticed at follow-up, neither any evidence of aseptic loosening. The graft was considered to be integrated in all cases.
Conclusions: Trabecular titanium revision cups showed high capacity of osseointegration, providing good results in short term follow-up.

TRABECULAR METAL CUPS - A SAFE OPTION IN CUP REVISION SURGERY

Maziar Mohaddes, Ola Rolfson, Johan Kärrholm
Department of Orthopaedics, Sahlgrenska University Hospital; Swedish Hip Arthroplasty Register, Gothenburg - Sweden

Introduction: Potential benefits such as high friction, excellent ingrowth properties and low modulus of elasticity may explain an increasing use of trabecular metal (TM) cups in revision hip arthroplasty. To our knowledge there is no comparative study confirming the superiority of TM design when used in revision surgery. We compared the survival of a TM cup and 2 other frequently used cup designs in the Swedish Hip Arthroplasty Register (SHAR).
Patients and methods: Between 2006 and 2012 9,478 first time cup revisions were reported to the SHAR. The 3 most frequently used designs consisted of Trilogy (n = 870), Trabecular Metal (n = 805) and Lubinus cups (n = 785). Reoperation included all surgical interventions while re-revision was defined as exchange or removal of the cup. Cox regression analysis was used to identify risk factors for reoperation and re-revision. The mean follow-up was 3.3 years.
Results: There were 215 reoperations and 132 re-revisions. Cox regression analysis did not show any differences in risk of reoperation or rerevision between the Trilogy and the TM cups. However, the Lubinus design had a lower risk for rerevision (RR = 0.34). The risk for revision was higher if the stem had not been revised (RR = 1.78).
Conclusions: The survival of the TM cup was similar to the two most frequently used designs in Sweden, indicating that continuous use of TM cups can be motivated in first time cup revisions. Longer follow-up is needed to evaluate if the trabecular metal cups can address the revision situation in a superior way compared to the less costly porous press-fit and cemented designs.

THE USE OF HIGHLY POROUS UNCEMENTED ACETABULAR SHELLS IN REVISION TOTAL HIP ARTHROPLASTY: MID-TERM FOLLOW-UP CLINICAL AND RADIOGRAPHIC RESULTS

Ana Cruz-Pardos, Ricardo Fernandez-Fernandez, Eduardo Garcia-Rey, Jose Ortega-Chamarro, Eduardo Garcia-Cimbrelo
Department Of Orthopaedic Surgery, Madrid - Spain

Introduction: Large bone defects are frequent in acetabular revision surgery. Long-term survival of the uncemented acetabular component in revision total hip arthroplasty is determined by initial implant stability and bone in growth. Highly porous acetabular shells facilitate bone in growth providing a reliable fixation.
Objectives: We evaluate clinical and radiographic results in acetabular revision surgery of highly porous screwed acetabular shells.

Methods: We reviewed 90 consecutive hip revision acetabular procedures performed with highly porous screwed acetabular shells. Mean follow-up was 34 months (range 12-90). There were 41 men and 49 women with a mean age of 69.8 years (range 26-93). Bone defects were graded according to Paprosky classification. There were 4 type 1, 36 type 2A, 24 type 2B, 10 type 2C, 14 type 3A and 2 type 3B. Clinical evaluation was assessed according to Merlé-D´Aubigne-Postel scale. Postoperative images were evaluated for osteointegration and reconstruction of the hip centre of rotation according to Ranawat. Kaplan-Meier survival analysis with 95% confidence intervals (CI) was used to assess implant survival, with radiological failure as the endpoint.
Results: The Merlé-DÁubigne-Postel improved on average from 8 to 16 points ($p< 0.001$). There were 4 re-revisions; 3 cups were revised because recurrent dislocation and one cup with a Paprosky 3B defect, by aseptic loosening. At 5 years the cumulative probability of not having re-revision for any reason was 95.3% (95% CI, 95.2-95.34%). There were no infections. Radiological aseptic cup loosening was observed in 2 hips with a Paprosky 3B defect; the remaining hips were radiographically stable and osteointegrated. The hip centre of rotation was restored in 75 patients.
Conclusions: Highly porous acetabular shells are a good option in acetabular revision surgery providing bone in growth in most cases. Bone defects larger than Paprosky type 3A could require other acetabular reconstructive technique. A longer follow-up is necessary to confirm these results.

THE GANZ REINFORCEMENT RING FOR AAOS TYPE III AND IV ACETABULAR DEFECTS IN HIP REVISION ARTHROPLASTY

Mohammad Kamal Abdelnasser[1], Frank M. Klenke[2], Lukas Kraler[2], Klaus A. Siebenrock[2]
[1]Department of Orthopaedics and Traumatology, Assuit University Hospital, Assuit - Egypt; [2]Department of Orthopaedic surgery, Bern University Hospital (Inselspital), Bern - Switzerland

Introduction: Large acetabular defects and pelvic discontinuity in particular are complex problems in revision total hip arthroplasty. Acetabular reconstructions are associated with an increased risk of aseptic loosening, infection, disarticulation, and nerve injury. Treatment options include reinforcement rings, plating of the anterior and/or posterior column, bone grafting, triflange acetabular components, porous metal implants, and combinations of the above.
Objective: To evaluate the effectiveness of the Ganz reinforcement ring for the reconstruction of large acetabular defects (AAOS type III) and pelvic discontinuity (AAOS type IV defects).
Methods: Forty-six hips in 45 patients were retrospectively reviewed after a mean follow-up of 54 months (range 12-161). Patient age at the time of surgery was 68 ± 10 years. All hips underwent THA revision surgery with implantation of a Ganz reinforcement ring and bone grafting. In pelvic discontinuities, plating of the anterior and/or posterior column was performed additionally. Follow-up investigations included conventional x-rays (APpelvis, hip crosstable view) and clinical evaluation. HSS and Merle d' Aubigné scores were assessed.
Results: In type III defects, 22 out of 26 defect reconstructions survived; four hips failed due to aseptic loosening. In pelvic discontinuities 9 out of 20 reconstructions failed due to aseptic loosening (n = 5), non-union (n = 2), and deep infection (n = 2) [Kaplan-Meyer Survival type III vs type IV: p = 0.002]. Time to revision ranged from 26 months to 41 months and 8 months to 99 months in AAOS type III and IV defects, respectively. Reoperation for any cause was done in 9 hips out of 26 in type III defects (34.6%) and in 13 hips out of 20 in type IV defects (65%). Average HSS and Merle d' Aubigné scores of the surviving reconstructions at follow-up were similar in both groups [type III: HSS: 76 (45-99) Merle d' Aubigné: 14 (9-18); type IV: HSS: 75 (36-97), Merle d' Aubigné 14 (9-16)]. Of those reconstructions that survived, 21 out of 22 after type III defects and 9 out of 11 cups after pelvic discontinuity did not show radiographic signs of loosening.
Conclusions: THA revision surgery of large acetabular defects involves a significant risk of failure and severe complications, in particular in patients with pelvic discontinuity. On the other hand, the functional results of successful reconstructions are satisfactory in this elderly population. The failure rates found in the present study are similar to that reported in the literature when reinforcement rings are used for type III as well as type IV defects. Yet, porous metal implants may be a favourable alternative especially for the treatment of type IV defects.

ACETABULAR RECONSTRUCTION CAGE IN REVISION TOTAL HIP ARTHROPLASTY

Hossein Ettehad[1], Afshin Taheriazam[2], Farshad Safdari[2]
[1]Department of Orthopedics, Guillan University of Medical Sciences, Rasht - Iran; [2]Department of Orthopedics, Milad Hospital, Tehran - Iran

Introduction: In revision total hip arthroplasty (RTHA), reconstruction of acetabular component challenges the surgeons and requires a metal ring cage to support the acetabular sides in most of the cases.
Objectives: To investigate the outcomes of our experience with Gap II (Graft Augmentation Prosthesis) implant for acetabular component reconstruction
Methods: Between 2010 and 2013, 24 patients (19 males and 5 females) aged 49.5 ± 26.2 years underwent RTHA utilising Gap II prosthesis. Structural allograft (bulk), morselised allograft and TMT augment were used in 2, 8 and 1 hip, respectively. A cemented polyethylene cup implanted with cement in Gap II implant. Patients were examined clinically and radiographically before and after the operation. Gross classification was used to classify the bone defects. Pre- and post operation, modified Harris Hip Score was completed for all patients. The cup stability was assessed using plain x-rays of the hip. Patients were followed for 15.7 ± 9.3 months.
Results: We found no patient with infection, deep venous thrombosis, pulmonary thromboembolic disease and dislocation. Modified HHS increased significantly from 53 ± 13.6 before the surgery to 85±15.5 after the operation ($p<0.001$).
Conclusions: Reconstruction of the acetabulum in RTHA has 2 major steps including reconstructing the bone defects using grafts and supporting the graft and acetabular sides with a metal cage. Gap II has a hook which implanted in obturator foramina and facilitates the anatomic acetabular component positioning. In addition, extension plates supply more stability for implant through multiple screws in iliac bone.

Paediatrics/Primary Conservative Surgery

HIP SONOGRAPHY AS AN EXAMPLE FOR TELE-MEDICINE IN THE WORLD-WIDE-WEB

Christof Pabinger, Reinhard Graf
Medical University of Graz, Graz - Austria

Introduction: The developmental dysplasia of the hip (DDH) is the most frequent paediatric-orthopaedic disorder in developed countries. 2-4% of all newborns are affected in Germany. A higher frequency can be found in the states of Hessen, Oberpfalz, Franken, and Sachsen. Up to 7.5% are affected in Italy and Greece. Applying the right therapy at an early point of time prevents damage to the hip joint and further arthrosis. Surgical procedures can be prevented by a quick and reasonable therapy. Therfore, it is crucial that therapy starts as early as possible after birth. Hence a screening is mandatory in the first week after birth. Up to now many countries stay without screening and there was no possibility to interpret sonograms from abroad except via email. Sonograms are easy to get, small in size and can be sent easily via a web portal to specialists.
Objectives: We were looking for a use case for tele-diagnostics and tele-medicine in the field of orthopaedics. We wanted to know, if orthopaedic surgeons would be willing to look for a second opinion in difficult cases and if anonymous login would prompt users to supply more sonograms than a login with their real name.
Methods: We established a web portal where sonograms can be uploaded. Patient specific information have to be included in a structured manner (age, gender, side, date of observation...). The sonogram is then evaluated if quality allows proper judgement and it is then forwarded to the inventor of hip sonography, Prof. Graf, initially. Measurement lines are evaluated and descriptive information can be added in a text field. The collected information is then referred back to sender. At this point of time, the use of the portal is free of charge.
Results: The web portal is accepted well. Information was filled out completely in most cases. Several difficult cases could be treated in a slightly different manner using expertise from a specialist. Tele-Diagnosis and Tele-Therapy seem to work sufficiently using sonograms.
Conclusions: The methodology applied is of value to lesser developed counties in the 2nd and 3rd world. Furthermore telemedicine can contribute to the needs of surgeons and patients in developed countries as well, where there is a demand for a second opinion due to forensic and scientific issues.

BACK-CARRYING INFANTS TO PREVENT DEVELOPMENTAL HIP DYSPLASIA AND ITS SEQUELAE - IS A NEW PUBLIC HEALTH INITIATIVE NEEDED?

James Cruickshank[1], Simon Matthew Graham[1], Jonathan Manara[1], Linda Chokotho[2], William J. Harrison[1]
[1]Department of Orthopaedic Surgery, The Countess of Chester Hospital, Chester - United Kingdom; [2]BEIT CURE International Hospital, Blantyre, Malawi, Blantyre - Malawi

Introduction: Developmental dysplasia of the hip (DDH) is rarely encountered in the native sub-Saharan African population.
Objective: We present a retrospective review of the incidence of symptomatic DDH in Malawi and a systematic review of the role of back-carrying as a potential influence of prevalence in this population group.
Method: We retrospectively reviewed the diagnosis and management of all infants seen at the Beit CURE International Hospital, Malawi and its mobile clinics, from November 2002 to September 2012. Additionally, methodical review of the literature using the Preferred Reporting Items for Systematic Reviews and Meta-analyses (PRISMA) checklist and algorithm was performed.
Results: 40,683 children aged under 16 years were managed at our institute over a 10-year period, of which 9,842 children underwent surgery. No infant presented with, or underwent surgical intervention, for symptomatic DDH.
Conclusions: The majority of mothers in Malawi back-carry their infants during the first 2-24 months of life, in a position that is similar to that of the Pavlik harness. We believe this to be the prime reason for the low incidence of DDH in the country. Additionally, there is established evidence indicating that swaddling, the opposite position to back-carrying, causes an increase in the incidence of DDH. There is a need for the establishment of a large clinical trial into back-carrying and prevention of DDH in non-African population groups.

TREATMENT OF CHILDREN WITH DYSPLASTIC COXARTHROSIS

Vladimir Baskov, Valentin Neverov
[1]Department of Hip Pathology, The Turner Scientific and Research Institute for Children's Orthopedics, Saint-Petersburg Pushkin - Russian Federation

Introduction: In analysis of long-term treatment outcomes of children with dysplastic coxarthrosis there is a trend in good results of treatment with increasing age of patients. In treatment of children aged 12-17 years old palliative surgery or expectant treatment is often performed. At 18 years old the problem is automatically transferred to adult orthopaedic surgeons.
Objective: To prove the need for the earliest possible preserving surgery of hip joints.
Methods: In treatment of children with dysplastic coxarthrosis, aged 12-17 years old, our method of choice is acetabulum transposition after triple pelvic osteotomy combined with capsulotomy, acetabulum modelling and femoral osteotomy.
Results: We performed more than 400 such operations. Follow-up period is 28 years. In most patients, clinical improvement, radiographic dynamics of joint space formation and restoration of joint components suggest slowing progression of coxarthrosis. Preservation of thigh muscle function and repositioning of acetabulum laterally and anteriorly deserve positive assessment that will facilitate fixation of acetabular component in hip replacement in the future.
Conclusions: We suggest that in treatment of children with dysplastic coxarthrosis it is necessary to perform reconstructive surgery that restores the hip function and delays the timing of replacement while creating favourable technical conditions for its implementation.

RELATIONSHIP BETWEEN CROSSOVER SIGN AND ACETABULAR COVERAGE IN THE DYSPLASTIC HIP

Hiroshi Koyama, Hironobu Hoshino, Hiroki Furuhashi, Yukihiro Matsuyama
Department of Orthopaedic Surgery, Hamamatsu University School of Medicine, Hamamatsu - Japan

Introduction: Crossover sign (COS) may indicate anterior acetabular over-coverage and/or posterior deficiency. However, it is unclear how COS relates to acetabular coverage in developmental dysplasia of the hip (DDH).
Objectives: The relationship between COS and acetabular coverage in DDH was investigated
Methods: We reviewed plain radiographs of 55 dysplastic hips with no osteoarthritic changes. The software "ACX dynamics" was used to calculate acetabular coverage from a radiograph. The regional areas of acetabular coverage (total, anterior 1/2 (A1/2), posterior 1/2 (P1/2), antero-lateral (AL) and postero-lateral (PL)) were measured. We divided these hips into 2 groups (positive and negative COS), and compared the acetabular coverage rate between 2 groups.
Results: The average acetabular coverage rates in positive COS were total 57.4%, A1/2 50.9%, P1/2 64.0%, AL 11.6% and PL 28.3%, respectively. Those in negative COS were total 57.7%, A1/2 47.5%, P1/2 67.8%, AL 11.1% and PL 36.7%, respectively. Average P1/2 and PL in positive COS were significantly smaller than those in negative COS ($p<0.05$).
Conclusions: In patients with DDH, positive COS does not indicate excessive anterior acetabular coverage but indicates posterior deficiency.

LONG-TERM RESULTS OVER 30 YEARS AFTER SALTER'S PELVIC OSTEOTOMY FOR DEVELOPMENTAL DYSPLASIA OF THE HIP. RELATION WITH FEMORO-ACETABULAR IMPINGEMENT FINDINGS AT BONE MATURE AGE

Shigeru Yanagimoto[1], Toyonori Sakamaki[2], Masaki Tezuka[1], Makoto Kameyama[1], Shinntarou Nakayama[1], Yuri Yabuki[1], Takatsugu Komiyama[1], Eijirou Okada[1], Arihiko Kanaji[3], Yoshiaki Toyama[3], Sasaki Toshie[4]
[1]Department of Orthopedic Surgery, Saiseikai Central Hospital, Tokyo - Japan; [2]Department of Orthopedic Surgery, Fureai Tsurumi Hospital, Yokohama - Japan; [3]Department of Orthopedic Surgery, Keio University, Tokyo - Japan; [4]Department Orthopedic Surgery, Tokyo Metropolitan Ohkubo Hospital, Tokyo - Japan

Introduction: We evaluated the long term results (over 30 years) after Salter's pelvic osteotomy for the treatment of developmental dysplasia of the hip (DDH). Relations with osteoarthritis (OA) involvement over 30 years and X-P validations, including acetabular coverage and femoro-acetabular impingement (FAI) findings at bone mature age, were estimated. From the analysis of these relations, most important risk factor to develop early OA after Salter's operation was investigated.
Objectives and methods: The materials were as follows, 14 cases (1 male, 13 female), 18 hips. For these cases, Salter's pelvic osteotomy was done in the purpose of acetabular coverage improvement. The age at operation was on average 4.7 (2-7) years old. Follow-up term was on average 34 (30-40) years. The age at final follow-up time was 38 (34-46) years old. X-P parameters (Severin's classification and indicators of acetabular coverage and FAI) at bone mature age and OA change at final follow-up time were estimated. The correlation between these parameters and early OA appearance was investigated.
Results: According to Severin's classification at bone mature age, Group 1a was 4 hips, Group 2a; 5 hips, Group 2b; 5 hips, Group 3; 4 hips. OA change was found on 4 hips (1 hip from Group 2a, 2 hips from Group 2b, 1 hip from Group 3). OA change on X-P had started at the time of their twenties. All these 4 cases had hip joint pain clinically. The extent of acetabular coverage did not always effect for early OA involvement. Common risk factors existing in all 4 cases were flat shape femoral head and FAI findings (cross-over sigh and femoral bump positive).
Conclusions: After Salter's pelvic osteotomy for DDH, there exists the possibility that early OA change advances at relative younger age. Even from enough acetabular coverage case (Group 2a), early OA change may occur. There is a possibility to concern FAI for early OA advancement after Salter's operation.

TÖNNIS CLASSIFICATION IS A POOR METHOD FOR GRADING EARLY HIP ARTHRITIS

Natalia Ibañez Aparicio[1], Marius Valera Pertegas[2], Marc Tey Pons[3], Xavier Crusi Sererols[2], Rogelio Sancho Navarro[2]
[1]Department of Orthopaedic Surgery, Barcelona - Spain; [2]Department of Orthopaedic Surgery, Hospital de la Santa Creu i Sant Pau, Barcelona - Spain; [3]Department of Orthopaedic Surgery, ICATME Institut Universitari Dexeus, Barcelona - Spain

Background: Tönnis classification is widely accepted for grading hip arthritis and it's routinely used in therapeutic decision-making for hip conservative surgery. Despite this, few studies have specifically tested the usefulness of such classification in current clinical practice.
Purpose: We aimed to determine whether the Tönnis Classification is a reproducible method to grade early stages of hip arthritis and a reliable reference for conservative hip surgery.
Material and methods: In a prospective study we examined 117 hip x-rays from 2 groups of patients under 55 years of age: 1 group of 31 candidates for hip conservative surgery and a control group of 30 patients with no hip disease. Three orthopaedic surgeons with different levels of experience individually evaluated all images twice, and graded arthritis using Tönnis classification. Intra- and interobserver reproducibility was analysed using Kappa index and graded following Landis and Koch classification. The scale was validated using pain as an external variable.
Results: Kappa values for inter- and intraobserver reproducibility were considered as slight or fair (range 0.173-0.397). Confidence interval showed observer experience did not affect reproducibility. Validity analysis showed that scored were significatively higher in symptomatic hips than in asymptomatic hips (Mann-Whitney Test, $p>0.005$).
Conclusions: Our results indicate that Tönnis classification is not a reliable method to assess early stages of hip arthritis. Its routine use in therapeutic decision-making for hip conservative surgery should be reconsidered.

WITHDRAWN

THE MINI-OPEN ANTEROLATERAL APPROACH FOR THE TREATMENT OF FAI

Benjamin Quansah, Fouzia Khatun, Bala Guhan, Araz Massraf
Department of Orthopaedics, Peterborough City Hospital, Peterborough - United Kingdom

Introduction: Femoro-actecabular impingement (FAI) is increasingly recognised. Surgical treatment ranges from surgical hip dislocation and debridement, arthroscopy and mini-open technique - either on its own or in combination. We present our ongoing study of a mini-open antero-lateral approach for FAI.
Objective: To demonstrate the minimally invasive anterolateral approach is sufficient to address FAI pathology in carefully selected patients in the district general hospital setting.
Methods: Ongoing prospective study of 100 patients from January through to December 2010. Clinical outcome assessed in outpatient setting and quantified using Oxford Hip Scores calculated and pre-procedure and 6, 12, 24 and 52 weeks post-procedure. All cases performed by single surgeon using a standardised approach and surgical technique.
Results: A single surgeon's results are presented based on Oxford Hip Scores pre- and post-procedure with average length of follow-up of 1 year. Our data demonstrates good clinical improvement and improvement in Oxford Hip Scores. No patients required post-operative blood transfusions.
Conclusions: This approach offers a viable alternative for addressing pathology of the supero-lateral corner without the need for methods frequently used that require a steeper learning curve and specialist equipment. The majority of patients with FAI do not exhibit pathology in the central compartment and therefore can avoid arthroscopy and open surgical dislocation.

THE SURGICAL HIP DISLOCATION FOR THE TREATMENT OF FEMORAL-ACETABULAR IMPINGEMENT. A CASE STUDY AFTER A MEAN FOLLOW-UP OF 53 MONTHS

Frank Sitterlee, Stephanie Kirschbaum, Georgi Wassilew, Carsten-Frank Perka, Michael Müller
Charité - Universitätsmedizin Berlin, Centrum für Muskuloskeletale Chirurgie, Klinik für Orthopädie, Berlin - Germany

Introduction: The surgical hip dislocation (SHD) is an established surgical technique for the treatment of femoroacetabular impingement (FAI). The benefits are the full visualisation of the hip joint and therefore the modulation of any bony deformities of the femoral neck and the acetabulum even in areas of the joint difficult to access. The potential disadvantages are the increased time for recovering full joint function and the higher risk for femoral head necrosis and pseudarthrosis.
The aim of the study is to evaluate the surgical success, risks and complications of the SHD for the treatment of FAI in a mid-term follow-up.
Methods: There were 36 patients available for follow-up evaluation. All these underwent SHD for the treatment of FAI (Cam n = 3, Pincer n = 1, combined n = 32) between the years 2006 to 2011. The postoperative care involved sufficient analgesia, physical therapy and partial weight bearing with 15 kg for 6 weeks with increased bearing after radiological evaluation.
The analysis included objective parameters (pre- and postoperative function, scores, range of motion, activity and pain levels, the need for re-operation and conversion to total hip arthroplasty) and the individual estimation of the surgical success by the patients (individual satisfaction, improvements in hip function and symptoms). Additionally the pre- and postoperative radiological images were evaluated.
Results: The mean follow-up was 53 months (range 20-87). The mean age was 49 years (range 35-74). Improvements were made in internal rotation from a mean of 5° pre- to 13° postoperatively ($p<0.05$) and abduction from a mean of 28° pre- to 34° postoperatively ($p<0.05$). The mean HHS changed from 71 pts. ± 11 to 84 pts. ± 17. In 56% of the cases (n = 20) a postoperative pain-free episode was present with a mean of 1.5 years (0-5), a relieve of pain was possible in 28% (n = 10). After recovery 64% (n = 23) returned to an active lifestyle, but the spectrum of sport activities changed to more joint preserving activities. The hip function improved distinctively, 74% of the patients we have seen declared their

actual hip function as normal to nearly normal. The individual satisfaction with the surgical success was 47% (n = 17) and the same number of people would undergo surgery again. The mean alpha angle decreased significantly from 70° to 44° (p<0.05). In 36% (n = 13) the conversion to total hip arthroplasty was necessary after a mean of 33 months. About 40% (n = 5) of these patients had an arthrosis grade >1. The complication rate was 13% (2x femoral head necrosis, 2x pseudarthrosis, 1x screw breakage.)
Conclusions: The surgical hip dislocation is a successful surgical technique for the treatment of femoral acetabular impingement in a mid-term follow-up. It enables to relieve the pain as well as to improve the overall hip function. However, a full restoration by the means of a physiological hip function is limited, particularly in patients with preoperative arthrosis >1°. Therefore a thorough medical briefing of the patients regarding the odds of surgical success, relief of symptoms, patient's expectations, risks and possible residual symptoms is essential.

MINIMISING COMPLICATIONS OF PELVIC PERIACETABULAR OSTEOTOMY WITH A NEW MINIMALLY INVASIVE APPROACH - EARLY CLINICAL AND RADIOLOGICAL RESULTS

Sherif Abouel-Enin[1], Caroline Blakey[2], Sanjeev Madan[1]
[1]Department of Orthopaedics, Doncaster Royal Infirmary, Doncaster - United Kingdom; [2]Department of Orthopaedics, Sheffield Children Hospital, Sheffield - United Kingdom

Introduction: We report the radiological outcomes, and short-term clinical results, of 47 periacetabular osteotomies undertaken through both the traditional bikini incision, and a minimally invasive approach.
Methods: Forty-seven periacetabular osteotomies have been undertaken in 45 patients, by the senior author, between 2005 and 2013. There were 10 male and 35 female patients. The mean age at operation was 28.2 years. Since 2010 surgery has been performed through a 7 cm skin incision (31 hips), an incision coined as minimally invasive by Søballe et al when they described their trans-sartorial approach for acetabular surgery. Clinical data was collected prospectively; outcome measures included the young adult hip score and the hip disability and osteoarthritis outcome score. Pre- and postoperative radiographs were analysed for achieved acetabular reorientation.
Results: At the time of follow-up the median young adult hip score had improved significantly from preoperative values. Mean scores were 35.4 preoperatively, and 64.25 postoperatively. Improvement in the anterior and lateral centre-edge angle was 32° and 32.9° respectively through a traditional incision, and 27.1° and 30° via the minimally invasive approach (p>0.05). Four patients complained of lateral cutaneous nerve hypoasthesia, in 2 patients there was delayed union of the pubic osteotomy and in 1 non-union. Two patients have gone on to total hip replacement.
Conclusions: The minimally invasive approach is safe and allows for accurate reorientation of the acetabulum whilst minimizing tissue damage. Our results showed reduced number of complications with this approach. The scar is cosmetically appealing to patients, especially the predominantly female group treated with this condition.

REDUCTION OF NON-UNIONS WITH A MODIFIED TECHNIQUE AND ALLOGENE BONE GRAFTING OF THE BERNESE PERIACETABULAR OSTEOTOMY

Georgi Wassilew, Viktor Janz, Carsten Perka
[1]Orthopaedic Department, Centre for Musculoskeletal Surgery, Charité - Universitätsmedizin, Berlin - Germany

Introduction: Developmental hip dysplaysia is a common cause for premature secondary osteoarthritis of the hip. The goal of the Bernese periacetabular osteotomy (PAO) is improvement of the femoral coverage to forgo hip osteoarthritis. The standard procedure recommends a secure acetabular fixation through screws to ensure an osseous consolidation of the acetabullum. However, the current literature reports the development of a pseudarthrosis in up to 19% of all cases. The aim of the current study was to evaluate if a modified surgical procedure with interposition of allogenic spongiosa and a fixation using a non-rigid Kirschner-wires leads to a reduction in the rate of pseudarthrosis in comparison to the standard procedure with a more rigid screw fixation.
Methods: Seventy-three patients, (85 hips) undergoing a PAO were included in the study. The average patient age was 28.3 ± 8.9 years with an average follow-up of 24.6 months. The following parameters were evaluated: lateral centre-edge angle (LCE); acetabular index (AI); acetabular index of depth to width (D/W); and femoral head extrusion index (FEI). Additionally, the osteoarthritis grade according to Tönnis, as well as the Harris Hip Score (HHS) was evaluated both preoperatively and at follow-up.
Results: This study was able to show a significant radiological improvement of the femoral coverage resulting in a significant improvement of the LCE (p<0.001), the AI (p<0.001), and the FEI (p<0.001). As expected, there was no significant change in the D/W (p = 0.3821). These radiological improvements resulted in a significant functional improvement resulting in an increased HHS (p<0.001). Using our modified technique/procedure not a single case of pseudarthrosis was found/reported at the time of follow-up.
Discussion: In comparison to the current literature, this represents a significant reduction in the reported rate of pseudarthrosis, while retaining an equal amount of radiological correction/improvement. Possible explanations for the improved outcomes are an improved osteoconductivity and the additional stability of the retroacetabular space, through the utilisation of an allogenic spongiosa graft, as well as the less rigid fixation of the supraacetabular osteotomy through Kirschner-wires.

Tribology/Materials

IN VITRO SIMULATION OF HEAD-NECK TAPER CORROSION USING A LONG-TERM HIP SIMULATOR WEAR TEST

Chenxi Li[1], Amit Parikh[2], Vivek Pawar[2]
[1]Smith & Nephew Orthopaedics Ltd., Leamington Spa - United Kingdom; [2]Smith & Nephew, Inc., Memphis - USA

Introduction: Mechanically assisted corrosion has been observed on the tapers of retrieved metal femoral heads. To examine contributing factors, laboratory studies have primarily used cyclic off-axis loading. While this has created corrosion, it has not replicated the severity of the taper corrosion observed on some retrievals, perhaps due to the absence of multi-axis motion and torque. The primary goal of this study was to compare tapers of the CoCrMo heads tested in a long-term hip simulator study to tapers of retrievals. A secondary goal was to evaluate oxidised Zr-2.5Nb (OxZr) heads tested concurrently.
Methods: CoCrMo and OxZr heads (36 mm, n = 4 each), assembled onto 12/14 Ti6Al4V stem trunnions, were tested in diluted calf-serum against 10 Mrad crosslinked UHMWPE on an AMTI hip simulator for 45 million cycles at 1.15 Hz using a protocol based on ISO-Bergmann profiles. The heads stayed on the trunnions for the entire duration of the test (~2 years). Along with visual and SEM examination, depth of material loss at head tapers was measured on a Taylor-Hobson roundness machine using the straightness function.
Results: The severity of fretting and corrosion observed on tapers of simulator tested CoCrMo heads was within the range observed on retrieved heads and greater than typically observed on heads tested using off-axis cyclic loading. The average (±std. dev) of maximum depth of material loss from CoCrMo head tapers was 23.5 ± 14.5 µm. In comparison, tapers of OxZr heads showed minimal signs of fretting and corrosion with no measurable material loss, which could be attributed to the ceramic oxide on the taper surface.
Conclusions: This study shows the importance of test duration and use of multi-axis motion and torque to simulate mechanically assisted corrosion of head-neck junctions. The corrosion features and depth of material loss on CoCrMo head tapers were similar to those observed on some of the retrieved heads, whereas such features were absent on the ceramic taper surface of OxZr heads.

SEVERE METAL-ON-METAL BEARING WEAR TRIGGERED BY 3rd BODY METAL PARTICULATES IN HIP SIMULATOR STUDY

Ian C. Clarke[1], Evert Smith[2], Thomas K. Donaldson[3], John G. Bowsher[4], Christine Savisaar[4]
[1]Department of Orthopaedics, Loma Linda University, Loma Linda - USA; [2]Department of Orthopaedics, University of Bristol, Bristol - United Kingdom; [3]Empire Orthopaedic Center, Colton - USA; [4]Food and Drug Administration, Silver Spring - USA

Introduction: Metal-on-metal (MoM) bearings have not proven successful. One reason may be that they are susceptible to 3rd-body wear.
Objective: Our objective was to prove that metal debris was the trigger-mechanism. We challenged 38 mm MoM with CoCr, titanium alloy (Ti64), and bone cement (PMM) debris.
Methods: The 38 mm MoM were run in a hip simulator for 5 million cycles. Beginning each test week, 5 mg debris dose was placed in each cup to simulate a clinical impingement risk (CoCr = #230, Ti64 = 340, PMMA = 1300).

Results: Within 1-2 hours of start, metal debris turned the lubricant quite black and this maintained through all tests (PMM debris = no affect). The PMM, CoCr, and Ti64 debris gave MoM wear-rates 0.3, 4.1, and 6.4 mm3 per million cycles, respectively, statistically significant differences.
Discussion: This is 1st investigation of PMM, CoCr and Ti64 debris effects on MoM. Our study revealed (i) PMM debris did not affect CoCr and (ii) CoCr and Ti64 metal debris provoked adverse MoM wear with black colouration similar to that seen in retrievals. Ti64 debris created greatest response, raising MoM wear x20-fold above PMM-controls. Such MoM sensitivity to metal debris may explain the dichotomy of good and bad reports.

METAL ION LEVELS IN PATIENTS WITH MODULAR ACETABULAR HIP COMPONENTS, MATCHING CrCo LINERS WITH TITANIUM CUPS

Jean-Alain Epinette
Orthopaedic Research and Imaging Centre in Arthroplasty, Bruay Labuissière - France

Introduction: Instability following hip arthroplasty can be considered as a major issue. Dual Mobility Cups can efficiently prevent dislocations while titanium shells have been successfully used in case of uncemented acetabular reconstructions.
Objectives: Since a polyethylene (PE) mobile liner cannot be directly inserted into a titanium component, new acetabular systems bringing together a CrCo liner and a Ti shell are currently available. However potential metal ion release and immuno-allergic reactions have been reported in hip modular components. Metal ion blood levels in evaluating patients with these modular components can be critical when evaluating these new modular acetabular systems.
Methods: This prospective study analysed a consecutive cohort of 39 CrCo MDM® coupled with either a Trident® (n = 10) or a Tritanium® (n = 29) cup at 2 years follow-up, used in conjunction with a monoblock stem. Bearing surfaces were, in all cases, annealed highly crosslinked PE (X3®) matched either with a CrCo head (n = 24; with 15 22.2 mm and 9 28 mm) or Alumina (Biolox Delta® n = 15, all 28 mm). Aetiology was revision in 31 cases and difficult primaries in eight. Average age was 70.77yrs (30-92) in 51% females vs 49% males. All patients were followed clinically and had two consecutive Co/Cr ion level controls at 3-12 months initially and 6-19 months afterwards.
Results: Average ion blood levels for all tests were respectively 0.911µg/l, 0.963µg/l and 0.996 for Co, Cr and CO/Cr ratio. No statistical difference was found between these 3 mean levels according to both gender and age. Repeat tests demonstrate decreases in level for respectively Co, Cr and Co/Cr ratio for 79%, 64% and 71% with mean values at -0.232, -0.092 and -0.093.
Conclusions: These preliminary results at 2 years confirm that modularity in these cups would not be an issue in terms of metal ion release, thanks to an eccentric distribution of loads and optimal locking mechanism between liner and shell.

FRETTING AND CORROSION RISK OF CERAMIC BALL HEADS WITH METAL SLEEVES

Markus Flohr, Thomas Pandorf, Roman Preuss
CeramTec GmbH, Plochingen - Germany

Introduction: The role and importance of fretting and corrosion in modular hip endoprostheses has gained interest within the last years. Especially bearing couples with large diameters may experience high friction moments leading to an increase of relative micro movements between the surfaces of the taper connections. Recently published studies show that the risk of fretting and corrosion is significantly reduced by using ceramic ball heads compared to metal ball heads. Objectives: Goal of this study is to investigate the risk of fretting and corrosion as well as possible loosening of large ceramic ball heads with metal sleeves.
Methods: BIOLOX®OPTION systems have been investigated, consisting of ceramic ball heads (BIOLOX®delta) with sleeves (Ti6Al4V) using generic tapers made of different metals (Ti6Al4V, FeCrNiMo, CoCrMo):
A) fretting test according to ASTM F1875-98 (IIb)
B) corrosion test under *in vivo* like fatigue loading
C) simulator test creating large frictional moments

Results:
A) In the ASTM test, for all taper materials under investigation, decreasing corrosion currents on a comparatively low level have been measured.
B) The interface strength between both the taper/sleeve surface and the sleeve/ball head surface has not significantly changed after fatigue loading and storage in a corrosive medium.
C) Even though large bending moments and torques have been applied during the simulator test, no loosening between the components has been observed. The analysis of the involved surfaces exhibited plastic deformation of the microstructure and tribochemical reaction layers as expected. No signs of excessive corrosion have been found.

Conclusions: The results of the fretting and corrosion tests of ceramic ball heads with sleeves exhibited no signs of remarkable corrosion even under adverse conditions (large ball head diameter, high inclination, large bending moments and torques). No loosening events have been observed. The proper assembly of the involved modular components (dry, no debris between the surfaces) according to the manufacturer's Instructions For Use is an essential requirement hereby.

LONG-TERM RESULTS OF CONTEMPORARY HYBRID CERAMIC-ON-CERAMIC TOTAL HIP

Laurent Sedel[1], Marc El Kaïm[2], Simon Nizard[2]
[1]Departement of Orthopaedics, University of Paris - France; [2]Departement of Orthopaedics, University of Paris 7 - France

Introduction: although ceramic-on-ceramic bearing in total hip has been documented for 40 years, few series concerned long-term results with contemporary materials.
Materials and methods: Socket was a press fit titanium alloy shell with ceramic liner. Titanium alloy stems were covered with titanium oxide smooth and cemented. Cone was of 14/16 and ceramic head were of 32 mm in diameter. Two hundred and five consecutive THR in 206 patients were implanted from January 1990 to December 1992: 99 females, 107 males, mean age 58.
Results: All patients were followed annually and checked at the longest follow-up by an independent observer. Clinical evaluation radiological grading and revision for any reason and revision due to material were recorded.
Forty-three died from unrelated reasons, 75 were followed and examined. Fourteen revisions were recorded: 6 aseptic loosening of the acetabular component, 2 component fractures, 2 revised for unknown reasons, 2 for recurrent dislocations, 1 psoas impingement, 1 infection. Survivorship depicted 88, 2 (82, 3-94, 5) at 20 years. No osteolysis on the socket side, 3 limited osteolysis on the femur.
Discussion: Observational, retrospective, lost to follow-up. But It is the first study on results of ceramic-on-ceramic with contemporary design.

DUAL MOBILITY UHMWPE LINER RETENTION WEAR EVALUATION - EXPLANT ANALYSIS

Thomas Neri, Bertrand Boyer, Remi Philippot, Frédéric Farizon
Service de Chirurgie Orthopedique, CHU Saint Etienne, Saint Etienne - France

Intra-prosthetic dislocation (IPD), a specific complication of dual mobility total hip arthroplasty (DM-THA), always needs a surgical treatment.
Our objective was to compare, liner rim wear from IPD versus liner rim wear without IPD to tribologically define the IPD and to determine a predictive model of occurrence.
From 1960 primary DM-THA, we included 71 polyethylene liners over 15 years of implantation divided into 2 groups: with IPD (41) and without IPD (30). Using a surface scanner following the fringe method enabled us to quantitatively measure the wear of the area.
An IPD related liner had a rim total wear averaging around 41.3% (33, 49, CI 95%). Total wear from the rims having presented an IPD was significantly higher than that of explants without IPD. A model for predicting the probability of IPD based on liner rim total wear could be established. When the rim total wear reached 32%, a 100% risk of LIP was predicted. A transition zone, very discriminative, was observed between 15 and 40 % wear.
Whatever the mechanism, IPD occurred after liner rim wear. This predicting model will stand as assistance to a potential THA revision surgery, and will screen patients at risk of IPD.

MINIMUM FIVE-YEAR RESULTS FOR A LARGE DIAMETER METAL-ON-METAL HIP REPLACEMENT FROM A SINGLE SURGEON IN A DISTRICT GENERAL HOSPITAL: PROSPECTIVE REVIEW OF REVISION RATE, METAL IONS, ALVAL AND OUTCOMES FOR 138 PROSTHESIS

Ihsaan Al-Hadad, Mohamed Altayeb Mussa, Simon West
Department of Orthopaedics, Northampton General Hospital, Northampton - United Kingdom

Introduction: We report 5-7 years results of ASR XL hip in a district general hospital in UK, including revision rates, metal ions, ALVAL and pain.

Objectives: To determine failure rate at a minimum of 5 years for single surgeon in single centre.
Methods: Prospective review of 112 patients (138 prosthesis).
Results: Fifty-six females and 55 males (31-70 years). Metal ions ranged from cobalt 7-1753 nmol/ml and chromium 7-1490 nmol/ml. MRI confirmed ALVAL in 58 cases of varying sizes. Thirty cases revised on basis of metal ion levels and ALVAL. Five patients were asymptomatic despite an evolving ALVAL over a period of 6 months and had revision thereafter. Revision involved a standard regime for collection of histological and microbiological specimens. One patient had full revision of stem, head, and cup. Twenty-nine patients had revision of only head and cup. Postoperatively 5 patients had on-going groin and scar pain but no cases of thigh pain. Twenty-nine patients revised have registered for a class action suit.
Conclusions: Our results show a cumulative failure of 30% at a minimum of 5 years for the ASR XL cup and head combination on a Corail stem. Corail stem has survived in 136 out of 138 cases.

Tribology/Ceramic

CERAMIC ON CERAMIC BEARINGS: PARADOX AND TRIBOLOGY

Patrick Chaboche
Department of Orthopaedic Surgery, Quimper - France

Ceramic-on-ceramic bearing is a favoured choice in younger and patients with high activity. Squeaking and fracture are speculated to be related to the material properties. How to understand this phenomenon?
Firstly we analyse the chemical molecule, then the biomechanical and thermo dynamical behaviour.
The molecule alumina is Al2O3 pure or Alumina Delta: Al2O3 82%, ZrO2 17% and 1% strontium aluminate (Ceramtec Plochingen, Germany). It explains the tribology: hardness so the perfect polishing, no chemical and biological reactions, no ion emission, excellent thermal conductivity and lubrication. The adverse effect is the poor ductility and no deformation that explain the special friction and vibration then the squeaking and the risk of fracture: this is the first paradox.
The biomechanical analysis definite a biological system and understand the friction-vibration in the bearing and also in the connexions. The mechanical behaviour of these connexions can jeopardise the bearing. It is the second paradox.
The thermo dynamical analysis studies the fluctuation-diffusion phenomenon and the balance between the kinetic energy and the opposite energy generated by the friction. It is the third paradox and the key to understand this ceramic-on-ceramic bearing.

METAL ION LEVELS IN CERAMIC-ON-CERAMIC THR WITH MODULAR NECKS

Jan Somers[1], Catherine Van Der Straeten[2]
[1]Department of Orthopaedics, Jan Yperman Hospital, Ypres - Belgium; [2]University Hospital Ghent, Ghent - Belgium

Introduction: In THR with modular necks, corrosion of the neck taper junction can lead to the release of toxic metal ions. The objective was to measure cobalt and chrome in serum of active patients with a well-functioning THR with a modular neck.
Methods: Patients were recruited from a cohort of 500 THR that are followed prospectively. In this consecutive series, there have been no revisions or adverse reactions to date. Inclusion criteria were patients with a hybrid THR with conventional diameter ceramic-on-ceramic bearing couple, used in conjunction with a modular titanium neck and a cobalt-chrome polished tapered stem, a UCLA-activity score of >6/10, without any other metallic implant.
Results: There were 18 females and 10 males. Average age at implantation of THR was 64 years. Twenty patients had a long titanium neck, and 8 had a short titanium neck. There were 4 straight, 8 anteverted, 9 varus, and 7 combined necks. One head diameter 28 mm, 14 32 mm and 13 36 mm. Average cup diameter was 52 mm; none had screws inserted. Follow-up was 27 months (range 16-49). Average modified Charnley score was 17 (range 13-18). There were no differences in subgroups with short necks vs long necks in regard to age, follow-up, cup or stem size, Charnley score, UCLA-activity score or neck type distribution. Radiographic evaluation of all hips showed no signs of osteolysis or radiolucent lines and no abnormalities on plain x-ray. Cobalt in serum averaged 1.20 µg/l (range 0.8-2) in the short neck group and 1.26 µg/l (range <0.5-2) in the long neck group. Overall average cobalt in serum was 1.21 µg/l. In none of the samples we could measure a quantifiable amount of chromium (all samples chrome <0.5 µg/l).
Conclusions: The hybrid THR Profemur Xm - Procotyle L with a titanium modular neck on a cobalt-chrome stem design shows no signs of abnormal toxic ion-levels (cobalt or chrome) in a randomly selected group of well-functioning hip patients.

NEWS ON CERAMICS - BEYOND WEAR REDUCTION

Robert M. Streicher
Dr. Streicher GmbH, Feusisberg - Switzerland

Introduction: Osteolysis, dislocation, fretting corrosion and prosthetic joint infection (PJI) are major factors leading to revision of THA.
Objectives: The goal is to evaluate the value of ceramic bearing for use in total hip arthroplasty.
Methods: Clinical wear of ceramic compared to metal vs highly cross-linked polyethylene (XLPE) was evaluated *in vitro* and *in vivo* using appropriate methodology. Wear and corrosion estimation was carried out using qualitative and quantitative methods 50 matched retrievals each with metal or ceramic heads and 54 retrievals with various bearings using the same implant were investigated. The risk of prosthetic joint infection (PJI) dependence on bearing couples was analysing four databases. One study also analysed the influence of age at surgery, BMI, pathology and articular coupling using Cox multivariante analysis.
Results: The wear study *in vivo* demonstrate after 5 years a significant 54% reduction in highly cross-linked polyethylene wear rate by using ceramic heads compared to metal heads. The investigations on explants revealed a significant difference in the amount of corrosion for different bearings. Articulations using ceramic components demonstrated less material removal on the stem taper for fretting and/or corrosion and zero effect on the ceramic head, while metal heads all had at least some signs of wear/corrosion. The rate of revisions for PJI for the >700,000 patients showed that ceramic components resulted in a lower incidence of revisions for up to 50%.
Conclusions: Using ceramic heads reduces polyethylene wear rate, diminishes the corrosion/fretting issue for modular implants and may also lead to lesser PJI in total hip arthroplasty, addressing main issues for the revision of hip implants.

TRIBOLOGICAL ADVANTAGES OF CERAMIC-CERAMIC BEARINGS

Thomas Pandorf[1], Kim Lars Haeussler[1], Robert Streicher[2], Roman Preuss[1], Christian Kaddick[3]
[1]CeramTec GmbH, Plochingen - Germany; [2]Dr. Streicher GmbH, Freienbach - Switzerland; [3]Endolab GmbH, Thansau/Rosenheim - Germany

Introduction: The reported revision rate for total hip arthroplasty (THA) is below 10% at 10 years. Major factors for revision are aseptic loosening or dislocation. CoC bearings in THA have demonstrated very low wear rates, hence, osteolysis is very rarely observed. Zirconia platelet toughened alumina (ZPTA) has improved toughness and bending strength while maintaining all other advantageous properties of alumina. Consequently, its clinical fracture rate is minimal and wear resistance is superior to alumina.
Objectives: Since a trend exists towards the usage of larger bearings the aim of this study was to compare the tribological behavior of different ZPTA/ZPTA THAs with respect to their ball head diameter.
Methods: Wear tests according to ISO14242-1 were performed in a servo-hydraulic hip simulator with ZPTA bearings from 36 to 48 mm up to 5 million cycles (mc). Wear was measured every mc and surfaces were inspected at 5 mc. For each diameter 3 different combinations regarding clearance and roundness were chosen. The tests were carried out in 20 g/l protein serum.
Results: All ZPTA articulations showed a characteristic running in period followed by a steady decrease in wear rate up to 5 mc. The 48 mm bearing showed highest running in wear. For all bearing sizes wear decreased to about 0.05 mm^3/mc or less throughout the testing period. For all couplings minimal differences in the wear rate and almost no influence of the roundness and clearance on the wear rate was found.
Conclusions: The study supports the extremely low wear rates for ZPTA/ZPTA bearings and shows that increasing the diameter up to 48 mm has only a small influence on the wear rate when tested under ISO14242-1 conditions. Thus, larger diameter ZPTA bearings seem a safe solution for active patients due to higher dislocation resistance and reduced wear. Other loading conditions such as subluxation are known to contribute to the clinical wear rate and will be investigated in future tests.

IMMUNOLOGICAL AND ALLERGOLOGICAL COMPATIBILITY OF CERAMIC MATERIALS

Burkhard Summer[1], Gabriele Roider[2], Peter Thomas[1]
[1]Department of Dermatology and Allergology; [2]Institute of Legal Medicine, Ludwig-Maximilians-University, Munich - Germany

Introduction: Metal allergy is frequently found in the general population, e.g. in about 13% to nickel (Ni), 2% to cobalt (Co) and 1% to chromium (Cr). As an alternative ceramic materials are considered to be without risk of allergy.
Objectives: To assess the immune-allergological properties of Al2O3-based ceramics in metal allergic individuals by a) a patch test model and b) lymphocyte transformation assay (LTT). In parallel potential metal ion release from ceramic material should be evaluated.
Methods: 200 patients (125 female; 22-74years) were patch tested to the standard allergen series (including Ni, Cr, Co) and to ceramic (BIOLOX® delta) discs. LTT: Peripheral blood mononuclear cells (PBMC) of 30 individuals (22 female, 21-76 years) including 10 non-allergic and 20 metal (Ni, Co and/or Cr) allergic were separated from venous blood and cultured *in vitro* in the presence of metal salts, BIOLOX® delta discs or control stimuli. *in vitro* reactivity was evaluated by proliferative response (3H-thymidine uptake). Metal release: Ceramic discs and as control chromated rings were kept 7 days in H2O, artificial sweat or culture medium (= "eluents"). Potential metal release was assessed by atomic absorption spectroscopy ("AAS").
Results: Patch test: of the 200 patients 29 (14.5%) reacted to Ni, 15 (7.5%) to Co, 10 (5%) to Cr - but none to ceramic (BIOLOX® delta) discs. LTT: There was no enhanced PBMC-reactivity to ceramic (BIOLOX® delta) discs. AAS-based evaluation of the eluents gave no enhanced Cr release from ceramic (BIOLOX® delta) discs - but showed marked Cr liberation from chromated (control) rings (up to 22.73 µg/ml).
Conclusions: In the here presented experiments, both the *in vivo* (patch test) model and the *in vitro* assays gave no sign of Cr liberation from ceramic (BIOLOX® delta) discs.

RELATION BETWEEN METAL TAPER CONDITIONS AND THE BURST LOAD OF CERAMIC COMPONENTS

Bernard Masson
CeramTec Medical Division, Toulouse - France

Ceramic ball heads are appreciated for their outstanding properties in terms of wear resistance and burst loads which are significantly higher than the maximum *in vivo* loads acting on the human hip. Nevertheless, rare *in vivo* fractures of ceramic ball heads are a cause for concern.
This paper shows that the *in vivo* metal taper condition strongly influences the clinical reliability of ceramic ball heads.
Ceramic ball heads were loaded in a uniaxial test machine until fracture with various metal taper conditions. Parameters under investigation were contaminated tapers greased (fat), wet and with entrapped foreign body as well as damaged tapers. Additionally, theoretical and numerical calculations were used to explain and support the experimental findings.
The experimental results clearly exhibit a strong influence of the metal taper condition on the burst load. The reduction of the coefficient of friction due to contaminated condition of the metal taper lead to significantly higher hoop stress within the ceramic ball head and consequently reduced the burst loads significantly. Damaged tapers result in point loads, which stress the ceramic locally and as result exceed the burst strength under certain conditions. The theoretical and numerical calculations support these findings for greased and wet taper conditions as well as for damaged tapers.
A carefully cleaned metal taper is necessary for sustaining the high burst loads of ceramic ball heads that are measured *in vitro* under the best experimental conditions. Hence, it has to be pointed out that the burst load of ceramic ball heads is not a material intrinsic parameter but is strongly influenced by its environmental conditions. Good taper conditions are essential for the ceramic ball heads to fully use their strength abilities. As the intraoperatively achieved fixation between modular components is also essential for fretting and corrosion issues. It is essential to prepare their interfaces with outmost care.

MID- TO LONG-TERM RESULT OF CERAMIC BEARINGS IN TOTAL HIP ARTHROPLASTY

Vahit Emre Ozden[1], Goksel Dikmen[1], Burak Beksac[2], I. Remzi Tozun[2]
[1]Department of Orthopaedics and Traumatology, Acibadem Maslak Hospital, Istanbul - Turkey; [2]Department of Orthopaedics and Traumatology, Acibadem Medical Faculty, Acibadem Maslak Hospital, Istanbul - Turkey

Introduction: Ceramic-on-ceramic surfaces have been used to decrease osteolysis and subsequent aseptic loosening due to conventional polyethylene surfaces.
Objectives: To evaluated our clinical experience with ceramic-on-ceramic cementless THA and complications after an average follow-up of more than 8 years.
Methods: From January 2001 and December 2008, 540 total hip arthroplasty with ceramic-on-ceramic bearings were performed in 448 patients (92 bilateral that 54 of them operated simultaneously) with a mean age 49.9 years (18-84) by senior surgeon. The average follow-up time was 8.2 years (5-13.2). Preoperative aetiological reasons were developmental dysplasia of the hip (DDH) in 205 hips, degenerative arthritis in 157 hips, avascular necrosis in 51 hips, rheumatoid diseases in 40 hips, post-traumatic arthritis 40 hips. other reasons in 25 hips and revision surgery in 22 hips. Patients were evaluated with Harris Hips Score (HSS) and radiological findings of acetabular and femoral component loosening or osteolysis with ceramic bearing related complications like squeaking, liner and head fractures were recorded.
Results: The main HHS increased from 42.4 points preoperatively to 94.9 points at the time of last follow-up. We had one fractures of ceramic head (0.1%), 11 clicking (2%) and 4 (0.7%) squeaking; 1 of them revised because of terrible squeaking due to acetabular ceramic liner fracture (0.1%), other 3 seldomly audible from the outside followed conservatively. Twelve patients underwent revision; 3 for acetabular loosening after at an average 9.3 years, 2 for femoral loosening due to malalingment followed Z and schanz osteotomy, 3 for periprostetic fracture. Three recurrent dislocations were revised in high-hip dislocation patients because of component malalingment.
Conclusions: Our study has been demonstrated that ceramic-on-ceramic bearings can be used safely in different aetiological problems. Incidences of noisy hips are reducing.

Basic Science

OBJECTIVE FUNCTIONAL ASSESSMENT, LEAN MASS ANALYSIS AND ASSOCIATED GENETIC ADAPTATIONS OF THE OPERATED LEG FOLLOWING TOTAL HIP ARTHROPLASTY

Tosan Okoro[1], Nasser Al-Shanti[2], Andrew Lemmey[3], Peter Maddison[3], John Andrew[4], Claire Stewart[5]
[1]Department of Orthopaedics, University Hospital of Wales, Cardiff - United Kingdom; [2]Institute of Biomedical Research into Human Movement and Health, Manchester Metropolitan University, Manchester - United Kingdom; [3]School of Sport, Health and Exercise Sciences, Bangor University, Bangor - United Kingdom; [4]Department of Orthopaedics, Ysbyty Gwynedd, Bangor - United Kingdom; [5]Research Institute for Sport and Exercise Sciences, Liverpool John Moores University, Liverpool - United Kingdom

Introduction: This study aimed to characterise the possible metabolic pathways for early muscle recovery following THA by combining associated genetic adaptations in the affected leg with objective functional measures and body composition analysis.
Methods: Fourteen patients (males n = 8, aged (mean ± SD) 64.6 ± 9.1 yrs; females n = 6 aged 61 ± 12.2 yrs) were recruited. Objective function: maximal voluntary contraction of the operated leg quadriceps (MVCOLQ), chair sit to stand (ST) score in 30 seconds, the 6 minute walk test (6MWT), and lean mass the operated leg assessed by dual energy x-ray absorptiometry (DEXA) scanning. Genetic adaptations were assessed with vastus lateralis (VL) muscle biopsies. RT-qPCR analysis was performed for genes coding for hypertrophy [FOS, calpain2 (CAPN2)], atrophy (20s proteasome alpha subunit 7 (PSMA7), cathepsin L2 (CTSL2), inflammation (TNF, IL-6) and lipid metabolism (lipoprotein lipase (LPL), and peroxisome proliferated activated receptor gamma (PPARAG), with assessments preoperatively and 6 weeks postoperatively. Paired *t*-tests assessed changes ($p<0.05$ statistically significant).
Results: At 6 weeks post-THA, there were no significant differences, relative to preoperative values, in objective function measures nor leg lean mass (MVCOLQ (mean ± SD, pre-op vs 6 weeks post-op) 186.9 ± 77.8N vs 201.4 ±

60.2N, p = 0.438; ST 10.1 ± 3.8 vs 11.4 ± 5.18, p = 0.122; 6MWT 251.6 ± 124.8m vs 264.5 ± 109.0m, p = 0.497; and lean mass 6329.8 ± 8793.9g vs 6835.1 ± 8857.4g, p = 0.777). Markers for hypertrophy were increased at 6 weeks (FOS +1463%, p = 0.016; with CAPN2 trending towards a significant increase +129.2%, p = 0.087) with atrophy markers reduced (PSMA7 -44.8%, p = 0.016; CTSL2 -42.5%, p = 0.050), and inflammation (TNF -29.6%, p = 0.023), lipid metabolism showing the same trend LPL -42.45%, p = 0.016). Despite declines of 82.7 % and 26.3 % in the expression levels of IL-6 and PPARAG, significance was not attained.
Conclusions: A hypertrophic cellular muscle response is apparent following THA, although this is not reflected in function nor leg lean mass. Rehabilitation regimes that feature an exercise intensity that is sufficient to induce increments in objective function measures and lean mass may be capitalizing on a post-THA intramuscular cellular environment supportive of anabolism.

HIP OSTEOARTHRITIS, HIP ARTHROPLASTY AND PATIENT BALANCE

Miquel Pons[1], Alex Pasarín[2]
[1]Cirurgia Ortopèdica; [2]Rehabilitació Funcional, Hospital Universitari Sant Rafael, Barcelona - Spain

Hip osteoarthritis (HOA) involves an alteration in the balance and therefore an increase of falling risk. The objective is to confirm this deficit of balance and therefore its improving with a hip prosthesis (THA). Prospective study of patients with osteoarthritis operated by THA. Static posturography at bipodal situation with opened (OE) and closed (CE) eyes before THA and one year after surgery. Single-blind evaluation. Values studied: surface swing body mass centre, Romberg ratio and oscillation surface of each limb. Data compared with 200 healthy controls. Statistics: ratio of variance and Student *t* test.
n = 30 patients. Average age: 69 years (range 28-46). 56% males and 44% females. Affected side: 19 unilateral, 11 bilateral. The oscillation surface of mass centre with OE was worse in HOA compared with control group, p = 0.0003. One year after THA, there was an improvement with p = 0.0149. Romberg ratio also had a significant difference compared to control group (p = 1.0933E-19). There was an improvement after THA, p = 0.0004. After 1 year Romberg ratio was nearly normal, p = 0.0414. In unilateral affected hips, there was a greater oscillation surface of each limb compared with the control group (healthy limb: p = 5.389 E-05 and affected limb: p = 5.365 E-06). With THA, oscillation of healthy limb was normal, p = 0.0057 and affected limb improved, but it was not normal, p = 0.0243.
Our results show an increase of the oscillation surface of mass centre. This suggests a lack of balance in these patients. Furthermore, there is also a greater area of oscillation surface of the healthy limb and arthritic limb compared with the control group. After 1 year with THA, we observed and improvement of the balance with less oscillation of both limbs.

THE HIP JOINT CAPSULE PASSIVELY STABILISES THE HIP DURING NORMAL ACTIVITIES

Jonathan Jeffers[1], Andrew Amis[1], Justin Cobb[2], Richard van Arkel[1]
[1]Department of Mechanical Engineering; [2]Department of Surgery and Cancer, Imperial College London, London - United Kingdom

The capsular ligaments can be cut during hip arthroscopy and although multiple repair options are available, the worth of routine repair is debatable. There is a lack of basic science that describes if the capsule passively stabilises the native hip within a clinically relevant range of motion, ROM, which is needed to evaluate how important capsular preservation/repair is.
This *in vitro* study quantifies the ROM where the capsule passively stabilises the hip and compares this to hip kinematics during daily activities.
Ten cadaveric left hips were skeletonised preserving the joint capsule and mounted in a testing rig that allowed application of loads, torques and rotations in all six-degrees of freedom. At 27 positions encompassing a complete hip ROM, the passive rotation resistance of each hip was recorded. The gradient of the torque-rotation profiles was used to quantify where the capsule is taut/slack. The ROM measurements were compared against hip kinematics from daily activities.
The capsule tightly constrains the hip in full flexion/extension with large slack regions in mid-flexion. Whilst ligament recruitment varies throughout hip ROM, the magnitude of stability provided is constant (0.82 ± 0.31 Nm/degree). The measured passive stability envelope is less than clinical ROM measurements indicating the capsule does provide stability to the joint within a relevant ROM. Activities such as pivoting, stooping, shoe tying and rolling over in bed all would recruit the capsular ligaments in a stabilising role.
The fine-tuned anatomy of the hip capsule provides a consistent contribution to rotational hip stability within a functionally relevant ROM for normal activities. This also acts to prevent or reduce loading of the labrum. Capsulotomy should be kept to a minimum and routinely repaired to maintain natural hip mechanics. All ligaments are slack in mid-flexion with neutral abduction and rotation making this an ideal position for hip joint distraction.

THE CAPSULAR LIGAMENTS PROVIDE MORE ROTATIONAL STABILITY THAN THE LABRUM OR LIGAMENTUM TERES

Richard van Arkel[1], Andrew Amis[1], Justin Cobb[2], Jonathan Jeffers[1]
[1]Department of Mechanical Engineering; [2]Department of Surgery and Cancer, Imperial College London, London - United Kingdom

High-energy trauma, low-energy repetitive motions and excessive surgical bony/soft tissue resection can all cause hip instability in young adults. Instability is also a concern following total hip arthroplasty where subluxation can cause squeaking/metallosis through edge loading, or cause dislocation. Careful soft tissue management can treat/prevent hip instability; however there is no information on the relative importance of each tissue.
This *in vitro* study finds the primary and secondary passive internal and external rotation stabilisers so that the most important soft tissues can be prioritised during surgery.
Nine cadaveric left hips were mounted in a testing rig that allowed application of loads, torques and rotations in all six-degrees of freedom. Each hip was rotated through a complete range of motion and the contribution of the iliofemoral (medial and lateral arms), pubofemoral, ischiofemoral and ligamentum teres ligaments to stability was determined by resecting a ligament and measuring the torque reduction to achieve the same angular position as before resection. Cutting orders were randomised and the contribution from the labrum was also measured.
All the capsular ligaments provided primary stability within the hip's range of motion; however the ischiofemoral/lateral iliofemoral ligaments were primary internal/external rotation stabilisers in two-thirds of possible hip positions with max contributions of 75%/85% respectively. The ischiofemoral ligament also provided a protective sling stabilising the hip against subluxation in deep flexion. The contributions from the ligamentum teres (max 13%) and labrum (max 28%) to rotational stability were less than that of the capsular ligaments.
Preservation/repair of the ischiofemoral and lateral iliofemoral ligaments should be prioritised during hip surgery to maximise post-operative stability. Preservation of the ischiofemoral ligament may also prevent subluxation and reduce posterior edge loading and dislocation.

NATIVE PERIARTICULAR MUSCLE DISTRIBUTION DOES NOT CORRELATE WITH HIP JOINT ORIENTATION

Bernd Preininger, Doruk Akigun, Philipp von Roth, Tobias Winkler, Carsten Perka
Department of Orthopaedics, Centre for Musculoskeletal Surgery and Berlin-Brandenburg Centre for Regenerative Therapies, Charité, University Medicine Berlin, Berlin - Germany

Introduction: In total hip replacement (THR) the positioning and the orientation of the implants is crucial for the function, range of motion and stability of the hip joint.
A relationship between the native hip joint geometry and the volume of the abductor muscles in the frontal plane has been quantitatively described. The influence of the native acetabular and femoral orientation on the hip encompassing muscles, however, has not yet been investigated.
Objective: Investigation of a quantitative correlation between the hip encompassing muscles and the acetabular anteversion (AV), the femoral antetorsion (AT) as well as the combined anteversion/antetorsion (AV/AT) in the horizontal plane.
Methods: Retrospective study design, 49 consecutive patients, no hip joint pathologies. AV, AT, AV/AT and the muscle volumes of the M. gluteus maximus (GXV), M. gluteus medius (GMV), M. glutaeus minimus (GIV) and the M. tensor facia latae (TFL) were measured in 3-dimensional computed tomography reconstructions. Correlations between AV, AT and AV/AT and the single and combined muscle volumes were analysed.
Results: Hip joint orientation [°]: AV: 22 ± 5.9; AT: 7.22 ± 7.4; AV/AT: 29 ± 9. Muscle volumes [ccm]: GXV: 780 ± 227; GMV 322 ± 82; GIV: 85 ± 20; TFL 68 ± 22. No side differences were observed (p>0.05). Analysis did not show a correlation between the hip joint orientation and any of the single or combined muscle volumes.
Conclusions: The distribution of the hip encompassing muscles against the background of the hip joint geometry in the horizontal plane surprisingly has not

yielded any quantitative relationships. Therefore hip joint instability after THR due to muscular insufficiency in one direction most likely has to be attributed to the muscle damage during the surgical approach(-es) rather than to a patient-specific muscle distribution. For that along with muscle sparing techniques an approach-adapted positioning of the implants should highly be considered.

RESURFACING OF FEMORAL HEAD WITH FETAL SKULL, AN EXPERIMENTAL STUDY IN DOG

Dariush Savadkoohi, Morteza Khalaji, Babak Siavashi, Arash Aalirezaei, Mersad Moosavi
Tehran University of Medical Sciences, Sina Hospital, Tehran - Iran

Introduction: Destruction of cartilage of femoral head is a problem which eventually leads to destructive joint disease. Although total hip arthroplasty is a successful operation in hip destructive joint disease, but head preserving procedures like cartilage reconstruction may be more useful.
Materials and methods: Fifteen adult dogs divided to 3 groups. Group 1 only femoral head cartilage destruction after surgical dislocation of hip. Group 2 head destructed and covered with calvarium of foetal dog. Group 3 head destructed and covered with calvarium and hip fixed with pin. In this experimental study, skull (calvarium) of foetal dog as pluripotential substance covers the destructed head of femur in dog. After 60 days, femoral heads were dislocated surgically and evaluated macroscopically and microscopically.
Results: In group 1 head destructed macroscopically and microscopically and no cartilage was found in the specimen. In group 2 and 3, fibrocartilage covers the head of femur. Cartilage content is more in group 2.
Discussion: Pluripotential skull (calvarium) of foetal dog changes to fibrocartilage in the hip joint. Fixing the joint cannot improve transformation to cartilage and actually decreases cartilage formation. It means that motion moves stem cells to produce cartilage.

IMPACT OF FEMORAL TORSION ON FEMORO-ACETABULAR IMPINGEMENT

Amélie Reymond, Patrick Zingg, Phillipe Favre, Kersten Berndt, Claudio Dora
Uniklinik Balgrist, Zurich - Switzerland

Introduction: Morphological aberrations can result in femoro-acetabular impingement (FAI). Pathological femoral torsion (FT) is one of them.
Objectives: This experimental study aims to assess the effect of FT on FAI and the amount of osteochondroplasty needed to compensate for decreased FT.
Methods: A CAD-based 3D computer model of an average person was used. Quality of bone surface was improved with Geomagic software. Refined parts were imported into SolidWorks and a coordinate system with three cuboids was established. Within this coordinates the femur was moved until contact with the pelvis occurred. Then FT was varied between -15° and 40° in 5° steps. With reference to a FT of +12° alterations of range of motion due to altered FT were compensated by simulated head-neck osteochondroplasty. Localisation and extent of the resection was assessed.
Results: Hip flexion was not influenced by augmentation of FT from 0° to 50°. Decrease of FT from 0° to -15° relevantly reduced flexion by 45°. In order to compensate for decreased FT of either 0° or –15°, atypical distal femoral neck resection (depth, width, length) of 2, 6, 19 mm and 5, 13, 32 mm was necessary. Hip internal rotation was not influenced by augmentation of FT from 10° to 50°. Varying FT from +10° to -15° exponentially reduced hip internal rotation by 36°. In order to compensate for decreased FT of either 0° or -15°, atypical distal femoral neck resection (depth, width, length) of 2, 4, 10 mm and 4, 8, 25 mm was necessary. Femoral antetorsion >30° limits hip extension and adduction by posterior FAI and ischiofemoral impingement.
Conclusions: In this model decreased femoral antetorsion up to 0° does not relevantly reduce hip flexion and internal rotation. Femoral retrotorsion (<0°) relevantly impairs hip flexion and internal rotation. Compensation by extensive osteochondroplasty would result in creating a groove in the periphery of the femoral neck.

ELECTRO-CHEMICAL TESTING RESULTS OF CONVENTIONAL HIP STEMS

Ahmad Faizan, Jim Nevelos, Viswanathan Swaminathan, Kevor TenHuisen
Stryker Orthopaedics, Mahwah - USA

Introduction: Electro-chemical testing has been used to understand the corrosion potential of hip replacement systems [1]. This *in vitro* test was designed to evaluate the relative electro-chemical performance of 3 different commercially available hip femoral component tapers to understand the effect of taper material combination: Ti6Al4V/CoCrMo [Accolade II] vs TMZF/CoCrMo [Accolade TMZF]) and design: V40 taper [Accolade II] vs C taper [Secur-Fit] (all Stryker Orthopaedics, Mahwah, NJ) on the electro-chemical performance under physiologically relevant loading conditions.
Methods: Testing involved a short-term loading scheme where cyclic load magnitude was incremented in steps (from 100 N up to 3200 N, 3 min at each load at 3 Hz, R = 0.1) followed by a long-term loading scheme where cyclic loading continued for 1 million cycles (3200 N at 3 Hz, R = 0.1). After 1 million cycles loading, samples were allowed to recover for a period of time and the short-term loading scheme was repeated. All tests were performed in phosphate buffered saline solution at room temperature. Electrochemical measurements were taken periodically throughout the duration of the test.
Results: The results showed that the average current and current amplitude increased and the potential dropped with increasing load magnitude. For different groups, the onset load ranged from 960 to 1204 N, and the mean currents at maximum applied load ranged from 1.3 to 2.2 μA. No statistically significant differences were observed between different taper designs or material combinations tested in this study.
Conclusions: The results from this *in vitro* bench top testing showed that these differences in material combination and taper design did not influence the electro-chemical performance of the tapers. Further study will include exploration of the effects of taper surface finish, taper assembly conditions, complex loading mechanisms, and aggressive solution conditions on the corrosion performance of different tapers.

CORROSION ASSESSMENT OF 12-14 EUROPEAN TAPERS USED WITH 28 MM METAL-ON-METAL BEARINGS

Jean Yves Lazennec[1], Ian C. Clarke[2], Evert J. Smith[3], Adreas Stark[4], John G. Bowsher[5], Christina Savisaar[5], Thomas K. Donaldson[6]
[1]Department of Orthopaedics, La Pitie, Paris - France; [2]Department of Orthopaedics, Loma Linda University, Loma Linda - USA; [3]Department of Orthopaedics, University of Bristol, Bristol - United Kingdom; [4]Department of Orthopaedics, Karolinska University, Stockholm - Sweden; [5]Food and Drug Administration, Silver Spring, MD - USA; [6]Emprire Orthopaedics, Colton, CA - USA

Introduction: Modular junctions used in total hip arthroplasty have become controversial again, due to the role of fretting-assisted corrosion. While the "12-14" European taper has been used for 40 years with CoCr and ceramic femoral heads, we could not find corrosion analysis on this "gold standard". We therefore selected for analysis 10 retrieved stems with 28 mm metal-on-metal heads (MOM). Unique to our study were the ridged taper-profiles in both heads and on trunnions.
Methods: Follow-up was 3-8 years, 4 of 10 stems were CoCr types (Sulzer, Suisse) and 6 were titanium alloy (TI64: FH-Orthopedics, France). The 28 mm CoCr heads were bi-valved in horizontal plane for direct imaging by interferometry and SEM.
Results: Non-contacting regions of head tapers had 70 μm pitch and peak-valley depth 5-7 μm. Threads on trunnions was much coarser than heads, with CoCr 130 μm pitch and Ti64 210 μm. In contact zones the head threads had flattened slightly with average roughness 0.45 μm typical. Areas labeled as "corrosion" were well within "mild" grade for all tapers and there was no "imprinting". Thus even with design and material varieties plus "mixed metals" and vendor mix-and-match, these profiled taper junctions had performed well for 28 mm MOM up to 8 years follow-up.

CORRELATION OF METAL IONS IN SYNOVIAL FLUID, SERUM AND URINE OF PATIENTS WITH FAILED METAL-ON-METAL TOTAL HIP REPLACEMENTS

Alun John, Hafiz Javaid Iqbal, Narendra Rath, Elizabeth Clatworthy
University Hospital of Wales, Cardiff - United Kingdom

Introduction: Metal ions release from metal-on-metal (MoM) bearing surfaces can cause local inflammatory reactions leading to joint failure. The systemic effects of these ions are not yet fully understood. There is currently limited literature about distribution of these ions in the body fluids especially correlation of synovial fluid ions with serum and urine ions levels in failed stemmed MoM hip replacements is not well studied.
Objectives: We aimed to analyse the correlations between synovial fluid, serum and urine metal ions in failed MoM hip arthroplasties.
Methods: We analysed the cobalt and chromium ions levels in patients with failed MoM total hip replacements undergoing revision surgery. Synovial fluid

was aspirated at surgery. Blood and urine samples were collected immediately preoperatively. Complete data was available in 67 patients.
Results: The median cobalt levels were 336.3 µg/L, 8.3 µg/L and 41.9 µg/L in synovial fluid, serum and urine respectively. The respective median chromium levels were 341.4 µg/L, 4.7 µg/L and 9.7 µg/L. There was a significant positive correlation between levels in serum and synovial fluid for Co (Spearman's coefficient = 0.573, p = 0.0001) and for Cr (Spearman's Coe = 0.558, p = 0.0001). Similar correlations were found for levels in Synovial fluid and Urine for Co (Sp Coe = 0.482, p = 0.0001) and for Cr (Spearman's Coe = 0.608, p = 0.0001). There were strong correlations between serum and urine levels for Co (Spearman's Coe = 0.779, p = 0.0001) and Cr (Spearman's Coe = 0.825, p = 0.0001)
Conclusions: Both serum and urine metal ions levels are positively correlated with synovial fluid levels.

Trauma 1

AN ANALYSIS OF THE MORTALITY AND LENGTH OF STAY OF LOWER LIMB PERIPROSTHETIC FRACTURES FOLLOWING LOWER LIMB ARTHROPLASTY

Mark Harris[1], Christine Quinlan[2], James Harty[2]
[1]School of Medicine, University College Cork, Cork - Ireland; [2]Department of Orthopaedics, Cork University Hospital, Cork - Ireland

Introduction: There has been a sharp increase in periprosthetic fractures worldwide due to an aging population.
Objectives: Our aim was to observe the increasing trend of periprosthetic fractures versus the associated mortality.
Methods: The length of stay analysis was also performed and approximate total cost per patient. A single-centre, retrospective observational study conducted at a Level I Trauma Centre in Cork, Ireland. All operatively managed periprosthetic lower limb fractures treated at the institution between January 2001 and May 2013 inclusive were identified from theatre logs and discharge records. Date of death and length of stay was confirmed with existing records.
Results: A total of 127 periprosthetic femoral fractures were identified at a mean postoperative interval of 78 months (±84). The average length of stay per patient was 19.85 days (±27.5) with a cost per night at our centre of €914 ($1200). Twenty-nine deaths occurred in the cohort. Four died during their hospital admission. There was a 30-day mortality rate of 5.1% and a 12-month mortality rate of just 11.5%. 76% of this patient group had a greater than 5-year survival.
Conclusions: This study shows that the majority of patients who underwent surgery for periprosthetic fracture lived beyond 2 years postoperatively.

THE TROCHANTERIC HOOK PLATE IN PERIPROSTHETIC FEMORAL FRACTURES

Rui Cabral[1], João Cabral[2], Alfredo Figueiredo[2]
[1]Serviço de Ortopedia D; [2]Orthopaedic Department, Coimbra Hospital and University Centre, Coimbra - Portugal

Introduction: The periprosthetic femoral fracture during or after total hip arthroplasty, is a possible complication, sometimes with difficult surgical solution. The characteristics and severity of the femoral fractures and bone defects may vary and require different surgical strategies. The aim of this study was to evaluate the efficacy of some surgical strategies in the different fracture types
Material and methods: Between 1990 and 2012 we carried out 124 revision hip arthroplasties due to periprosthetic femoral fractures in 72 males and 52 female with a mean age of 67.8 years old, 43 cases in cemented components and 81 uncemented femoral prosthesis. We used trochanteric hook plates in the surgical treatment of 34 clinical cases (27%), according the Vancouver classification: type A (6 cases), type B1 (14 cases), type B2 (6 cases), type B3 (8 cases), type C (0 cases). In 18 clinical cases we only fixed the femoral fracture and in 16 cases needs a revision hip arthroplasty with uncemented femoral stems and applied cancellous bone allografts in 12 cases (35%). The mean follow-up was 12.4 years.
Results: In the majority of cases (31-91%) we observed a very good clinical and radiological evolution, with fracture consolidation between 3–18 months, excellent incorporation of the bone allografts to the host bone. Complications included one superficial infection (3%), of which needed a careful surgical cleanliness; one hip dislocation (3%) treated conservative and 1 case (3%) with rupture of the metallic cables.
Discussion/Conclusions: The treatment of periprosthetic femoral fractures varies according the fracture location and stability of the implants. In the type A or B1 with prosthesis stability, the fracture fixation can be sufficient. However, in the type B2 or type B3 femoral fracture needs a revision hip arthroplasty. Another cases (type A or B) it is not possible to fix the fracture with metallic cables and we needed to apply the trochanteric hook plate to obtain a good fracture fixation and a clinical success.

A BIOMECHANICAL EVALUATION OF VANCOUVER TYPE B1 FEMORAL PERIPROSTHETIC FRACTURE FIXATION USING A PURPOSE-DESIGNED PLATING SYSTEM

Mustafa Rashid[1], Matthew Gee[1], Pramod Achan[1], John McCrory[2], Rhys Pullin[2]
[1]The Royal London Hospital, London - United Kingdom; [2]Cardiff University School of Engineering, Cardiff - United Kingdom

Introduction: Femoral periprosthetic fractures around a well-fixed femoral implant are challenging to treat successfully. Different methods of fixation for these fractures have demonstrated mixed success rates. Research using these newer systems is required to inform Orthopaedic surgeons which configuration of fixation provides sufficient stability to prevent fixation failure.
Objective: To evaluate the stiffness, strain, and mechanical behaviour of four different configurations of femoral periprosthetic fracture fixation around a well fixed prosthesis.
Methods: Four different configurations using the NCB system to fix femoral periprosthetic fractures around a stable cemented collarless, polished, tapered femoral stem (CPT, Zimmer) were prepared using composite synthetic femora. Constructs tested had increasing degrees of cement mantle intrusion from none (cables-only) to six bicortical locking screws in the proximal fragment. Constructs were loaded in 3 modes, then cyclically loaded in axial compression, and post-cycling loading to determine the overall stiffness and maximum load to failure.
Results: Pre-cycling mechanical testing produced erratic results however, after cycling, 'bedding in' of the prosthesis into the cement mantle occurred and there was a reliable correlation observed. Bicortical locking screws in the proximal fragment inferred the greatest construct stiffness, particularly in torsion. A trend was observed with progressive decrease in cement mantle intrusion. The cables-only construct was deemed to be the least stiff and unsatisfactory for fixation stability.
Conclusions: Polyaxial bicortical locking screws that breach the cement mantle and bypass the femoral stem leads to greatest construct stiffness. Cables-only fixation does not provide sufficient stability to prevent excessive displacement and should be avoided.

CAN INTERTROCHANTERIC FEMUR FRACTURES BE NAILED PROPERLY IN LATERAL DECUBITUS POSITION WITHOUT TRACTION TABLE: RETROSPECTIVE ANALYSIS OF 207 PATIENTS

Ali Turgut, Burak Günaydin, Burak Önvural, Önder Kalenderer, Levent Karapinar, Mert Kumbaraci, Haluk Agus
Department of Orthopaedics and Traumatology, Tepecik Training and Research Hospital, Izmir - Turkey

Introduction: Treatment of intertrochanteric fractures is still challenging.
Objectives: The purpose of this study is to evaluate if intertrochanteric femur fractures can be reduced and nailed properly in lateral decubitus position without traction table by using proksimal femoral nail antirotation (PFN-A) as a fixing device.
Methods: Two hundred and seven patients were enrolled in this study which included 81 male and 126 female. The mean age at the time of operation was 75 (range 22-95 years). On the immediate postoperative radiographs; Baumgaertner tip-apex distance (TAD) of the helical blade, the quadrant of the helical blade was evaluated.
Results: Mean follow-up time was 20.4 months. According to Ikuta's classification; the number of reduced fractures in Subtype N was 176 (%85), 15 (%7.3) in Subtype P and 16 (%7.7) in Subtype A. We obtained 99% good or acceptable reduction according to Herman criteria. Mean TAD was 29.2 mm. The mean operation time was 57.2 minutes. Optimal blade position had been achieved in 53.5% of the patients and only in 2.4% this localization was superior-posterior quadrants. Cut-out complication occured in nine patients (4.3%).
Conclusions: Patients who have intertrochanteric femur fracture can be treated with PFN-A in lateral decubitus position without using traction table.

CLINICAL EXPERIENCE WITH TELESCOPING HIP NAIL

Suk Kyu Choo, Hyoung-Keun Oh, Dae Yeon Jo, Yoo Kyung Kang
Inje University Ilsan Paik Hospital, Department of Orthopaedic Surgery, Go Yang City - South Korea

Introduction: Sliding (gliding) by the lag screw of sliding hip plate or proximal hip nail, can be advantageous by decreasing the fracture gap which can enhance the fracture repair. But if excessive sliding occurs it may cause shortening of the limb and abductor lever arm and by protruding laterally, it can be a cause of lateral hip pain.
Objectives: A new hip nail with telescoping lag screw was developed to solve the problem of lateral hip pain after fixation of hip fracture and its clinical experience is reported.
Method: From February 2012 to January 2014, 65 years and older femur intertrochanteric fracture patients were treated with Compression Hip Nail (TDM, Korea) which is characterised by telescoping lag screw that slides into outer barrel were alternately used with established other hip nails. The 40 CHN(Gr A) and 46 Synthes PFNA II(Gr B) were alternately used regardless of fracture type. The clinical data were collected and blood loss during surgery, union rate, metal failure or other complications, walking ability and lateral hip pain were evaluated.
Results: Average age and fracture type for both group (A/B) was 79.5/78.7, A1(18/17), A2 (20/21), A3 (2/8). The average blood loss was 114 cc/110.7 cc. Two patients in Gr A and 4 patients in Gr B died during the follow-up. There was 1 cutting out in Gr A who refused further surgery and 2 in Gr B required exchange of the barrel due to cutting through. Otherwise there were no metal failure or nonunions or any other complications concerning the implants. Three patients in group A had there outer sleeve protrude for 1 cm but did not complain of pain and in group B, there were 18 patients who had protruded laterally for more than 1 cm and 6 patients complained of lateral hip pain and required medication and 4 required steroid injection. None opted for exchange of barrel. No patient in Gr A complained of lateral hip pain at the lag screw site.
Conclusions: The telescoping CHN has good clinical results comparable to established hip nail system without lateral hip pain which may be an impairment of function in the elderly patients.

SAFETY AND EFFECTIVENESS OF A NEW OSTEOSYNTHESIS DEVICE DEDICATED TO PREVENT HIP FRACTURE

Frédéric Sibilla[1], Jean-Charles Le Huec[2], Hugues Demezon[2], Julien Rigal[2], Stéphane Costes[1]
[1]Traumatology and Orthopaedic Department, Centre Hospitalier de Libourne, Libourne - France; [2]University Bordeaux Hospital, Traumatology and Orthopaedic Department, Groupe Hospitalier Pellegrin, Bordeaux - France

Introduction: The second fracture of the upper part of the femur is associated to a dramatic increase of the mortality rate (from 20-50% depending of the studies) (1, 2). Therefore, it is clearly important to prevent this second fracture. The purpose of this study is to evaluate the impact of a new prevention dedicated osteosynthesis implant (PDOI) on patient in terms of safety and effectiveness.
Methods: The study was performed in an on-going prospective series of 15 PDOIs. To date, 3 patients were implanted. The PDOI was implanted into the contralateral hip during the same surgery time of fractured hip gamma nail implantation. Mean follow-up was 3 months. Clinical evaluation included the Oxford hip score, the WOMAC scores. Plantar pressure measurements were evaluated at 3 weeks and 3 months after the surgery using a Win-Pod (Medicapteurs).
Results: Mean Age and BMI of patients were 83 ± 3 years and 25 ± 9 kg/m² respectively. Mean duration of surgery was 43 minutes (range 35-58). Cement quantities were similar over the 3 patients (6-7 cc). At 3 weeks, comparison between the 2 legs' plantar pressures revealed no differences (50%-50%). Experiences of pain were comparable between the 2 legs (0.7 and 1 for the Gamma Nail and the PDOI respectively). At 3 months, WOMAC scores for pain and functionality were 6 and 36 respectively and an OHS score of 25. Experiences of pain were similar between the two legs (3 and 4 for the Gamma Nail and the PDOI respectively). Concerning the plantar pressures, results obtained were in favour of the PDOI compared to the Gamma nail (53% vs 47%). No osteolysis or implant loosening was observed at the different follow-ups.
Conclusions: At 3 months, patients have maintained good physical health without any inconveniences, in the contralateral hip, caused by the implantation of the PDOI. Furthermore, patients tend to more bear their weight on the leg with the PDOI. These first results are very encouraging and suggest that PDOI did not cause additional troubles or pains to the patient.

References:
1. Ryg J, Rejnmark L, Overgaard S, Brixen K, Vestergaard P. Hip fracture patients at risk of second hip fracture: a nationwide population-based cohort study of 169,145 cases during 1977-2001. J Bone Miner Res. 2009;24(7):1299-1307.
2. Berry SD, Samelson EJ, Hannan MT, et al. Second hip fracture in older men and women: the Framingham Study. Arch Intern Med. 2007;167(8):1971-1976.

PROXIMAL FEMORAL FRACTURES AUGMENTATION IN ELDERLY PATIENTS WITH OSTEOPOROSIS: LONG-TERM RESULTS

Carlo Dall'Oca, Gian Mario Micheloni
Department of Surgery, Orthopaedic and Traumatology Clinic, University of Verona, Verona - Italy

Introduction: The incidence of proximal femoral fractures has substantially risen in the elderly. This rise has been attributed to an increase in their life span and the underlying poor bone stock and osteoporosis. One of the main reason for revision surgery, reported to be as high as 19%, is the cut-out of the fixation device at the apex of the femoral head, due to bone fragility and/or surgical technique errors. Augmentation, facilitated by injecting cement (polymethylmethacrylate) around the apex of the proximal screw of the fixation device, is considered as an useful method with regard to the increase purchase between the bone and implant interface.
Objectives: The aim of this study is the description of the cement Augmentation operative technique for unstable osteoporotic intertrochanteric fractures with 1-2 femoral head screws devices.
Methods: From 2007 to 2014 we studied 56 patients with trochanteric unstable (31 A2.2, A2.3 and A3) osteoporotic (Sing 1 e 2) fracture treated with endomedullary nail and cement Augmentation. Every patient underwent to hip joint X-rays and clinical tests periodically with a mean follow-up of 5 years.
Results: The average of surgical times increased only 7 minutes.
All patient healing without complications like cut out, femoral head necrosis, nonunion or infections. Clinically results in first days were better than patients treated without Augmentation.
Conclusions: In our experience Augmentation technique provide better clinical results in first postoperative phases without mid term complications (in particular cut-out). We consider that it is a valid method to help surgeons in difficult cases and it could be improved by using partially reabsorbable cements.

SHORTENING AND VARUS COLLAPSE AFTER FEMORAL NECK FRACTURES IN YOUNG PATIENTS

Rafael Carbonell Escobar, Ricardo Fernandez Fernandez
Hospital Universitario La Paz, Madrid - Spain

Introduction: The treatment of femoral neck fractures in younger patients is controversial. Avascular necrosis of the femoral head and nonunion are potencial complications specially in displaced fractures. Nevertheles functional result in these patients is based on the restoration of the anatomy of the proximal femur. We compared the varization and shortening of the femoral neck, in patients treated with cancellous screw fixation or with dynamic plate fixation.
Method: We analysed femoral neck fractures in under 55-year-old patients treated at our institution between 2008 and 2013. Mean age was 43.6 years (range 22-55) and mean follow-up of 29 months (range 9-66). Fractures were classified according to AOTA, Garden and Pauwels classifications. Femoral neck shortening was assessed (<5 mm, 5-10 mm, >10 mm) as well as varization (<5º, 5-10º, >10º) with relation with the unfractured hip. Euroquol-5D (EQ5D) questionnaires were employed for clinical results.
Results: A total of 52 patients were treated with internal fixation; 34 fractures were treated with cancellous screws and 10 with dynamic hip screw fixation. There were 23 undisplaced fractures and 21 displaced fractures. 15 fractures showed comminution of the medial cortex and 14 of the posterior cortex. The rate of avascular necrosis was of 6.8% (3 cases). The was not any nonunion. Mean femoral neck shortening was of 3.6 mm (range 0-18) and mean varus collapse was of 2º (range 0-15º). Patients with severe shortening or avascular necrosis of their hip had significantly lower quality of life scores. We found a higher degree of varus collapse in patients treated with cancellous screws.
Conclusions: A large proportion of displaced and undisplaced femoral neck fractures fixed with cancellous screws heal in a shortened position and varus. This affects the functional result in this group of patients.

TOTAL HIP REPLACEMENT FOR FRACTURED NECK OF FEMUR: THE SIZE OF THE PROBLEM AND THE CHALLENGE OF STILL MEETING BEST PRACTICE TARIFF. A 2-YEAR REVIEW OF A TEACHING HOSPITAL ORTHOPAEDIC DEPARTMENT'S EXPERIENCE

Gary Hannant
Leeds Teaching Hospitals, Leeds - United Kingdom

Introduction: NICE (National Institute for Health and Clinical Excellence) guidelines state a total hip replacement (THR) be offered to those with an intracapsular fracture who were able to walk independently outdoors with no more than 1 stick, are not cognitively impaired and are fit for surgery.
Objectives: Can this be achieved, especially when THRs only at elective hospital?
Methods: All hip fractures from 1/7/11 to 30/6/13 were reviewed. An American Society of Anaesthesiologists (ASA) grade of ≤3 was assigned fit for THR. An Abbreviated Mental Test Score (AMTS) of ≥8 suggests no cognitive impairment. A total of 878 patients had intracapsular fractures, those not meeting NICE criteria were excluded leaving 96.
Results: A total of 35 (36%) patients received a THR and 61 (64%) received a hemiarthroplasty. One (3%) patient received a THR and 38 (63%) a hemiarthroplasty within 36 hours. Delays for administrative/logistics occurred in 25 (71%) of THRs and 18 (30%) of hemiarthroplasties. Nine (26%) THRs were medically unfit whilst 5 (8%) hemiarthroplasties were. Sixteen (26%) hemiarthroplasties needed 1 walking aid outside whilst 4 (11%) THRs did. THRs ASA were 12 (34%) ASA 3, 23 (64%) ASA 2 or 1. For hemiarthroplasty 61 (100%) ASA 2 or 1. THR AMTS were ≥8 in 35 (100%) and for hemiarthroplasties ≥8 in 59 (97%). Mean age was 71.2 (55-85) in THR and 84.2 (66-99) for hemiarthroplasty.
Conclusions: Of 878 intracapsular fractures 96 (11%) met THR criteria, 0.92/week. There were 14 other THRs performed, totalling 1.1/week THR demand. A total of 35 (36%) patients received a THR but only 1 (3%) within 36 hours. Administrative/logistic reasons accounted for 25 (71%) patients. THR for fracture requires a hip surgeon and availability is a big obstacle. Our Trust now has THR equipment at the Trauma hospital to help combat this. The existence of pre-existing hip OA is not recorded and influences mobility and surgical treatment. NICE states when criteria are met they "should be offered a THR". We believe a section in the admission proforma to record the offer is needed.

TOTAL HIP ARTHROPLASTY REDUCES REOPERATION RISK IN FRACTURE PATIENTS. A STUDY FROM THE SWEDISH HIP ARTHROPLASTY REGISTER

Cecilia Rogmark[1], Göran Garellick[2], Johan Kärrholm[2]
[1]Department of Orthopaedics, Skane University Hospital/Swedish Hip Arthroplasty Register, Malmö/Gothenburg - Sweden; [2]Swedish Hip Arthroplasty Register/Sahlgrenska Academy, Univeristy of Gothenburg, Gothenburg - Sweden

Introduction/Objectives: Both hemi- (HA) and total hip arthroplasty (THA) is common as fracture treatment. There is no consensus regarding optimum implant choice.
Methods: The analysis comprises THA, modular bi- or unipolar HA via dorsal or direct lateral approach 2005-2012. Gender, primary/secondary arthroplasty, approach, cemented/uncemented stem was analysed by Cox regression in age groups <75 (n = 8141), 75-85 (19,633) and >85 years (15,485). Including ASA-grade and BMI in the analysis, the number was 3224, 5920 and 4649.
Results: Secondary arthroplasty is a risk factor for reoperation (2.1; CI 1.7-2.6) in all ages, together with uncemented stem (1.8; CI 1.4-2.3) in patients <75 years. THA reduces reoperation risk in patients <85 years, and in patients >85 years after adjusting for ASA-grade and BMI. Bipolar HA implies an increased risk in the oldest group, but not after adjustment for ASA /BMI. Dorsal approach is a risk factor for reoperation due to dislocation; cementless stem for periprosthetic fracture and obesity for reoperation due to infection. Bipolar HA reduces the risk of reoperation due to erosion/pain compared to unipolars, but increases the risk of infection in patients >85 years.
Conclusions: We find THA to decrease the reoperation risk. Secondary arthroplasty, dorsal approach and cementless stem increases the risk.

SURGICAL APPROACH AND PATIENT-REPORTED OUTCOME IN HEMIARTHROPLASTY FOR FEMORAL NECK FRACTURES. A STUDY FROM THE SWEDISH HIP ARTHROPLASTY REGISTER

Olof Leonardsson[1], Ola Rolfson[2], Cecilia Rogmark[3]
[1]Department of Orthopaedics, Blekinge Hospital, Karlskrona - Sweden; [2]Swedish Hip Arthroplasty Register/Sahlgrenska Academy, Gothenburg - Sweden; [3]Department of Orthopaedics, Skane University Hospital/Swedish Hip Arthroplasty Register, Malmö - Sweden

Introduction: In hemiarthroplasty surgery after femoral neck fracture, direct lateral approach reduces the risk of dislocation, but in elective total hip arthroplasty surgery the posterior approach results in better patient-reported outcome than the direct lateral. This is not studied in fracture patients.
Objectives: To evaluate differences between direct lateral and posterior surgical approach regarding patient-reported outcome in hemiarthroplasties.
Methods: Data from SHAR on 3908 patients >70 years with femoral neck fracture and either direct lateral (Gammer/Hardinge) or posterior (Moore) approach during 2009. A questionnaire including EQ-5D and visual analogue scales for pain (VAS-pain) and for satisfaction (VAS-satisfaction), was mailed to the 2,728 patients alive 1 year post-injury.
Results: A total of 2,118 patients (78%; 1140 lateral, 978 posterior) answered. Regarding EQ-5D, VAS-pain or VAS-satisfaction, there was no statistically significant difference between the two groups (direct lateral and posterior approach; analysis of covariance, ANCOVA, adjusted for gender, cognitive impairment, type of stem, type of implant head, ASA-group and age).
Conclusions: The choice of surgical approach does not influence the patient-reported outcomes after hemiarthroplasty surgery. Thus the recommendation to use the direct lateral approach for this patient group (to prevent dislocations) is strengthened.

TOTAL HIP REPLACEMENT FOR FRACTURE NECK OF FEMUR: CEMENTED OR UNCEMENTED?

Veenesh Selvaratnam, Aaron Borbora, Badri Narayan
Royal Liverpool and Broadgreen University Hospitals NHS Trust, Liverpool - United Kingdom

Introduction: About 75,000 hip fractures occur each year in the UK costing the NHS £2 billion per year. The National Institute for Health and Clinical Excellence (NICE) guidelines suggest, in addition to performing total hip replacement (THR) for displaced intracapsular fractures in patients who are able to walk independently, not cognitively impaired and who are medically fit for surgery, to use cemented implants in patients undergoing arthroplasty surgery. Controversy exists regarding the complications of cementing and the perceived advantages of uncemented stems.
Objectives: Comparison of complication rates of cemented vs uncemented THRs for fracture neck of femur in a University Teaching Hospital.
Methods: A retrospective case notes analysis was performed.
Results: Fifty-seven patients (44 females and 13 males) had a THR for fracture neck of femur between January 2011 and November 2012. The age range was 50-87 years (mean 70.4 years). Mean Abbreviated Mental Test Score (AMTS) was 9.6 (range 8-10) and 82% of patients had either an ASA of 1 or 2. A total of 53 patients were independently mobile and 4 were mobile with 1 stick prior to their fall. There were 54 fractures due to simple mechanical falls while 3 were pathological fractures. Fourty-two patients had an uncemented THR while 15 patients had a cemented THR. Both groups were matched for age, sex, ASA and length of hospital stay. There were no documented medical or surgical complications in the cemented THR group. The surgical complications in the uncemented group was 3 periprosthetic fractures, 2 dislocations and 1 wound haematoma (p = 0.32) while the medical complications were 3 chest infections, 2 UTI and 1 TIA (p = 0.32).
Conclusions: In this subgroup of patients, the total rate of complications for uncemented THR was statistically significantly higher that the cemented THR group (p = 0.02). We suggest the use of cemented THR in fracture neck of femur.

Trauma 2

HIP FRACTURE A POLYTRAUMA IN GERIATRIC PATIENT: SERUM LACTATE A PROGNOSTIC MARKER

Sivaraman Balasubramanian, Murali Venkatesan, Chika Uzoigwe, Tim Coats, Steve Godsiff, Asif Khan, Robert Smith
University Hospital of Leicester, Leicester - United Kingdom

Introduction and objective: Outcomes from patients suffering hip fracture remain poor, with a 9% mortality at 30 days and 35% at one year. Despite robust guidelines these mortality rates have undergone little change. Admission serum lactate in patients with sepsis or suffering general trauma has been shown to be an indicator of adverse clinical outcomes. We investigated whether venous lactate can predict mortality for hip fracture patients.
Methods: Over a 12-month period the admission venous lactate of all patients presenting to our institution with hip fractures was prospectively collated. Multivariate binary logistic regression and Cox proportional hazards ratio analysis was used to evaluate the relationship between admission venous lactate and 30-day mortality and early survivorship, while adjusting for age and gender.
Results: A total of 770 patients were included in the study. The mean age was 80 years. The overall 30-day mortality for this cohort was 9.5%. Admission venous lactate was associated with early death. A 1 mmol/L increase in venous lactate resulted in a 1.9 (95% CI 1.5-2.3 p<0.0001) fold increase in the odds of 30-day mortality and a 1.4 (95% CI: 1.2-1.6 p<0.0001) factor increase in the risk of death at any time after hip fracture. Admission venous lactate remained a predictor of mortality despite adjustment for patients American Society of Anesthesiologists (ASA) grade. Those with an admission serum lactate of 3 mm/L or greater were particularly at risk. This cohort had a 30-day mortality odds that was 5 fold higher than those whose level was less than 3 mmol/L (p<0.0001) and an any-time risk of death that was 1.9 times higher (p<0.0001). Those with a level of less than 3 mmol/L had 30-day mortality of 6.8%. For those with an admission venous lactate of 3 mmol or greater this was four times higher at 28%. The difference was statistically significant (p<0.0001).
Conclusions: Elevated admission venous lactate following hip fracture is a predictor of early death.

DEFINING THE EPISODE OF CARE FOR THE HIP FRACTURE PATIENT

James Waddell[1], Erik Hellsten[2], Nick Lo[3], Valerie Palda[4]
[1]Division of Orthopaedic Surgery, University of Toronto, Toronto - Canada; [2]Health Quality Ontario, Toronto - Canada; [3]Department of Anaesthesia; [4]Department of Medicine, St. Michael's Hospital, Toronto - Canada

Introduction: Uniformity of care for hip fracture patients is important to ensure timely surgery and a structured postoperative programme.
Objectives: Develop a programme to improve outcomes for 12,000 hip fracture patients in Ontario, Canada.
Methods: A panel representing payers, hospitals and care providers defined the episode of care for hip fracture patients and developed guidelines for care delivery. This included preoperative assessment, emergency room management, surgical procedures and acceptable postoperative practices regarding ambulation, rehabilitation and discharge home.
Results: Forty-six recommendations have been made and consolidated into a handbook for hip fracture care. These recommendations have been implemented by all hospitals in the province delivering hip fracture care. A scorecard has been developed to monitor the progress and implementation of these recommendations and to monitor the outcome of their adoption.
Conclusions: A multi-specialty based consultative model can define an acceptable episode of care for hip fracture patients that meets the needs of the patient, the care providers, the hospital and those responsible for paying for the care. Insuring appropriate investigations, timely implementation of treatment and appropriate rehabilitation has resulted in a significant improvement in outcome for hip fracture patients.

IMPROVING HIP FRACTURE OUTCOMES WITH INTEGRATED ORTHOGERIATRIC CARE

Mark Middleton[1], Bettina Wan[2], Ruy da Assunção[1]
[1]Department of Orthopaedics; [2]Department of Orthogeriatrics, Worthing Hospital - United Kingdom

Introduction: Our unit serves an elderly population, admitting 400 to 500 hip fractures annually. Using national databases (the UK National Hip Fracture Database, NHFD, and Dr Foster, which collates hospital statistics), a higher than expected mortality rate was identified. The hip fracture pathway was subsequently changed from a consultation based orthogeriatric service to a fully integrated service with multidisciplinary orthopaedic surgical and medical care.
Objectives: The aim of this study was to compare the 2 models of care by quantifying the change in outcomes such as mortality and quality indicators such as time to surgery and length of stay (LOS).
Methods: A total of 1,894 consecutive hip fractures that occurred 2 years before and after the change (880 before, 1018 after) were retrieved from the NHFD and cross-referenced with local data. Outcome variables and quality indicators were compared and multivariate regression analysis was used to assess factors significantly linked to outcomes.
Results: The 30-day mortality was initially 13% but fell to 10% after integrating orthogeriatric care (chi2 test, p = 0.057). Following the intervention, there was a significant reduction in time to surgery (42 to 27 hours, Mann-Whitney *U* test, p<0.001) and LOS (28-21 days, Mann-Whitney U test, p<0.001). There was a significant increase in the number of patients admitted with multiple comorbidities (American Society of Anaesthesiology grade 4 or higher 11% to 18%, chi2 test, p<0.001). Regression analysis suggested multiple variables, such as age and comorbidity, were responsible for mortality, in keeping with previously published data.
Conclusions: Implementing an effective integrated orthogeriatric pathway at our hospital resulted in improved outcomes despite an increase in the complexity of the cases. Examination of local data, together with benchmarking data from national databases may facilitate significant improvement in service delivery.

THE ASSESSMENT OF STANDARDS OF PATIENT CARE FOLLOWING TOTAL HIP REPLACEMENT IN FRACTURED NECK OF FEMUR: A COMPARATIVE STUDY

Ahmed Hamam, Aaron Ng, Jonathan Barclay, Zaid Hashim
Department of Orthopaedics, Pinderfields General Hospital, Wakefield - United Kingdom

Introduction: According to National Joint Registry (NJR) in 2012, 76,448 primary total hip replacements (THR) were performed in England and Wales of which 3% (2,440) were for fractured neck of femur (NOF). The consensus document issued by British Orthopaedic Association (BOA) 'Primary Total Hip Replacement: A guide to good practice' has been published in UK to ensure the best possible care for patients undergoing primary THR in the UK.
Objectives: The aim of the study is to ascertain if the postoperative management of THR in fracture NOF is compliant with the best practice guidelines published by British Orthopedic Association (BOA) in November 2012 and compared to the practice of elective primary THR in our institution.
Method: Between 2009 and 2012, retrospective cohort review of 70 patients undergone THR with mean age of 68.95; range 59-82; M:F = 21:49. In group one (elective) there is 36 patients, in group two there is 34 patients. Patients' demographic details, radiographic details and complications were documented. We compared a few of the postoperative parameters to assess the standards of care between 2 groups.
Results:
For deep venous thrombosis (DVT) prophylaxis: -69.4% (group 1) versus 20.6% (group 2)
For post-operative physiotherapy: -50% (group 1) vs 61.7% (group 2)
For post-operative contact details: -41.6% (group 1) vs 23.5% (group 2)
For outpatient clinical appointment: -86.1% (group 1) vs 35.3% (group 2)
For long term follow-up: -30% (group 1) vs 0% (group 2)
Conclusions: There is a discrepancy of post operative management of THR in fracture NOF as compared to the THR in elective patients, a robust integrated care pathway is in this subgroup of patients, recommended to address the inequalities

OUTCOME OF HIP FRACTURE SURGERY IN PATIENTS WITH POOR PRE-FRACTURE MOBILITY

Dinnish Baskaran, Shah Jehan, Iain Burkinshaw, Frank Howell, Daniel Omonbude, Tajesh Bagga
Trauma and Orthopaedic Department, Diana Princess of Wales Hospital, Grimsby, Grimsby - United Kingdom

Introduction: Hip fractures are common with a UK incidence of 70,000 cases and total healthcare costs of over £2 billion per year. Mortality rates of 10% at 30 days and up to 30% at 1-year have been reported.
Objectives: We wanted to assess the outcome of hip fracture surgery in patients with reduced pre-fracture mobility as has not been exclusively studied previously.

Methods: We retrospectively reviewed 168 hip fracture patients with reduced pre-fracture mobility (wheelchair bound, bed bound, walking with two aids or a frame) who underwent hip fracture surgery at our institution between 2008 and 2013 using case notes, discharge letters, outpatient clinic letters and laboratory test results. Measured outcomes included 30-day renal, cardiac and respiratory morbidity as well as 30-day and 1-year mortality.
Results: Our study comprised 27% males and 73% females with a mean age of 82 years. The 30-day chest infection, acute renal failure and acute coronary syndrome rates were 26%, 7.7% and 4% respectively. In the wheelchair and bed bound group, 30-day and 1-year mortality rates were 11.8% and 52% respectively where as in the two aids and frame group, 30-day and 1-year mortality rates were 4.34% and 39.70% respectively.
Conclusions: Our study highlighted increased 30-day and 1-year morbidity and mortality rates following hip fracture surgery with notable high rates of respiratory and renal complications in patients with reduced pre-fracture mobility. We would recommend pre and postoperative optimisation with orthogeriatric review, chest physiotherapy and intravenous fluid hydration to reduce complication rates and improve morbidity and mortality.

THE EFFECT OF OSTEOPOROTIC TREATMENT ON THE FUNCTIONAL OUTCOME, RE-FRACTURE RATE, QUALITY OF LIFE, HARDWARE COMPLICATIONS AND MORTALITY IN PATIENTS WITH HIP FRACTURES

K.G. Makridis, Theofilos Karachalios, L.S. Badras, K.N. Malizos
Orthopaedic Department of University of Thessalia, Centre of Biomedical Sciences (CERETETH), Larissa - Greece

We included 520, out of 611, who were admitted (2009-2011), operated on due to a hip fracture and completed their follow-up evaluations in this study. Data related to functional outcome scores, re-fracture rate, quality of life, complications and mortality rate were prospectively recorded, analysed and correlated to osteoporotic treatment. There were 151 (25%) men and 369 (71%) women with a mean age of 80.7 years (range 60-98). At a mean follow-up of 27.5 months (range 24-36) a mortality rate of 23.6% at 2 years was recorded. Mean values of functional and quality of life scores were progressively improved within 2 years after surgery. Seventy-eight (15%) patients were taking osteoporotic treatment before hip fracture and 89 (17.1%) started afterwards. Osteoporotic treatment proved to be an important predictor of functional recovery (all p values <0.05), re-fracture rate (p = 0.028), quality of life (EQ-5D, all dimensions p values <0.05), and hardware-related complications (p = 0.031). Osteoporotic treatment did not affect post-fracture mortality rates.

ARE DISLOCATIONS FOLLOWING HIP HEMIARTHROPLASTY A PREDICTOR OF INCREASED MORTALITY?

Anastasios Lampropoulos, Michalis Panteli, Peter Giannoudis
Academic Department of Trauma and Orthopaedics, Leeds General Infirmary, Leeds - United Kingdom

Introduction: Hip fractures represent an international public health problem and an economic burden to the healthcare system, with approximately 1.5 million hip fractures worldwide per year.
Objectives: The aim of our study was to evaluate the incidence, characteristics and mortality risk of patients sustaining a dislocation of a hip hemiarthroplasty.
Methods: This is a case series of patients that presented in our institution with 1 or more episodes of hip hemiarthroplasty dislocation within 2 years from the initial hip operation.
Results: Over a 3-year period, out of 881 hip hemiarthroplasties performed in our institution, 31 patients (10 male) had at least 1 episode of dislocation. The mean age at time of first dislocation was 81.6 years (median 81.5 years, range 65 to 95). The average time between the hemiarthroplasty and the first dislocation was 32.5 weeks (median 3.3 weeks). The average number of dislocations was 2.3 per patient (median 2, range 1-6 dislocations). During the same period, we identified the patients who died during their initial hospitalisation following the hip hemiarthroplasty operation. Out of a total of 81 patients, 7 had sustained a dislocation. Age was found to be significantly lower in the dislocations group (p = 0.02). Although there was a trend that patients in the dislocation group died closer to their initial hip operation, it was not statistically significant (p = 0.06). However, this failure to reach significance might be secondary to a type II statistical error. The risk ratio (RR) of mortality following a dislocation whilst still in hospital was 2.30 [95% Confidence Interval (CI) 1.14 - 4.65].
Conclusions: This study demonstrates that dislocations in the immediate postoperative period following a hip hemiarthroplasty represent a predictor of increased mortality. In particular, the in-patient mortality was found increased more than two-fold.

Outcome Measures

A NEW METHOD TO ASSESS AND QUANTIFY LEARNING CURVE IN HIP ARTHROPLASTY

Tajeshwar Aulakh, Jan-Herman Kuiper, James Richardson
Keele University, Oswestry - United Kingdom

Purpose: Hip resurfacing arthroplasty is a technically demanding procedure than routine total hip arthroplasty. Recent studies have shown higher complication rates for surgeons new to this procedure and this has been attributed to a learning curve. The implant position and post-op complications have been used to assess this learning curve. We describe a new method of using hip scores to assess and quantify this learning curve
Methods: In this international multicentre study, 2,803 patients operated by 27 surgeons were selected from an international hip resurfacing register. Multilevel modelling was used to analyse the effect of serial procedures on year one hip scores. The data was sorted for each surgeon in ascending fashion based on the procedure date resulting in serial scores for each surgeon. These scores were considered as level one and the surgeon was considered as level two. In the first model we looked at the effect of each individual procedure on first year scores. This model is equivalent to a simple regression analysis of score versus procedure number. In the second model, a random intercept model, we took into account the nesting of scores within individual surgeons but assumed that the change in score per procedure for each surgeon would be identical. In the final model, a random slope model, we assumed that scores for each surgeon could vary over time. Individual coefficients were tested for significance using the Wald test, and the three models compared using the likelihood ratio test. MLWin v2.02 software was used for analysis.
Results: In level one model, we found that patients reported an average score of 90.8 at 1 year postoperatively for the first resurfacing procedure, which improved significantly by an average of 0.011 for each extra procedure performed by the surgeons (p<0.05). In the random intercept model, the patients reported a significant variation between surgeons for their first resurfacing procedure in one year post-operative scores. The average increase in score after each consecutive procedure was 0.010 (p<0.05). The scores increased after each additional resurfacing procedure, with an equal increase per extra procedure for each surgeon due to the model assumptions. In random slope model, the change in hip score per additional resurfacing procedure was allowed to vary between individual surgeons. There was similar increase in average score per additional procedure, but there was a significant variation in increase per additional procedure between the surgeons. The surgeons who achieved higher scores in their first procedure had a smaller increase in score per additional procedure than those surgeons who achieved lower scores for their first procedure
Conclusions: The above results demonstrate a learning effect in surgeons undertaking hip resurfacing arthroplasty and post op hip scores can be a helpful tool for assessment of surgical performance. Although this technique has been demonstrated using hip resurfacing arthroplasty, it can be used to assess and compare trainee performance for other surgical procedures using functional outcome scores. This method can be used to compare hospitals and regions and help with policy framework.

RELIABILITY OF THE 9-STEP STAIR CLIMB TEST IN PEOPLE WITH TOTAL HIP ARTHROPLASTY

Bayram Unver[1], Turhan Kahraman[1], Serpil Kalkan[2], Ertugrul Yuksel[1], Vasfi Karatosun[3], Izge Gunal[3]
[1]School of Physical Therapy and Rehabilitation; [3]Department of Orthopaedics, Faculty of Medicine, 9 Eylul University, Izmir - Turkey; [2]Department of Physical Therapy and Rehabilitation, School of Health, Celal Bayar University, Manisa - Turkey

Introduction: Measurement of treatment outcomes is a critical component of clinical practice for people with total hip arthroplasty (THA). 9-step Stair Climbing test (SCT) is one of the most used SCT for people with osteoarthritis. However, reliability of 9-step SCT has not been shown in people with THA.

Objectives: The aim is to investigate the test-retest reliability of 9-step SCT in people with THA.
Methods: 37 patients with THA participated in this study. Patients performed twice trials for 9-step SCT on the same day. Between the first and second trials, patients waited for an hour on sitting positionin order to prevent fatigue. To assess reliability, intra-class correlation coefficient [ICC (2,1)], standard error of measurement (SEM), smallest real difference at the 95% confidence level (SRD95) were calculated.
Results: The average time for the first trial was15.14 ± 7.17 seconds and 15.05 ± 7.02 seconds for the second trial. There was no significant difference between the trials (p>0.05). ICC, SEM and SRD95 for 9-step SCT were 0.98, 0.30 and 0.83, respectively.
Conclusions: Reliability of 9-step SCT was excellent for patients with THA. The 9-step SCT can be used as a quick and simple measure in clinical settings that does not require specialised equipment.

RELIABILITY OF THE PERFORMANCE TESTS IN PEOPLE WITH TOTAL HIP ARTHROPLASTY: 50-FOOT TIMED WALK, AND 30-SECOND CHAIR STAND TEST

Bayram Unver[1], Turhan Kahraman[1], Serpil Kalkan[2], Ertugrul Yuksel[1], Vasfi Karatosun[3], Izge Gunal[3]
[1]Dokuz Eylül University, School of Physical Therapy and Rehabilitation, Izmir - Turkey; [2]Celal Bayar University, School of Health, Department of Physical Therapy and Rehabilitation, Manisa - Turkey; [3]Dokuz Eylul University, Faculty of Medicine, Department of Orthopaedics and Traumatology, Izmir - Turkey

Introduction: Evaluation of outcomes following total hip arthroplasty (THA) is important. Using objective assessment methods is essential to clinicians for determining both the prognosis and the healing of patients after THA. Performance-based measurement methods are commonly used for measuring physical function in patients, planned or implemented THA. 50-Foot Timed Walk (50FTW) and 30-Second Chair Stand Test (30CST) are efficient measurement methods for measuring physical function in patients with lower extremity arthritis. However, reliability of these tests has not been shown in patients with THA yet.
Objectives: The aim is to investigate the reliability of 50FWT and 30CST in patients who have undergone THA.
Methods: A total of 37 patients with THA participated in this study. 30CTS and 50FWT were performed twice trials with 5-minute intervals. Between the first and second trials, patients waited for an hour on sitting position in order to prevent fatigue. The Harris Hip Score (HHS) was used to determine the functional levels of the patients. To assess reliability, intra-class correlation coefficient [ICC (2. 1)], standard error of measurement (SEM), smallest real difference at the 95% confidence level (SRD95) were calculated.
Results: The functional levels of the patients were perfectly according to the HHS (93.27 ± 8.25 for right lower extremity and 93.14 ± 8.08 for left lower extremity). ICC, SEM and SRD95 for 50FWT were 0.98, 0.31 and 0.85, respectively. ICC, SEM and SRD95 for 30CTS were 0.94, 0.28 and 0.77, respectively.
Conclusions: Reliability of 50FWT and 30CST is excellent for patients with THA. These tests are simple, no time consuming and sensitive methods to measure the functional performance and also can be used to quantify even small changes in functional performance in patients with THA in the clinical settings.

TEST-RETEST RELIABILITY AND CONCURRENT VALIDITY OF THE INTERNATIONAL PHYSICAL ACTIVITY QUESTIONNAIRE (IPAQ) WITHIN PATIENTS AFTER TOTAL HIP ARTHROPLASTY

Tim Blikman[1], Martin Stevens[1], Inge Reininga[2], Inge van den Akker-Scheek[1], Sjoerd K. Bulstra[1]
[1]Department of Orthopaedic Surgery, University Medical Centre Groningen, Groningen - The Netherlands; [2]Department of Orthopaedic Surgery, Martini Hospital Groningen, Groningen - The Netherlands

Introduction: Despite recognised benefits of regular physical activity, little is known about the physical activity level of patients after total hip arthroplasty (THA). The International Physical Activity Questionnaire (IPAQ) tries to address this problem.
Objectives: To determine test-retest reliability and concurrent validity of the IPAQ in patients after THA.
Methods: 19 patients completed the IPAQ (short- and long version) twice (in-between period of 9-12 days). Reliability was assessed by calculating Spearman's and Intraclass correlation coefficients (ICC). Concurrent validity was determined by using an accelerometer; Spearman's correlation coefficients were calculated between the IPAQ and the accelerometer. Bland–Altman analyses were performed for the reliability and validity study to notice any systematic bias.
Results: With respect to relative reliability, correlation coefficients for the IPAQ total activity score were good: long form: 0.86 (ICC:0.65), short from: 0.80 (ICC:0.43). Separate activity scores were fair to good and ranged for the long form from r = 0.55 (ICC:0.54) to r = 0.87 (ICC:0.70) and for the short form from r = 0.50 (ICC:0.01) to r = 0.78 (ICC:0.67). With respect to absolute reliability, a slight systematic bias was observed within the total activity score of the long form. With respect to relative concurrent validity, the IPAQ correlated with accelerometer readings; coefficients ranged for the long form from a low 0.18 (sitting) to a high 0.60 (total) and for the short form from a low 0.01 (sitting) to a high 0.68 (vigorous). A significant systematic bias was found between the IPAQ and the accelerometer readings, with IPAQ scores being higher.
Conclusions: The IPAQ possesses a fair-to-good test-retest reliability and weak concurrent validity for determining physical activity behavior of patients following THA. These results are in line with previous studies. Due to the significant systematic bias, the IPAQ may only be suitable for intergroup comparisons.

ARE SURVIVORSHIP AND FUNCTION CORRELATED IN YOUNG HIP ARTHROPLASTY PATIENTS? A PROSPECTIVE STUDY OF SURVIVORSHIP AND HARRIS HIP SCORES AFTER HIP RESURFACING, HYBRID, CEMENTED AND UNCEMENTED TOTAL HIP ARTHROPLASTY IN PATIENTS AGED 55 AND UNDER WITH MINIMUM 5-YEAR FOLLOW-UP

Robert Lawton[1], Sarah Gill[1], Cameron Brown[1], Wiejie Wang[2], Ben Clift[1]
[1]Department of Trauma and Orthopaedic Surgery, University of Dundee, NHS Tayside, Dundee - United Kingdom; [2]University of Dundee, Dundee - United Kingdom

Introduction: Implant choice in young hip arthroplasty is based mainly on survivorship data. There are few long-term studies comparing functional outcomes.
Objective: To investigate whether the best surviving implants also have the best function in young hip arthroplasty patients.
Methods: A total of 758 primary hip arthroplasties in patients aged 55 or under with at least 5 years follow-up (1990-2006) were identified. Prospectively collected pre-op, 1, 3, 5 and 10-year post-op Harris Hip Scores (HHS) and Kaplan-Meier survivorship were compared for cemented, uncemented, hybrid total hip arthroplasties and resurfacing.
Results: There were 244 cemented, 118 hybrid, 127 uncemented and 259 resurfacings included. By 10 years hybrid had the best survivorship (hybrid 0.966, cemented 0.955, resurfacing 0.915, uncemented 0.88). This trend continued at 15 years. Resurfacing, however, had the highest absolute post-operative HHS at all time points and was significantly better up to 5 years (p = 0.000 to 0.004). Hybrid had the lowest postoperative HHS at 1, 5 and 10 years; significantly different from resurfacing but not from cemented and uncemented.
Discussion: These data demonstrate the best surviving implant may not give the best functional outcome and suggest choice of implant in young active patients should take into account survivorship and functional data alongside patient factors.

SOFT-TISSUE BALANCING IN TOTAL HIP ARTHROPLASTY: RESULTS IN 100 CONSECUTIVE PATIENTS

Manoj Sood, Arman Memarzadeh, Dan Arvinte
Department of Orthopaedics, Bedford - United Kingdom

Introduction: Restoration of anatomy is essential in total hip arthroplasty (THA) to optimise function and stability. Leg length and femoral offset are important. Leg-length discrepancy (LLD) of 10 mm or greater is poorly tolerated and can be the subject of litigation. We routinely use a multimodal protocol to optimise soft tissue balancing which involves preoperative templating, leg length measurement supine before positioning, and in the lateral position after positioning, use of an intraoperative leg length and offset measurement device (LLOMD) and use of femoral prostheses with standard and high offset options. Few studies have reported results of femoral offset restoration after THA.
Objectives: To analyse the results of our protocol in restoring leg length and offset in primary THA.
Methods: Radiological leg length and femoral offset were measured in a consecutive series of 100 patients who had THA for unilateral arthritis by an independent observer pre- and postoperatively using validated methods and the contralateral hip as a control. Patients with bilateral hip arthritis and those with secondary hip degeneration were excluded.
Results: 80% of patients had their leg length restored to within 5 mm of the contralateral side [mean 1.5 mm (95% CI -5.7 to +8.7)]. 90% of cases had their

hip offset restored to within 5 mm of the contralateral side [mean 0.6 mm (95% CI -5.6 to +6.8)].
Conclusions: We have reduced the mean leg-length discrepancy and narrowed the range of discrepancy to acceptable levels compared to other studies. Intraoperative measurement of offset is difficult unless a specific measurement device is utilised. We have restored the femoral offset very accurately with a narrow range either side of the mean. We recommend a similar multimodal protocol to ensure restoration of leg length and offset to within narrow limits to help maximise function and patient satisfaction. This will undoubtedly also help minimise the risk of LLD litigation.

HIP JOINT CONTACT LOAD IN FEMOROACETABULAR IMPINGEMENT POPULATION DURING WALKING: AN EXPLORATORY STUDY

Giulia Mantovani[1], Mario Lamontagne[1], Paul Beaulé[2]
[1]School of Human Kinetics; [2]Department of Orthopaedic Surgery, University of Ottawa, Ottawa - Canada

Introduction: Femoroacetabular impingement (FAI) of type cam is characterised by an asphericity of the femoral head. High mechanical stresses at the site of the bone deformity are postulated to be a leading factor for FAI. Since *in vivo* measurements are invasive, musculoskeletal models are the most ethically acceptable approach to estimate hip joint contact load (HCL).
Objective: To investigate the differences in HCL between FAI and control participants.
Methods: FAI participants (n = 11) were recruited from a group of surgical patients, and 11 healthy controls (CON) were selected from the general population. Five gait trials were collected for every participant using a 10-camera motion capture system and 2 force plates for ground reaction forces. Muscle forces were estimated through static optimisation by using OpenSim. HCL was calculated including external and muscle forces contribution.
Results: The simulations produced a resultant HCL ranging between 1-6 body weights (BW), in accordance with the available literature. The overall amplitude of HCL was comparable between the two groups (CON and FAI). However, even if not statistically significant (p = 0.08), the FAI group showed a lower compressive force approximately in the 12:30 direction of the anterosuperior quadrant (in a clock-face reference system) of the femoral head and neck (4.62 ± 0.59 BW) respect to the CON group (5.04 ± 0.46 BW) at the end of the single-stance phase.
Conclusions: This study is the first to investigate HCL including muscle contributions in an FAI population. The results revealed an average 8.3% decrease in compression force of the hip for FAI group acting approximately in the direction of cam deformity location, possibly suggesting a protective mechanism of the joint. Walking does not require large hip range of motion and more prominent HCL alterations is less noticeable. For this reason, future studies should investigate HCL in more extreme conditions, such as squatting or stair descending.

Clinical Pathways

UNDERSTANDING THE PATIENT REPORTED FACTORS DETERMINING TIME TAKEN TO RETURN TO WORK AFTER JOINT REPLACEMENT

Benjamin Kleim[1], Ajay Malviya[2], Steven Rushton[3], David Deehan[1]
[1]Medical School; [3]School of Biology, Newcastle University, Newcastle upon Tyne - United Kingdom; [2]Department of Orthopaedics, Northumbria Healthcare Trust, Newcastle upon Tyne - United Kingdom

Aim: To quantify the relative significance or otherwise of patient reported variables upon time taken to return to work after THR or TKR in a working population.
Methods: Questionnaires about employment history, education, general health and experiences of returning to work after THR and TKR were administered by post and at outpatients' clinic. The chi-squared and *t*-test were employed.
Results: We recruited 102 patients; 52 THR and 50 TKR. Of these, 83 patients were employed pre-operatively and 80 returned to work at median 12 range 2-64 weeks. Having basic or no qualifications predicted a higher manual level of occupation (p = 0.021). Those in less manual occupations (p = 0.001), without pre-operative sick leave (p = 0.016) and a higher level of qualification (p = 0.041) returned to employment quicker.
Conclusions: Fewer qualifications predict more manual occupations. Those with preoperative sick leave, basic or no qualifications and more physically demanding occupations take longer to return to work. Operating patients before their arthritis forces them to be off work would improve rehabilitation and save costs associated with a long return to work. We suggest more tailored return to work time predictions to allow a faster return to work and avoid frustration.

PATIENT-REPORTED COMORBIDITY IS MORE ACCURATE THAN HOSPITAL-CODED COMORBIDITY WHEN PREDICTING PRIMARY HIP ARTHROPLASTY OUTCOMES: RESULTS FROM THE ADVANCING QUALITY ALLIANCE PATIENT COHORT

Luke C. Conway[1], Nicola J. Goodson[2], Nancy Prospero[3], Rao Janardhan[4]
[1]School of Medicine, University of Liverpool, Liverpool - United Kingdom; [2]Institute of Ageing and Chronic Disease, Faculty of Health and Life Science; University of Liverpool, Liverpool - United Kingdom; [3]Advancing Quality Alliance, Salford Royal Hospital, Manchester - United Kingdom; [4]Countess of Chester Hospital NHS Foundation Trust, Chester - United Kingdom

Background: Comorbid disease in hip arthroplasty has been shown to impact upon post-operative functional outcomes, hence are important to consider. Comorbidity burden can be ascertained with either patient reporting (PROM) or hospital-episode statistic coding (HES).
Aim: To assess and compare the impact of HES coded and patient-reported comorbidity burden on functional outcome in primary hip arthroplasty (THA) patients and to determine specific comorbid diseases that significantly affect hip arthroplasty functional outcome.
Methods: A total of 9,342 primary hip arthroplasty patients recruited as part of the Advancing Quality initiative completed pre- and postoperative PROM questionnaires to attain Oxford Hip Scores (OHS) and comorbidity burden from a list of 12 comorbid diseases/disease categories.
Association between OHS and either patient-reported or HES-coded comorbidity were assessed via logistic regression. Multivariate models were used to adjust for a high pre-op Oxford score and for co-existing comorbidities, reporting odds ratios (OR) with 95% confidence intervals.
Results: Our cohort consisted of 9342 patients from the Northwest of the United Kingdom underwent THA with a mean age of 68 (SD 10.7), collected as part of the Advancing Quality Alliance.
After multivariate modelling, several comorbid diseases were shown to be significantly associated with a decrease in post-op OHS. When patient-reported, these included peripheral vascular disease [OR 2.65 (1.79-3.91)], depression [OR 2.16 (1.47-3.17)] and nervous system disease [OR 2.95 (1.03-8.47)]. Depression [OR 2.42 (1.28-4.58)] and nervous system disease [OR 2.12 (1.25-3.62)] were also significantly associated when HES coded, as was coded respiratory system disease [OR 1.77 (1.30-2.40)]. Patient-reported high comorbidity burden (≥3 conditions) had a stronger inverse relationship with post-op OHS improvement [OR 0.50 (0.41-0.62)] than coded comorbidity [OR 0.63 (0.51-0.78)] and a stronger positive association with post-op OHS decrease [OR 1.90 (1.38-2.61)] than coded comorbidity [OR 1.64 (1.19-2.26)].
Conclusions: This study has highlighted specific comorbid diseases that can be detrimental to hip arthroplasty outcome, that cumulative comorbidity has an association with poor outcome and that patient-reported disease is a more sensitive predictor of post-arthroplasty outcome than HES-coded data. As such, more attention should be paid to patient-reported disease and for patients with the aforementioned comorbidities; focused care to optimise their outcome may be appropriate.

POSTOPERATIVE TOTAL HIP ARTHROPLASTY PATIENTS AND THEIR NEED FOR ONLINE INFORMATION AND ONLINE SUPPORT GROUPS

Marloes Schmitz[1], Nadja Wolf[1], Jaap Brunnekreef[1], Marjan Faber[2], B. Willem Schreurs[1]
[1]Department of Orthopaedics, Radboud Medical Centre, Nijmegen - The Netherlands; [2]Scientific Institute for Quality of Healthcare (IQ healthcare), Radboud Medical Centre, Nijmegen - The Netherlands

Introduction: It can be assumed that postoperative total hip patients do not feel the need to search for online information or participate in online support groups (OSGs), as their symptoms mostly have disappeared after the implantation of a THA. However, especially younger patients who will face future revisions due to their longer life expectancy might feel the need to keep updated and prepared for future revisions. The fact that they often suffer from rare or congenital causes of secondary osteoarthritis could make them more interested in OSGs.
Objectives: To examine the need for online information and OSGs of different groups of young postoperative THA patients.
Methods: We developed a cross-sectional questionnaire which consisted of 25 items. Questions asked covered the topics 'the need for online information and OSGs', 'future needs', 'accessibility of information', and the 'reliability of online information'. In addition, today's date was recorded and demographic data on

gender and age were collected. The study was conducted among postoperative THA patients who received a THA while younger than 50 at time of surgery at our Centre (n = 477).
Results: A total of 346 patients (72.5%) returned a completed questionnaire. 91% respondents had internet access, 61.0% of them reported to have searched online for information regarding THA during the pre- or postoperative period and were included for analysis. More than 66% of the postoperative THA patients reported a need for online information regarding THA. In contrast, only 35% reported a need for OSGs. Group analysis based on age, follow-up time, satisfaction, revision, and primary indication, did not show any differences in the need for online information or the need for OSGs between groups ($p \geq 0.14$).
Conclusions: About 1 in 3 postoperative THA patients have a need for OSGs postoperatively, while 2 in 3 postoperative THA patients report to have an evident need for online information.

SELECTING THE RIGHT HIP IMPLANT FOR OUR PATIENTS. THE DUTCH STRATEGY

Cees C.P.M. Verheyen[1], B. Willem Schreurs[2], Paul A. Bom[3], Jan A.N. Verhaar[4], Rob G.H.H. Nelissen[5], Jon Goosen[2], Rudolf W. Poolman[6]
[1]Member Task Force Hip of the Dutch Orthopaedic Association (NOV), Zwolle - The Netherlands; [2]Member Task Force Hip of the Dutch Orthopaedic Association (NOV), Nijmegen - The Netherlands; [3]Member Task Force Hip of the Dutch Orthopaedic Association (NOV), s'-Hertogenbosch - The Netherlands; [4]Member Task Force Hip of the Dutch Orthopaedic Association (NOV), Rotterdam - The Netherlands; [5]Member Task Force Hip of the Dutch Orthopaedic Association (NOV), Leiden - The Netherlands; [6]Member Task Force Hip of the Dutch Orthopaedic Association (NOV), Amsterdam - The Netherlands

Introduction: Problems with large head metal-on-metal hip prostheses (TH) encouraged Dutch orthopaedic surgeons to re-evaluate patient safety.
Objectives: Offer unequivocal evidence based information about performance of TH implanted in the Netherlands to patients. This should lead to a situation that all total hip prostheses implanted in the Netherlands have reliable clinical evidence. If not, these implants should be included in medical ethics review board approved.
Methods: The Dutch Orthopaedic Association (NOV) initiated a taskforce to classify the quality of TH based on survivorship. Two sources of data were used:1- national implant registry data; 2- Orthopaedic Data Evaluation Panel (ODEP)-ratings.
Prerequisites for the registry data were: at least 90% of all implants were registered (ISAR full member criterion); open access Internet was possible and a minimum of 500 patients were included.
Results: NOV 1A: *Full acceptance* (Benchmark): A hip implant (stem or cup) with a mean revision percentage of 10% or less at 10 years (endpoint: revision for any reason). Hence for 2013 the Swedish Hip Arthroplasty Register, the Danish Hip Registry, the AustralianNational Joint Replacement Registry and the National Joint Registry for England, Wales and Northern Ireland were used and implants with an ODEP-rating of 10A were also accepted.
NOV 1B: *Conditional acceptance* (Entry benchmark): A hip implant (stem or cup) with a mean revision percentage of 5% or less at 5 years. Substantiation: data from one of the above mentioned registers or an ODEP-rating of 5A or 7A.
NOV 2: *New implants:* Prostheses that do not meet the above mentioned criteria may only be implanted in a research programme with approval by the institutions medical ethics review board.
Note: if only the ODEPguidelines had been chosen, one quarter of our listed hip components would not have been included.
The actual 2014 listings (open access based on 2013-data):
http://www.orthopeden.org/uploads/jF/Ro/jFRotsvdGZWpYbkQd1LXmQ/General-procedure-and-list-Classification-of-Orthopaedic-Implants-2014.pdf
Conclusions: We offer patients insights in evidence based quality of the hip implants. This will facilitate shared decision making by empowering patients in their knowledge on available hip implants.

TRANEXAMIC ACID VERSUS FIBRIN SEALANT IN TOTAL HIP REPLACEMENT. A NON-RANDOMISED COMPARATIVE STUDY

Aaron Borbora, Gunasekaran Kumar, Peter Viju, Aatif Mahmood
Royal Liverpool and Broadgreen University Hospitals NHS Trust, Liverpool - United Kingdom

Background: The effectiveness of intravenous tranexamic acid (TA) in reducing blood loss and transfusion requirements during total hip replacement (THR) is well recognised. The aim of this study was to assess the effectiveness of a fibrin sealant in comparison to intravenous TA and a control group.
Patients and methods: We prospectively studied 270 patients with primary hip osteoarthritis who underwent a straight forward THR between February 2012 and September 2013. The first 70 patients acted as the control group. The next 100 consecutive patients received fibrin sealant spray before closure and the last 100 patients received 1g TA on induction. Demographic data, comorbidities, surgical time, surgeon grade, anaesthetic type, haemoglobin drop post-op and transfusion requirements were analysed using one-way ANOVA.
Results: The demographic characteristics, surgical time, surgeon grade, anaesthetic type and pre-operative haemoglobin of the 3 groups were comparable. Mean haemoglobin drop was less in the tranexamic acid and fibrin sealant group compared to the control group (2.76 vs 2.75 vs 3.43, p -0.03). Intra-operative blood loss was less in the TA group 412 vs 448, but this was not statistically significant. However, tranexamic acid was superior to fibrin sealant in decreasing allogeneic transfusion requirements (0% vs 9.6%, p = -0.02). There was no significant difference in terms of hospital stay or wound leakage problems in the postoperative period.
Conclusions: Both fibrin sealant and intravenous TA therapies are effective in reducing blood loss. However, TA use reduced post-operative transfusion requirements.

NO EFFECT OF LOCAL INFILTRATION ANAESTHESIA FOR TOTAL HIP ARTHROPLASTY BY ANTERIOR SUPINE INTERMUSCULAR APPROACH, A RANDOMISED PLACEBO CONTROLLED TRIAL IN 75 PATIENTS

Yvon den Hartog[1], Nina Mathijssen[1], Nick van Dasselaar[2], Pim Langendijk[3], Stephan Vehmeijer[1]
[1]Department of Orthopaedic Surgery; [2]Department of Anaesthetics; [3]Department of Pharmacology, Reinier de Graaf Hospital, Delft - The Netherlands

Introduction: Local infiltration analgesia (LIA) is frequently used during total hip arthroplasty (THA). However, only limited and inconclusive data regarding the effectiveness are available in literature. In our hospital, the Anterior Supine Intermuscular technique (ASI) is used for THA procedures. Lower postoperative pain scores have been described for this approach. Therefore, we studied the effectiveness of LIA in THA with ASI approach. Moreover, we hypothesised that LIA might be infiltrated more effectively when the incisions are made after the tissues have been infiltrated with local analgesia. Therefore we introduced the reversed-infiltration method, in which LIA is administered before the incision has been made.
Objectives: This study will investigate the effect of both standard and reversed LIA in combination with the ASI technique for primary THA.
Methods: In this prospective, randomised, placebo controlled trial we included patients diagnosed for primary THA by ASI technique. All patients received the same postoperative care regarding pain medication and mobilisation. Length of hospital stay (LOS) was measured by number of nights. Postoperative pain was determined with the NRS on multiple moments. Furthermore, the amount of postoperative consumption of pain medication was registered as well as the occurrence of side effects.
Results: Between November 1, 2012 and January 9, 2014, 75 patients were included. They were randomised into 3 groups of 25 patients. Mean LOS of all patients was 1.8 nights. There were no differences in LOS, surgery time, decrease of NRS, or use of pain medication between the three groups. Side effects after 8h and at day 2 were significantly more existent in the placebo group. However, these side effects had no influence on mobilisation of the patient.
Conclusions: This prospective, randomised, placebo controlled trial demonstrated no significant clinically relevant effect of LIA for THA with the ASI approach.

LOCAL INFILTRATION ANAESTHESIA IN TOTAL HIP ATROPLASTY. A DOUBLE-BLINDED RANDOMISED CONTROLLED STUDY

Tina Strømdal Wik, Janne Hofstad, Otto Schnell Husby, Siri Bjørgen
Department of Orthopaedic surgery, St Olavs Hospital, Trondheim - Norway

Introduction: The Local infiltration analgesic (LIA) technique has been widely used to reduce opioid requirements and improve postoperative mobilization following total hip and knee arthroplasty. The evidence for LIA in total knee arthroplasty seems clear; however the evidence for LIA in total hip arthroplasty (THA) remains to be clarified.
Objectives: The aim of this study was to evaluate whether a single shot LIA in addition to a multimodal analgesic regimen would reduce acute postoperative pain and opioid requirements after THA.
Methods: There were 118 patients undergoing THA under spinal anaesthetic included in this randomised double-blinded placebo-controlled trial. All patients

received oral opioid-sparing multimodal analgesia; Eterocoxib, Acetaminophen and Glucocorticoid. In addition the patients were allocated to 150 ml Ropivacain 2mg/ml and ½ ml Epinephrine 1mg/ml, or 150 ml saline 0, 9%. In addition patients received oral or intravenous analgesic as needed. The primary endpoint was Numeric Rating Scale (NRS) during mobilisation in the recovery unit. We also examined the NRS score during mobilisation the day after surgery and the total opioid consumption the first postoperative day.
Results: The mean NRS score during mobilisation at the recovery unit was 2.6 in the placebo group and 2.7 in the LIA group (p = 0.82). The mean NRS scores during mobilization the first day after surgery were respectively 4.1 and 4.4 in the 2 groups (p = 0.43). There were no significant differences between the opioid consumption between the 2 groups.
Conclusions: This study shows that there is no need for LIA in THA patients in addition to the multimodal analgesic regimen used in this study.

PAIN MANAGEMENT FOLLOWING TOTAL HIP REPLACEMENT (THR): REPORTING ON OUR EXPERIENCE USING LOCAL INFILTRATION ANAESTHETIC (LIA) TECHNIQUE AND PAINKWELL PUMP SYSTEM

Mohammad Salhab[1], Pete Kimposn[2], Jonathan Freeman[1], Todd Stewart[3], Martin Stone[4]
[1]Leeds Musculoskeletal Biomedical Research Unit, Chapel Allerton Hospital, Leeds - United Kingdom; [2]National Institute of Health Research, Leeds - United Kingdom; [3]University of Leeds Mechanical Engineering Unit, Leeds - United Kingdom; [4]University of Leeds Mechanical Engineering Unit, Chapel Allerton Hospital, Leeds - United Kingdom

Introduction: 70% of patients require morphine after THR. Despite opiates, moderate to severe pain has been reported in up to 58% of patients in the first 48 hours following surgery. LIA has been described as a method to reduce postoperative pain following THR. An intra-articular catheter can also be used to continuously infiltrate local anaesthetic into the joint.
Objectives: In this study, we report on our experience using LIA in addition to the PainKwell pump system (Peak Medical) of continuous infusion of 0.25% bupivacaine for 48 hours post THR.
Methods: Between June 2011 and Dec 2013, 173 consecutive patients undergoing primary THR were prospectively followed up. The 5 intervention groups received:
Group 1: general anaesthetic (GA) only. 31 patients,
Group 2: spinal anaesthesia (SA) only. 37 patients,
Group 3: SA plus LIA_1 only. 38 patients,
Group 4: SA plus LIA_2 only. 34 patients,
Group 5: SA plus LIA_1 plus PainKwell pump system for 48 hours. 33 patients.
LIA_1 mixture: 0.25% ropivacaine HCL, ketorolac and adrenaline diluted to 300 mls of 0.9% normal saline (NS).
LIA_2 mixture: 0.5% Marcaine diluted to 100 mls of 0.9% NS.
PainKwell pump system: 0.25% bupivacaine HCL in 250 mls of 0.9% NS. Infiltration rate was set at 4 mls/hr for 48 hours.
Results: Statistical analysis using Kruskal-Wallis test revealed that the number of patients requiring morphine in groups 3, 4, and 5 were significantly reduced compared to groups 1 and 2 by at least 50% (H(2) = 6.06, p = 0.036). There was also a significant reduction of more than 30% in the number of patients requiring morphine in groups 3 and 5 compared to group 4. Statistically, the least number of patients requiring 10mg morphine during 12-24 hrs was in group 5.
Conclusions: This study demonstrated that the PainKwell pump system in addition to LIA_1 provided maximal pain relief following THR. We recommend the use of LIA_1 with PainKwell pump system as an efficacious method to control pain during the 48 hours following THR.

NORWICH ENHANCED RECOVERY PROGRAMME FOR ELECTIVE TOTAL HIP ARTHROPLASTY: IS IT BENEFICIAL IN PATIENTS AGED OVER 80?

James Corbett, Tim Harrison, Elizabeth Pinder, Akash Soogumbur, James Wimhurst
Department of Orthopaedics, Norwich - United Kingdom

Introduction: Enhanced recovery programmes for total hip arthroplasty (THA) have been shown to be beneficial in reducing length of stay and improving postoperative pain. Since the implementation of an enhanced recovery programme at our institution, the median length of stay for THA patients has reduced by 4 days.
To our knowledge, there has been no previous work investigating the efficacy of enhanced recovery programmes in patients aged over 80, who tend to be frailer and can have more complex social needs that can delay discharge.
Objectives: To investigate whether the Norwich Enhanced Recovery Programme (NERP) reduced length of stay, blood loss and transfusion requirements in patients aged over 80.
Methods: A case controlled series of patients aged over 80 undergoing THA pre- and post implementation of NERP. Cases were matched for age, sex, ASA grade and surgeon. Length of stay, postoperative haemoglobin drop and transfusion requirement were analysed. Statistical tests including Mann Whitney test for length of stay, unpaired *t*-test for Hb drop and Fisher's exact test for number of patients transfused were performed using GraphPad Prism 6.0.
Results: A total of 55 patients were identified in each group. Mean age of 85 in both. Median length of stay reduced from 7 days pre-NERP to 6 days post-NERP (p = 0.02). Blood loss, as assessed by mean haemoglobin drop, reduced from 3.11g/dl pre-NERP to 1.96g/dl post-NERP (p<0.0001). Number of patients transfused reduced from 13/55 pre-NERP to 3/55 post-NERP (p = 0.01).
Conclusions: NERP significantly reduced the length of stay, blood loss and transfusion requirements in patients aged over 80 undergoing THA. The reduction in length of stay was less pronounced than in younger patients.
Based on these findings we believe that the NERP may benefit elderly patients undergoing arthroplasty for hip fractures by reducing blood loss and transfusion requirement but is unlikely to markedly reduce the length of stay.

TOTAL HIP ARTHROPLASTY USING THE ACCELERATED RECOVERY PROTOCOL

Lukas Kolodziej, Andrzej Bohatyrewicz
Katedra i Klinika Ortopedi i Traumatologii i Onkologii Nrzadu Ruchu, Szczecin - Poland

Introduction: Optimisation of perioperative protocol within the framework of evidence based medicine was created at authors institution. The aim of that protocol is to reach the same "milestones" in total hip arthroplasty more effectively and faster.
Objectives: The specific objectives of this study were: To compare length of hospital stay after accelerated and standard protocols of perioperative management. To compare the early results of treatment between protocols. To determine the most important factors to reduce length of hospital stay. To compare the incidence of complications and hospital readmissions after either protocol.
Material and methods: The prospective study enrolled 164 unselected patients. Following randomisation 81 were assigned to study group and 83 to control group. The mean age was 64 years (31-86). There were 92 (58%) females and 72 (42%) males. No significant differences between groups were noted. In all treated patients the same anaesthesia, surgical approach and implant type were used. Treatment outcomes was assessed with subjective Oxford Hip Score. Average follow-up was 12 months.
Results: None of the patient from study group required readmission due to complications during follow-up period in opposed to 4 (4.8%) patients from the control group. The mean length of stay in the study group was 2.5 days (from 1 to 5 days) compared to 7.1 days in control group (from 4 to 15 days).
Conclusions: A significant shortening of hospital stay was achieved in patients undergoing THR with modified protocol. Early results are significantly better with use of modified protocol in comparison to the standard procedure. Qualification to the accelerated protocol group and the type of preoperative employment (blue collar versus white collar workers) was the most important factors influencing the length of hospital stay.

Stem Revisions

ANALYSIS OF EARLY REVISION OF PRIMARY CEMENTED, CEMENTLESS, HYBRID AND RESURFACING HIP ARTHROPLASTY

Sarah Gill[1], Robert Lawton[1], Jessica Thompson[2], Linda Johnston[1], Gavin Love[1]
[1]Trauma and Orthopaedic Department, Ninewells Hospital and Medical School, Dundee - United Kingdom; [2]University of Dundee, Ninewells Hospital and Medical School, Dundee - United Kingdom

There is much emphasis on *long-term* survivorship of total hip arthroplasty (THA). By examining *early*, *unanticipated*causes of THA failure, we may better appreciate pitfalls of each modality and improve surgical technique.
The incidence and modality of early revision (<5 years post primary) of 2779 consecutive primary hip arthoplasties was examined. All included resurfacings were BHR.

Overall revision rate at 5 years was 2.32%: Cemented: 1.41% (10/711); Hybrid: 1.94% (21/1081); Uncemented: 2.85% (13/456); Resurfacing: 3.63% (20/551). Resurfacing had a significantly higher 5-year revision rate compared to cemented (p = 0.014) and hybrid (p = 0.045) THAs.
All four types of THA are susceptible to four common modes of failure: recurrent dislocation, infection, fracture and aseptic loosening. Thereisno statistically significant inter-group differences in the rates of these failures. There was a statistically significant difference (p<0.05) between the revision rates foraseptic loosening when comparing both resurfacings and cementless THAswith both cemented and hybrid THAs.
Resurfacing revision indications additionally included pseudotumour, failure to seat acetabular component and AVN. The higher rate of revision among resurfacings is related to additional niche vulnerabilities rather than a single mechanism. Awareness of these risks identifies areas of technical focus for the surgeon and aids patient counselling.

COMPARISON OF RE-REVISION RATES FOLLOWING REVISION OF CEMENTED AND CEMENTLESS PRIMARY TOTAL HIP ARTHROPLASTY

Peter Gebuhr[1], Alma Pedersen[2], Søren Overgaard[3], Kirill Gromov[1], Henrik Malchau[4], Anders Troelsen[1]
[1]Department of Orthopedic Surgery, Copenhagen University Hospital Hvidovre, Copenhagen - Denmark; [2]Department of Clinical Epidemiology, Aarhus University Hospital, Aarhus - Denmark; [3]Department of Orthopaedic Surgery, Traumatology and Clinical Institute, Odense University Hospital, Odense - Denmark; [4]Orthopaedic Department, Massachusetts General Hospital/Harvard Medical School, Boston - USA

Introduction: Increased use of uncemented technique for primary THA in most parts of the world can lead to changes in reoperation patterns, ie indications for revision, and potentially influence the survival of a following revision arthroplasty. In this registry-based study we wanted to investigate the role of primary femoral fixation, cemented versus cementless, on survival of revision arthroplasty.
Methods: Primary THAs with cemented (n = 1889) and uncemented (n = 805) femoral component that subsequently sustained 1st revision of femoral component were identified from the Danish Hip Registry during 1995-xx. Survival of 1st revision THA, with 2nd revision of the femur as outcome, was evaluated using crude and adjusted hazard ratios (HR). Patient demographics and indications for revision were also recorded.
Results: 71.6% of cemented primary THAs were revised due to aseptic loosening compared to 24.5% of uncemented primary THAs (p<0.0001). 46.1% of uncemented primary THAs were revised due to femoral fracture compared to 10.0% of cemented primary THAs (p<0.0001). Adjusted HR for 2nd revision due to any reason of uncemented compared with cemented primary THA with 1st revision was 1.47; 95% CI (1.13 -1.91). Adjusted HR for 2nd revision due to aseptic loosening of uncemented compared with cemented primary THA with 1st revision was 1.23; 95% CI (0.81-1.87). Median age at the time of 1st revision was 73 and 67 for cemented and uncemented primary THAs, respectively.
Conclusions: We found significantly 47% increased risk of 2nd revision after 1st time revision performed on primary cementless compared to cemented THA considering all causes for revision. Different indications for 1st revision, as well as age at the time of first revision could potentially explain inferior survival of revision performed on cementless THA. Our data suggest that increased use of uncemented fixation in primary THA may lead to inferior survivorship of 1st revision THA.

CLINICAL AND RADIOGRAPHIC ANALYSIS OF 208 FEMORAL COMPONENT REVISIONS WITH IMPACTION BONE-GRAFTING AND A CEMENTED POLISHED EXETER STEM

Martijn A.J. te Stroet, Wim H.C. Rijnen, Jean W.M. Gardeniers, Albert van Kampen, B. Willem Schreurs
Department of Orthopaedics, Radboud University Medical Centre, Nijmegen - The Netherlands

Introduction: Impaction bone-grafting is an attractive biological method of reconstruction in femoral revision hip arthroplasty since it can restore bone stock loss.
Objectives: The purpose of this study was to evaluate the clinical and radiographic outcomes of cemented femoral component revisions with use of impaction bone-grafting.
Methods: 208 consecutive femoral reconstructions that were performed between March 1991 and December 2007 with use of the X-change femoral revision system, fresh-frozen morselised allograft and a cemented polished Exeter stem were followed prospectively. The average age of the patients was 65 years (range 30 to 86). One patient was lost to follow-up after six years and data were included until this point.
Results: After a mean follow-up of 10.6 (range 4.7- 20.9) years a femoral re-operation for any reason was performed in 33 hips (15.9%). In 13 of these 33 hips the femoral component was re-revised (6.3%). The survival rate at 10 year for femoral re-revision for any reason was 94.9% (95% confidence interval [CI] 90.2 to 97.4) and for femoral re-revision for aseptic loosening 99.4% (95% CI 95.6 to 99.9).
Conclusions: Femoral revision with use of impaction bone-grafting and a cemented polished stem results in an excellent survival rate.

HIP REVISION SURGERY WITH THE MODULAR REVISION STEM

Lucio Piovani[1], Loris Perticarini[2], Valeria Peschiera[2], Francesco Benazzo[2]
[1]Ortopedia e Traumatologia, Azienda Sanitaria Ospedaliera S. Croce e Carle, Cuneo - Italy; [2]Ortopedia e Traumatologia, Policlinico San Matteo, Pavia - Italy

Introduction: The Lima Revision stem is a cementless, modular, tapered stem with longitudinal fins to support rotational stability designed in accordance with the philosophy of Wagner.
Objectives: The aim of this retrospective study was to evaluate the long-term clinical and radiographic outcomes of revision hip surgery with the Revision stem.
Methods: Between May 2001 and July 2011, 105 patients underwent revision hip surgery with the revision stem due to aseptic loosening in 79 (75.2%) cases, infections in 5 (4.8%) cases and periprosthetic fractures in 21 (20.0%) cases. A total of 77 cases required osteotomy according to Wagner technique for explantation of the previous stem; 62 (59%) cases also required an acetabular revision with implant designs according to the bone defects. Clinical evaluation with the Harris Hip Score (HHS) and radiographic analysis to assess implant stability were performed.
Results: The average follow-up is 78 months, with a maximum of 12 years. Radiographic assessment demonstrated that all stems had good stability at the last follow-up. At 6 months, the critical metaphyseal zone regained stability with wide bone neo-formation. The average Harris Hip Score significantly improved from 42 (range 30-65) preoperatively to 86 (range 67-99) with 80% of satisfactory results. In 9 (8.5%) cases, a bone femoral graft was required to fill bone defects caused by wear or loosening. Intraoperative complications included 7 metaphyseal fractures during explantation. No length leg discrepancy greater than 1 cm was found. Postoperative complications included 3 dislocations, treated conservatively, and 3 periprosthetic fractures, solved with cerclage wiring of the femur. No 2-stage revisions occurred.
Conclusions: The Revision stem ensured effective restoration of biomechanical joint parameters in all revision cases and allowed early mobilisation and weight bearing, leading to satisfactory clinical outcomes.

A CROSS-SECTIONAL STUDY WITH 6-20 YEARS FOLLOW-UP OF UNCEMENTED WAGNER REVISION STEMS. REOPERATIONS BONE MINERAL DENSITY, BMD, AND CLINICAL EVALUATION

Hans Mallmin
Department of Orthopaedics, Uppsala - Sweden

Introduction: Periprosthetic bone loss is a potential problem for uncemented primary and secondary total hip arthroplasty. Risk factors to consider are time to follow-up, diameter of the stem, stem design to mention a few. The uncemented Wagner revision stem was introduced at our unit 1991.
Objectives: We conducted a retrospective and cross-sectional study from our local total hip arthroplasty registry 1991-2011.
Material: Patients revised with an uncemented Wagner stem during 1991 till 2005 were identified (392 Wagner revisions). Study 1. Only patients (n = 105 patients with 112 hips) below the age of 85 years of age at follow-up, were followed, in the local total hip registry for reoperations and stem revisions, Study 2. Patients below the age of 85 at follow-up, operated with non transfemoral revisions with the Wagner stem were investigated for BMD with DXA (n = 43 with 46 hips). Potential risk factors for BMD such, length of follow-up, stem diameter, length, gender, age BMI were analysed correlations. p>0.05 was considered significant.
Results: Study 1: During the follow-up period was 10.3 ± 4.1 yrs, 66 reoperations were performed; 30 closed reduction, 10 cup revisions, 8 stem revisions, 6 infection, 2 wire extractions, 2 fixation of the greater trochanter and 8 miscellanous operation, resulting in a stem survival of 93%. Study 2. There were no significant correlations for BMD to follow-up, BMI, Charnley class, medication

with steroids or number of applied wires. Female gender, old age and big stem diameter were negatively correlated to BMD. Merle d'Aubignier scored for pain 5.2, walking 4.6 and joint motion 4.9 for the revised hip versus 5.4, 4.8 and 5.3 for the contralateral side respectively.
Conclusions: Revision with the uncemented Wagner stem showed a 93% survival rate with an average follow-up of more than 10 years although the patients were subject to more than 50% reoperations for various other reasons. Time was not correlated to periprosthetic bone loss.

THE ITALIAN-SPANISH EXPERIENCE WITH CEMENTLESS MODULAR REVISION STEM: OUTCOME OF 139 HIP AFTER AN AVERAGE OF 5 YEARS FOLLOW-UP

Vittorio Bellotti[1], Federico De Meo[2], Emanuele Astarita[1], Carlomagno Cardenas Nylander[1], Manuel Ribas Fernandez[1], Pietro Cavaliere[2]
[1]Hip Unit - ICATME Quiron Dexeus, Barcelona - Spain; [2]GIOMI Istituto Ortopedico del Mezzogiorno d'Italia "Franco Scalabrino", Messina - Italy

Introduction: As primary total hip replacements become more common in older patients and younger, physically active patients, the number of revision arthroplasties will also increase. Femoral bone loss, primary stability achievement, possible infections, hardware failure are a challenge for a surgeon performing revision arthroplasty. Removal of a prosthesis stem, severe femoral osteolyses due to poly debris or thick femoral cement mantles can cause intraoperative femoral defects or fractures that need to be bridged by long revision stem. The implant has to be adapted exactly to the diameter of the femoral medullary canal and fixed distally to the pathololological zone. Factors such as pelvitrochanteric muscles, joint instability, leg lenght discrepancy must be taken in consideration. To solve these problems, modular revision prostheses are now used. The main advantage of this prosthesis is the possibility to choose diaphyseal stem (length and diameter) independently from metaphyseal proximal body, modular neck and head size
Objectives: The aim of this study was to scrutinise the outcome of 139 cementless modular stem revision using the Profemur R (Wright Medical Technology, Arlington USA) with a minimum follow-up of 2 years and an average follow-up of 5 years.
Methods: In this multicentric study, 235 revision arthroplasties of the hip with a Profemur R revision stem were performed between 1 January 2003 and 31 December 2011. After an average follow-up of 5 (range 2-8) years, we could evaluate 189 patients clinically and radiologically. There were 102 men and 87 woman. The mean age of the patients at the time of the operation was 68 (range 37-89) years. The mean weight of the patients was 74 (range 44-115) kg. The revision indications were: 117 aseptic loosening of cup and stem, 47 aseptic loosening of the stem, 22 septic loosening, 3 Girdlestone hip.
The intrafemoral approach (91 patients) was used more often than the transfemoral approach (48 patients). Femoral bone defects were classified according to Paprosky criteria. The range of stem diameters used in this study was 12-23 mm, the 3 lengths of stems were used (95 - 115 -135), the range of proximal body size was 50-80 mm. The patients were clinically and radiologically examined. The Harris Hip Score and the WOMAC score were measured preoperatively and postoperatively. Anteroposterior and axial radiographs of the hip and the upper femur were analysed for radiolucent lines, changes in bone density, cortical hypertrophy, heterotopic ossification and subsidence of the femoral stem. Radiolucencies were classified according to Gruen criteria, femoral stability according to Engh criteria and heterotopic bone formation according to Brooker classification.
Results: The HHS improved from preoperative 50.2 ± 27.2 to postoperative 88.2 ± 31.5, the WOMAC Score improved from preoperative 45.2 ± 22.2 to postoperative 88.2 ± 40.5. The intraoperative and postoperative complications were registered. The main intraoperative complication was a femoral fissure or fracture in 5 patients. Dislocations occurred in 8 cases mostly for the poor muscles structures. Subsidence was observed in 2 cases where the stem was under-dimensioned. Infection treated with a two stage revision occurred in 9 cases. A stem fracture was observed in 1 overweight patient. There were no progressive osteolyses on the last radiographs in 142 patients.
Conclusions: Satisfactory clinico-functional results with high survivorship, low dislocation and rate can be expected by means of THR with modular stems in long-midterm. This device represents a valid alternative to traditional monoblock cemented implants.

RE-PERIPROSTHETIC FEMORAL FRACTURES. FOLLOW-UP OF 303 PERIPROSTHETIC FRACTURES

Jacques Tabutin, Olivier Gastaud, German Filippi
Service de chirurgie orthopédique, Centre hospitalier, Cannes - France

Introduction: periprosthetic fracture (PF) is the third most common cause of revision after hip arthroplasty. Unfortunately, after their surgical treatment, 23% to 35% will require further surgery. The first or second cause of revision after PF, according to the literature, is re-periprosthetic fracture (re-PF).
Objectives: To assess the incidence, management and evolution of re-PF, as well as their appropriate nomination and classification.
Methods: In a single-centre retrospective study, we followed 303 PF with clinical and radiographic analysis. We divided the re-PF in 3 groups: de Novo (different localisation), Iterative (same site) and Secondary displacement of fracture. We noted the type of trauma, its functional evolution through Harris Hip Score (HHS) and Postel-Merle d'Aubigné (PMA), healing time, mobility, and further surgery.
Results: Out of the 303 cohort, 31 re-PF occurred (11%). Four patients were lost to follow-up (FU). The mean age of the remaining 27 re-PF was 80 (46-99), 24 women and 3 men. We found 19 re-PF de Novo, 3 Iterative and 5 Secondary displaced fractures. The 19 re-PF with well fixed implants were treated with ORIF (18) or conservatively (1). The 8 re-PF, with loose implants, were revised with an interlocked stem. Before the first PF, mean HHS was 97 (65-100) and PMA was 17.6 (18-13). At last FU of 34 months (12-146) after re-PF, clinical results dropped by nearly 2 functional levels: HHS 73 (95-55) and PMA 13 (17-9). Seven patients required further surgery (3 recurrences of re-PF, 2 aseptic loosenings and 2 recurrent instabilities).
Conclusions: re-PF represented 11% of all our PF. No specific series on re-PF have been published. All secondary displacements were spontaneous, and due to poor bone quality, wrong surgical management or postoperative care. De Novo fractures were not easy to treat because of poor bone quality and little available room for implant purchase. Whatever the treatment, a re-PF carries a poor functional prognosis.

Tribology/Polyethylene

UHMWPE ACETABULAR LINERS: MATERIAL, TREATMENTS, COUPLING DIAMETER AND DESIGN. WHAT REALLY MATTERS?

Paolo Dalla Pria[1], Luca Giorgini[1], Alessandro Giusto[1], Luigi Costa[2]
[1]Limacorporate, San Daniele del Friuli (UD) - Italy; [2]Department of Chemistry, University of Turin, Torino - Italy

Introduction: Different Crosslinked UHMWPEs are available on the market. Remelting (RXPE) guarantees excellent wear behaviour and absence of oxidation, however, for some specific liner design fatigue fractures have been reported. Due to this limit RXPE is being replaced by the introduction of Vitamin E (VEXPE) to balance wear, oxidation and mechanical strength.
Objectives: This study compared tribological, mechanical and oxidation behaviour of standard UHMWPE (STDPE), RXPE and VEXPE to understand the influence of the femoral head in terms of diameter and material and to verify the fatigue safety of a thin VEXPE acetabular liner.
Methods: A single acetabular liner design has been produced in: STDPE, RXPE (75 kGy), VEXPE (Vit.E 0.1%, 75 kGy). Head diameters of 28, 36 and 40 mm have been used, in CoCrMo and Biolox Delta ceramics.
Wear tests (5 million cycles) have been performed according to ISO 14242.
Small punch test and Oxidation index calculation has been performed for each material.
Fatigue tests have been performed on the VEXPE with a minimum thickness of 4.2 mm.
Results: STDPE showed the highest wear rate and RXPE showed the best wear performance, both regardless head size and material. VEXPE wear is higher than RXPE and much lower than STDPE (RXPE:VEXPE:STDPE = 1:2.5:17).
The small punch test showed a significant decrease of the Work to Failure for the RXPE (-30%). STDPE and VEXPE are comparable.
Oxidation index after 2 weeks aging was below the safety limit for each material.
No mechanical failures have been found in the VEXPE fatigue tested.
Conclusions: Despite RXPE offers the lowest wear rate and the absence of oxidation, VEXPE highly reduces the wear compared to the STDPE and avoids the mechanical failures of the RXPE, mostly related to the shape of the acetabular liners.
The head diameter influences the wear of STDPE and it is not effective on the RXPE. VEXPE is slightly influenced because of the X-Linking partial inhibition by Vitamin E.
The material of the head does not show a statistically significant influence.

POLYETHYLENE WEAR OF THE CUP IN TOTAL HIP REPLACEMENT WITH MULLER REINFORCEMENT RING

Aurimas Sirka[1], Martin Clauss[2], Sarunas Tarasevicius[1], Hans Wingstrand[3], Justinas Stucinskas[1], Thomas Ilchmann[2]
[1]Department of Orthopaedics, Lithuanian University of Health Sciences, Kaunas - Lithuania; [2]Department of Orthopaedic Surgery, Kantonsspital Liestal, Liestal - Switzerland; [3]Department of Orthopaedics, Lund University and Lund University Hospital, Lund - Sweden

Introduction: Polyethylene (PE) wear contributes to the process of aseptic loosening and is seen as the one important reason for late failure after total hip replacement (THR). THR with Muller reinforcement ring (ARR) have showed favourable mid-term survival results, but we found no studies investigating PE wear in combination with ARR.
Objectives: The aim of the study was to investigate PE wear in THR with ARR followed ≥10 years.
Methods and materials: We performed 321 consecutive primary arthroplasties with ARR in 291 patients, between 1984 and 2002. For long-term wear and radiological analysis THR patients with ARR and cemented PE cup with at least 10 years radiological follow-up were included, leaving 133 THR implanted in 123 patients. For wear analysis linear and volumetric wear were measured. The analysis of age, gender, body mass index, head material, and head size in relation to volumetric wear was conducted using multiple regression analysis. Radiological assessment included evaluation of osteolysis, migration, and loosening.
Results: For wear and radiological analysis we included 43 males and 80 females with a mean age of 65 years (31-86, SD 10) and a mean follow-up of 13 years (10-23, SD 3.6). Out of 133 ARR, 9 were classified as loose and out of those 4 had osteolysis. Mean PE linear wear rate for all hips was 0.06 mm/year (SD 0.51), volumetric - 37 mm3/year (SD 25.5). The loose ARR had a mean wear rate of 0.07 mm/year (SD 0.04), volumetric - 52 mm3/year (SD 32.3). The highest wear rates were found for hips requiring acetabular component revision (mean 0.09 mm/year, SD 0.04, mean 64 mm3/year, SD 38.1). Only larger head size diameter independently of head material affected increased volumetric wear in multiple regression analysis, $p<0.001$.
Conclusions: We conclude that THA hips with ARR followed >10 years showed favourable wear rates as compared to conventional cups, larger head diameter being the only factor affecting greater volumetric wear.

IS WEAR LOW AND FUNCTIONAL RECOVERY BETTER OR FASTER WITH A LARGE VERSUS SMALL FEMORAL HEAD AGAINST HXLPE?

Bernd Grimm, Rachel Senden, Ide Heyligers
AHORSE Research Foundation, Atrium Medical Centre, Department of Orthopaedics, Heerlen - The Netherlands

Introduction: Large femoral heads (LH) increase the head/neck ratio and jump distance, thus reducing dislocation rates. It is also claimed that LH lead to a more physiological reconstruction and thus better and faster functional recovery. However, in conventional PE, volumetric wear increases with head size and in LH may exceed osteolytic thresholds. With highly crosslinked and oxidation stabilised PE (HXLPE) wear rates could be so low that LH could be safely tolerated.
This study compares small versus large femoral heads with regards to HXLPE wear and objectively measured functional recovery.
Patients and methods: A total of 40 OA patients (avg, age: 65yrs, F/M = 28/12) indicated for primary, unilateral THR were operated using the same stem (Stryker Symax) and cup (Stryker Trident) but randomised to a standard small (SH = 28 mm) or large femoral head (LH = 40 mm) with matching HXLPE insert (Stryker X3).
This study reports the results at 2 years (n = 26) excluding 3 patients lost to unrelated death or disease and 3 complications (2 infections, 1 luxation) leaving n = 20 subjects for analysis (LH = 13, SH = 7).
Patients were assessed pre-op and at frequent intervals using HHS, digital wear measurement (Roman V1.7) and wearable inertial sensor motion analysis for gait, sit-stand and step-up.
Results: Both groups self reported equally good clinical outcomes (HHS = 89.4) comparable to other studies.
The average (<0.1 mm/year) and even highest PE penetration rates were comparable between both groups and so low that they reach the resolution of the measurement method (0.1 mm) or the level of creep (up to 0.2 mm).
Objective function improved slowly reaching or exceeding pre-op levels only at 6 months or beyond. No significant difference in level or speed or recovery was found between groups.
Discussion: At 2 years FU, XLPE penetration of large versus small femoral heads seems the same and so low that wear rates appear to be safe even in 40 mm large heads. Despite the use of objective motion analysis, a higher or faster functional recovery could not be shown for large heads.

LOW WEAR IN A MODERATELY CROSSLINKED POLYETHYLENE CUP IN 32MM ARTICULATION. TWO YEARS RSA MEASUREMENT OF WEAR AND MIGRATION

Bernhard Flatoy, Stephan Maximillian Röhrl, Lars Nordsletten, Jonas Rydinge, Jon Dahl
Department of Orthopaedic Surgery, Oslo University Hospital, Oslo - Norway

Introduction: Wear products from polyethylene (PE) cups contributes to the process of aseptic loosening, and efforts have been made to reduce wear. Crosslinked PE (XLPE) has shown reduced *in vivo* wear up to 10 years. Crosslinking by irradiation produce surplus free radicals with harmful oxidative potential. This problem has been addressed by heating, which on the other hand cause unwanted changes in its mechanical properties. The optimal balance between irradiation and heating has yet not been found. The Marathon crosslinked PE acetabular cup is produced by irradiating GUR 1050 PE by 5 m Rad, melting and then sterilisation in gas plasma.
Objectives: Examination of wear and stability in Marathon cemented cups against 32 mm heads.
Methods: The cohort consists of 70 hips implanted with cemented Marathon cups. The patients were randomly allocated to two different types of cemented femoral stems with either 32 mm stainless steel or CrCo heads as a separate part of the trial. We examined wear and migration by RSA, osteolysis by x-ray and clinical results by Oxford Hip Score at 3, 12 and 24 months.
Results: Average proximal wear was 0.11 mm (95% CI 0.09-0.14) and 3D wear 0.15 mm (95% CI 0.13-0.17) at 2 years. There was no statistically significant difference between the different stem/head groups. Approximately half of the measured wear occurred during the first 3 months, and is probably due to "bedding in" phenomena. Subsequent wear decreases considerably to an average rate of 0.03 mm/year thereafter.
Conclusions: In this cohort of moderately XLPE cups against 32 mm heads, we found low wear rates comparable to previous trials on the Marathon cup examining uncemented cups against 28 mm heads, as well as other highly XLPE cups.

POROUS TITANIUM CUP WITH VITAMIN E-LINER COMPARED TO CONVENTIONAL CUP IN TOTAL HIP ARTHROPLASTY. A RANDOMISED TRIAL

Mats Salemyr, Olle Muren, Ghazi Chammout, Torbjörn Ahl, Henrik Bodén, André Stark, Olof Sköldenberg
Department of Clinical Sciences, Danderyd Hospital, Karolinska Institutet, Stockholm - Sweden

Introduction: We hypothesised that a titanium shell backside with increased porosity, aiming at enhanced bone ingrowth, and a vitamin E-treated polyethylene articulating liner had less periacetabular bone loss and lower polyethylene wear than a conventional acetabular cup.
Patients and methods: A total of 51 patients with primary hip osteoarthritis were randomised to either a cup with porous titanium construct backside and vitamin E-treated highly cross linked polyethylene (HXLPE) (treatment group, n = 25) or a conventional porous coated titanium cup and standard HXLPE liner (control group, n = 26). The primary outcome variable was change in periacetabular bone mineral density (BMD), measured with dual energy x-ray absorptiometry (DEXA), two years after surgery. Secondary outcomes were implant fixation and polyethylene (PE) wear, measured with radiostereometry (RSA). Hip function (Harris Hip Score) and quality of life (EQ-5D) were also evaluated using self-administered score protocols.
Results: The pattern of bone remodelling, as percentage change in periacetabular BMD in 4 regions of interest, was similar in the 2 groups with almost complete restoration to baseline values. BMD diminished in the 2 proximal zones and increased in the 2 distal ones. After minimal migration up to 6 months all implants in both groups became stable. Polyethylene creep, up to 12 months after surgery, was significantly lower for the vitamin E-treated liner. No significant difference in liner wear was seen between 12 and 24 months. We found no differences in clinical outcome between the groups.
Conclusions: In this prospective, randomised, controlled trial on a new porous titanium cup and a E-vitamin diffused liner we found, compared to a conventional cup, lower initial creep but no differences regarding periacetabular bone preservation, implant fixation or polyethylene wear up to 2 years postoperatively.

THREE-YEAR MULTICENTRE RSA EVALUATION OF VITAMIN E DIFFUSED HIGHLY CROSS-LINKED POLYETHYLENE LINERS AND ACETABULAR CUP STABILITY

Nanna H. Sillesen[1], Meridith Greene[2], Poul T. Nielsen[3], Mogen B. Lauersen[3], Anders Troelsen[1], Henrik Malchau[2]
[1]Clinical Orthopaedic Research Hvidovre, Department of Orthopaedics, Copenhagen University Hospital Hvidovre, Hvidovre - Denmark; [2]Harris Orthopaedic Laboratory, Massachusetts General Hospital, Harvard University, Boston - USA; [3]Department of Orthopaedics, Aalborg University Hospital, Aalborg - Denmark

Introduction: Vitamin E diffusion into highly cross-linked polyethylene (VEPE) is a method for enhancing long-term oxidative stability of hip arthroplasty liners. Early clinical outcome is important to document that there are no detrimental effects of new developments.
Objectives: The purpose of this study was to evaluate *in vivo* wear properties of VEPE and the stability of a porous-titanium coated acetabular cup using radiostereometric analysis (RSA).
Methods: A total of 144 patients were recruited into a prospective 5-year RSA study at 2 centres. All patients received porous-titanium coated cups and either VEPE or non-vitamin E medium cross-linked liners (XLPE). Cobalt-chrome or ceramic femoral heads were used, 32 mm or 36 mm. At Centre 1 the acetabulum was under reamed by 1 mm and at Centre 2 it was reamed size-to-size.
Results: There was no statistically significant difference (p = 0.203) in femoral head penetration into the VEPE liners at 3 years comparing the 32 mm metal heads (-0.002 ± 0.02mm) with the 32 mm ceramic heads (-0.04 ± 0.06 mm). There was no difference (p = 0.087) in head penetration into VEPE liners at Centre 1 compared with XLPE liners at Centre 2 (0.02 ± 0.05 mm); however there was statistically significant less wear in VEPE than XLPE liners at 3 years at Centre 2 (p = 0.017).
One year median proximal cup migration at Centre 1 (0.14 ± 0.03 mm) was significant lower than at Centre 2 (0.38 ± 0.06 mm) (p = 0.001). Median cup migration at Centre 1 remained stable at 3 years (0.15 ± 0.05 mm); however Centre 2 showed significant continual cup-migration at 3 years (0.45 ± 0.09 mm) (p≤0.002).
Discussion: This study provides the first multicentre *in vivo* wear measurement of VEPE liners using RSA. The 3 year VEPE results indicate low liner penetration with no significant difference between centres. Despite a statistically significant difference at Centre 2 between patients with VEPE and XLPE liners at 3 years the penetration measured is not clinically significant. The 3-year follow-up shows a low amount of early cup-movement.

THREE-YEAR FOLLOW-UP OF A LONG-TERM REGISTRY-BASED MULTICENTRE STUDY ON VITAMIN E DIFFUSED POLYETHYLENE IN TOTAL HIP REPLACEMENT

Henrik Malchau[1], Nanna Sillesen[2], Meridith Greene[1], Audrey Nebergall[1], James Huddleston[3], Roger Emerson[4], Eduardo Garcia-Cimbrelo[5], Peter Gebuhr[2], Anders Troelsen[2]
[1]Harris Orthopaedic Laboratory, Massachusetts General Hospital, Harvard University, Boston - USA; [2]Clinical Orthopaedic Research Hvidovre, Department of Orthopaedics, Copenhagen University Hospital Hvidovre, Hvidovre - Denmark; [3]Department of Orthopaedic Surgery, Stanford University Medical Center, Stanford California - USA; [4]Texas Center of Joint Replacement, Plano Texas - USA; [5]Department of Orthopaedics, Hospital La Paz, Madrid - Spain

Introduction: Preclinical studies of vitamin E diffused highly cross-linked polyethylene (VEPE) have shown improved fatigue strength and enhanced mechanical material properties that are less prone to wear because of the antioxidative properties of the vitamin E.
Objectives: To document both early and long-term clinical outcome of VEPE in order to ensure that there are no detrimental effects of the new developments and to evaluate the materials performances from clinical use.
Methods: A total of 977 patients from 17 centres in USA and Europe are enrolled into a prospective 10-year outcome study. Patients received either Porous Titanium Coated or Porous Plasma Sprayed acetabular shells with either VEPE liners or medium cross-linked (XLPE) liners. At each follow-up, 3 radiographs were obtained, 5 PROMs were completed (Harris Hip Score, case mix indicator, UCLA, SF-36, EQ-5D). Radiographs were measured for cup and stem position, as well as femoral head penetration into the liner. Postoperative complications and revisions were also collected.
Results: Mean age at surgery was 62 ± 9 years. At 3-year follow-up there were 14 dislocations in 10 patients and 13 revisions (4 periprosthetic fracture, 1 sepsis, 6 instability, and 2 implant mismatch at surgery). Eleven patients died due to causes unrelated to the operation. Wear analysis of AP pelvis films with Martell method from post-op to 3 years showed a penetration rate at 0.037 mm/year for XLPE and a penetration rate of 0.038 mm/year for VEPE with no significant difference between them (p = 0.95). Improvement was seen in all PROMs pre-op to 3 years postop (p<0.0001).
Conclusions: Early follow-up of VEPE liners provide encouraging results with few intra- and postoperative complications. PROMs indicate improvement after THA in functionality and quality of life across the centres. We have not observed any early adverse effects from diffusing the liners with vitamin E.

Infection

THE NATIONAL INCIDENCE OF PERIPROSTHETIC JOINT INFECTION AFTER PRIMARY TOTAL HIP REPLACEMENT IN SWEDEN - A NEW METHOD OF SURVEILLANCE

Viktor Lindgren[1], Per Wretenberg[1], Johan Kärrholm[2], Göran Garellick[3], Max Gordon[4]
[1]Department of Orthopaedic Surgery, Karolinska University Hospital, Stockholm - Sweden; [2]Sahlgrenska University Hospital, Gothenburg - Sweden; [3]Swedish Hip Arthroplasty Register, Gothenburg - Sweden; [4]Danderyd Hospital, Stockholm - Sweden

Introduction and purpose: In Sweden a national initiative called PRISS (Prosthesis Related Infections Should be Stopped) was introduced in 2008 in order to reduce the incidence of Periprosthetic Joint Infection (PJI) following total hip and knee arthroplasty. The purpose of this study was to estimate the incidence of deep PJI after primary Total Hip Arthroplasty (THA) in Sweden before the PRISS initiative and to validate the Swedish Hip Arthroplasty Register (SHAR) regarding reoperations due to infection.
Methods: All patients registered for a THA in the SHAR between July 01, 2005 and December 31, 2008 were selected for the study (45,531 patients with 49,219 THAs) and were matched with the Swedish Prescribed Drug Register. All patients that had received a minimum of 4 weeks of continuous outpatient antibiotic treatment within 2 years after their primary THA (1,989 patients, with 2,219 THAs) were selected for a medical records review to determine if they had suffered from a deep PJI. The reoperations discovered in the study were then compared with the data obtained from the reoperation database in the SHAR.
Results: The cumulative incidence of PJI within 2 years after primary THA was 0.9% (n = 443) and 405 of these had been re-operated. The incidence rate for the first 3 months was 5 deep PJIs per 10,000 THA-weeks and thereafter 0.3 deep PJIs per 10,000 THA-weeks. 1.3% of the total cohort had been re-operated due to infection within 2 years after the primary THA and 66% of these were reported to the SHAR.
Conclusions: This study describes a new way of national postoperative infection surveillance. The incidence is similar to previous international reports and is a prerequisite to evaluate the PRISS-project. The proportion of registered reoperations in the SHAR was lower than expected.

DOES AN INTRA-ARTICULAR STEROID INJECTION WITHIN 6 MONTHS OF SURGERY INCREASE RISK OF DEEP-SEATED INFECTION IN HIP ARTHROPLASTY PATIENTS?

Alexander Glover, Kumar Gunasekaran
Department of Orthopaedics, Royal Liverpool University and Broadgreen Hospital Trust, Liverpool - United Kingdom

Introduction: Intra-articular steroid injections (ISI) are commonly used for managing osteoarthritis - therapeutic or diagnostic. Recent studies have shown possible increase in deep infection in total hip arthroplasty (THA) patients who had a preoperative ISI. Given the small numbers, a significant link is yet to be established.
Objectives: Aim of this study was to assess the infection rates in patients who undergo primary THA and have had at least 1 preoperative ISI.
Methods: We identified 126 patients who had undergone 1 or more ISI prior to primary THA between November 26, 2012 and June 05, 2008. Data collected included: demographic information, co-morbidities, American Society of Anesthetists (ASA) grade, type of anaesthesia, surgeon grade, surgical time, wound complications, postoperative infection and revision for any reason.
Multivariate analysis was performed to identify any correlation between the data collected and infection rates and compared with infection rates in THA patients without preoperative ISI during the same period.

Results: The mean age of the patients was 70 years of age. Mean interval between injection and surgery of 9.61 months (range 2 to 42). All the patients had the same type of steroid injection. Mean follow-up after THA was 30.2 months. There were 2 cases (1.55%) of superficial infection requiring wound washout and secondary closure (mean 8 months). Three deep infections (2.38%) at 2, 5 and 9 months, underwent staged revision THA. There were no significant correlation between the data collected and infection. Infection rate in primary THA without ISI was 0.8% during the same period.
Conclusions: Deep infection rate following primary THA in patients with prior ISI was significantly higher than the ones without prior ISI. These infections manifest within a year of primary THA and often in the first 6 months. Hence, we recommend differing primary THA at least for 6 months following administration ISI into the hip joint.

BACTERIAL CONTAMINATION OF DIATHERMY TIPS USED DURING ORTHOPAEDIC PROCEDURES

Peter Coffey, Ali Abdulkarim, Andrew Moriarty, Eoin Sheehan
Department of Trauma and Orthopaedics, Tullamore - Ireland

Introduction: The role of diathermy in orthopaedic surgical practice has increased since its introduction. It is widely used for underlying tissue dissection, cutting, and haemostasis. Previous studies have compared electrosurgical and scalpel incisions in terms of wound infection, wound-related pain, and blood loss. There are well documented hazards associated with diathermy use including burns injury, electrocution, hypoxic stress, inhalation of diathermy plume, and gene mutation. No single study to date has focused on the potential for diathermy tips to cause wound contamination and infection. We sought to identify whether diathermy tips could be possible sources of infection in orthopaedic procedures.
Objectives: To determine the prevalence of bacterial contamination of diathermy tips during orthopaedic surgery and to assess any correlation with surgical site infections.
Methods: From July 2013 to September 2013, the diathermy tips from 86 consecutive orthopaedic procedures using diathermy were cultured using direct and enriched media. None of the diathermy tips were used for the skin incision. All patients underwent an orthopaedic procedure for a non-infected condition. For each procedure an unused control diathermy tip was placed on the instrument table at the beginning of the procedure and processed similarly. All patients were followed for any postoperative complications.
Results: A total of 108 diathermy tips from 86 orthopaedic procedures were cultured. None of the tips cultured directly on blood agar demonstrated bacterial growth. Following enrichment culture, 6 (5.6%) of the procedure diathermy tips and 1 (0.92%) of the control tips demonstrated bacterial growth. Coagulase-negative staphylococci (83.3%) and proprionibacterium (16.7%) were cultured from the tips. One of the patients who had bacterial growth from the diathermy tip developed a superficial surgical site infection.
Conclusions: Surgical site infections contribute substantially to orthopaedic surgical morbidity and mortality each year. The prevention of these infections encompasses careful operative technique, preoperative antibiotics, and a number of important measures to minimise the risk of bacterial contamination posed by operative staff, the operating theatre environment, and the patient's endogenous skin flora. Identifying potential bacterial sources is an important component of surgery. The 2 bacteria cultured in our study (coagulase-negative staphylococci and proprionibacterium) are both well known major culprits in orthopaedic infections, responsible for up to 70% of early and late peri-prosthetic infections. Our study suggests diathermy tips and the tissue coagulated by its use may not be as sterile as previously thought. There may be benefit in changing the diathermy tips during orthopaedic procedures as they may represent a possible source of bacterial contamination.

PERCUTANEOUS JOINT ASPIRATION IS NOT RELIABLE FOR THE EXCLUSION OF PERSISTING INFECTION IN TWO-STAGE HIP EXCHANGE

Tobias Winkler, Viktor Janz, Bernd Preininger, Andrej Trampuz, Carsten Perka
Centre for Muskuloskeletal Surgery, Charité - Universitaetsmedizin Berlin, Berlin - Germany

Introduction: Percutaneous joint aspiration (PJA) is used in many institutions as a standard in the diagnostic algorithm in two-stage exchange procedures of periprosthetic infections of the hip (PPIH). In this retrospective cohort study we aimed at the question of the validity of this diagnostic tool.
Methods: We analysed the data of 51 consecutive patients with PPIH who underwent a two-stage-exchange of the hip with a long interval (>6 weeks) and had a negative PJA before reimplantation. All patients had a Girdlestone hip in the interval, no spacers were used. The microbiological results of the Girdlestone-PJA were compared to the results of the microbiological and histological analyses of intraoperative specimens from the time of reimplantation. Antibiotic treatment was stopped 2 weeks before PJA.
Results: Within 2 years we could include 51 patients (25 male, 26 female) with a mean age of 70.4 ± 10.7 years. Using only the microbiological results of intraoperative specimens as a reference, the PJA of 11 patients revealed to be false negative yielding a negative predictive value of 78.4%. Determination of a persisting infection by an either positive microbiology or a positive histology at the time of reimplantation resulted in a negative predictive value of PJA of only 58.8%.
Conclusions: Percutaneous joint aspiration is a valuable tool for establishing the primary diagnosis of PPIH. However, due to its low negative predictive value for the determination of a persisting infection we recommend to reconsider its role in the diagnostic algorithms for two-stage exchange as we did in our institution based on these results.

CULTIVATION OF SONICATE FLUID IN BLOOD CULTURE BOTTLES IS SUPERIOR TO CONVENTIONAL AGAR PLATE CULTURES

Viktor Janz, Georgi Wassilew, Michael Müller, Carsten Perka
[1]Orthopaedic Department, Centre for Musculoskeletal Surgery, Charité - Universitätsmedizin Berlin, Berlin - Germany

Introduction: A timely isolation of the causative bacterial species is of paramount importance in the treatment of periprosthetic joint infections. Sonication of the explanted endoprosthesis and the microbiological culture of sonicate fluid (SF) has been proven to increase the rate of bacterial isolations in comparison to conventional microbiological methods. The cultivation of aspired synovial fluid in blood culture bottles (BCB) has been shown to yield a higher rate of bacterial isolations than cultivation on conventional agar plates (AP).
Objectives: The primary aim of this study was to investigate whether the inoculation of BCB with SF leads to a higher rate of bacterial isolations than culture on AP. Secondly, we wanted to investigate whether the utilisation of BCB leads to an earlier identification of the causative bacterial species. To our knowledge this is the first study to investigate the effects of BCB use on SF.
Methods: We performed a retrospective analysis comparing the results of the 2 different culture methods. To detect slow growing species all microbiological cultures, regardless of the culture method, were incubated for 14 days.
Results: Of the 206 patients included in our study 112 showed a positive bacterial isolation. Of these, 61 showed bacterial isolations through conventional microbiological methods and 101 through culture of SF in BCB. The rate of positive bacterial isolations was improved through the use of BCB over conventional AP from 16% to 22% for synovial cultures and from 25% to 44% for SF. The cultivation of SF in BCB showed a positive bacterial isolations an average of 1.3 days before the conventional AP.
Conclusions: When SF is cultured in BCB it leads to an improved rate of positive bacterial isolations and quicker bacterial growth than the culture on conventional AP.

CULTURE OF SAMPLES OBTAINED BY SONICATION VERSUS CONVENTIONAL CULTURE FOR PROSTHETIC JOINT INFECTION DIAGNOSIS

Nicolás Cachero[1], J.J. Ballester[2], J. Marante[3], I. Andrés[1], P. Casanova[1], A. Romero[2] A. Zapata[3], G. Jimenez[1], J.A. Andrés[1], F. Brun[1]
[1]Department of Orthopaedics, University Hospital Puerta del Mar, Cádiz - Spain; [2]Department Orthopaedics, University Hospital Puerto Real, Puerto Real - Spain; [3]Department Orthopaedics, SAS Hospital Jerez, Jerez de la Fra - Spain

Introduction: Identification of infectious agents as a causal factor in periprosthetic joint infection (PJI) is of paramount importance for a successful treatment. Microorganisms are typically present in a biofilm on the surface of the prosthesis, which impede the standard culture medium.
Objetives: We performed a prospective trial among patients undergoing hip revision, comparing culture of samples obtained by sonication of explanted hip prostheses to dislodge adherent bacteria from the prosthesis with conventional culture of periprosthetic tissue for the microbiologic diagnosis of prosthetic-joint infection.
Methods: We prospectively followed consecutive patients undergoing hip revision for suspected infection or aseptic loosening between Jul-Dec, 2013. Specimens were processed routinely with Gram's staining, fluid culture (aerobic and anaerobic) thioglycollate and incubated for 10-15 days. Sonication of the implant was performed at 40 +/- 2 kHz low frequency.

Results: Ten patients were included with a median age of 70 (65.5 to 79.0) years. Six cases were removed for suspected aseptic loosening (AL) and 4 of them due to confirmed infection. In the 6 patients with suspected AL, cultures obtained before surgery and the surgical specimens were all negative. In 2 of these patients (33.3%), microbiological growth was detected in sonicated-fluid culture (Propionibacterium acnes and S. epidermidis). In cases of PJI, all early infection were positive for S. aureus and late for S. hominis. In 2 cases treated with antibiotics, no growth was obtained with conventional tissue samples and had positive sonicated-fluid cultures.
Conclusions: Culture of samples obtained by sonication was more sensitive than conventional periprosthetic tissue culture for the microbiologic diagnosis of prosthetic hip infection, especially for the recovery of low virulence and slow-growing microorganisms and patients who had received antimicrobial therapy before surgery.

PROSTHETIC JOINT INFECTIONS AND BEARINGS

Rihard Trebše, Vesna Levašič, Simon Kovač
Valdoltra Orthopaedic Hospital, Ankaran - Slovenia

Introduction: Total hip arthroplasty (THA) articulating surfaces are constituted of a metal head articulating with conventional polyethylene (M/P), irradiated polyethylene (M/XLP) or metal (M/M), or ceramic head articulating with polyethylene (C/P), irradiated polyethylene (C/XLP), or ceramic (C/C). We hypothesise that bearing type influences the incidence of prosthetic joint infection (PJI).
Objectives: In our study we investigated if the incidence of PJI differs according the bearing type
Methods: In Valdoltra Arthroplasty Registry we identified all patients with THA implanted between January 01, 2002 and December 31,2012. There were 4,770 M/P, 2,813 M/XLP, 72 M/M, 512 C/P 376 C/XLP, and 1,323 C/C bearings. We compared the PJI incidences with Chi-Squared test. Forstatistical analysis we excluded the M/M group because it was too small in comparison to other groups. We also compared the group with the lowest PJI incidence - C/XLP with other 4 groups using the two-tailed *t*-test with a = 0.05.
Results: The incidence of PJI were as follows (hips): in M/P (30) 0.6%, in M/XLP (29) 1.03%, in C/P (3) 0.59% in C/XLP (0) 0.00%, and in C/C group (6) 0.45%. The Chi-Squared test for the remaining 5 groups (4 degrees of freedom) showed significant differences between groups. The differences between groups C/XLP vs C/C (p = 0.1099) and C/XLP vs C/P (p = 0.0827) were not significant, whereas the differences between C/XLP vs M/P (p = 0.0181) and C/XLP vs M/XLP (p = 0.0246) were Significant.
Conclusions: Our results suggest that THA with bearing couples with no metal component are less prone to PJI. In these bearings metal ion release is nil from the bearing and minimal from the taper junction. We assume that there are more PJI than generally acknowledged but periprosthetic host defence mechanisms keep many of them asymptomatic. Excessive metal ion load weakens local immune capabilities and consequently some of the asymptomatic infections become clinically manifested.

WITHDRAWN

HIGH SUCCESS RATE FOR ROUTINE ONE-STAGE EXCHANGE FOR INFECTED THR

Régis Lengert
Centre de Chirurgie Orthopédique et de la Main, Strasbourg - France

Introduction: Infection after total hip arthroplasty is a devastating complication. The treatment often involves removal of the implants with extensive debridement. A prosthetic reimplantation may be performed either during the same procedure than removal (one stage exchange), or in a second stage after weeks or months of waiting time without an implant. If the two stage procedure remains currently the gold standard for infection control, one stage procedure may be as efficient and more cost-effective. The respective indication of both procedures is not clearly defined in the literature.
Objectives: We wanted to evaluate the results of a routine one stage procedure, without selection criteria, on the success rate after infected prosthesis exchange in a retrospective analysis of prospectively collected data.
Methods: 65 cases of infected total hip arthroplasty were consecutively treated at our department between 2007 and 2010 by a routine one-stage exchange. No two-stage procedure was performed during the time of the study. There were 41 men and 24 women, with a mean age of 73 years. All patients were operated on by prosthesis removal, radical debridement and immediate prosthesis reimplantation. An adapted antibiotic treatment was given for 6 to 12 weeks. All patients were followed for a minimal period of 2 years or until death or recurrence of infection.
Results: Mean follow-up time was 37 months. 54 patients (83%) were considered free of infection at the last follow-up. The survival rate of being free of infection at 5 years was 83%. Among the 11 failures, 4 cases were considered a persistence of the index infection, 5 were considered as cured for the index infection but suffering from a new infection due to another pathogen, and 2 cases were inconclusive. Hip function was satisfactory, with a mean inverted Oxford Hip score of 34 points. No significant prognostic factor was detected. Specially, the responsible pathogen, the presence of a fistula and a prosthetic loosening prior to the prosthesis exchange did not influence the failure rate.
Conclusions: The routine one stage exchange procedure allowed a high rate of infection control and a good function of the reconstructed hip. The failure rate did not seem to be higher than the previously reported rates for selected one stage exchange procedure or two stage procedure. The routine one stage procedure may be more cost effective. We suggest using a routine one stage procedure for the treatment of chronically infected total hip arthroplasty.

SINGLE VERSUS STAGED REVISION FOR PATIENTS WITH CONTAINED PERI PROSTHETIC INFECTION OF THE HIP

Ayman Ebied[1], Ahmed Ali Ebied[2], Sameh Marei[1]
[1]Arthroplasty Unit, Orthopaedic Department, Menoufia University Hospital, Shebin El Kom - Egypt; [2]Orthopaedic Department, Menoufia University Hospital, Shebin El Kom - Egypt

Introduction: Evidence is still lacking when comparing single versus two-stage revision total hip replacement (THR) for periprosthetic infection.
Objectives: 1) To prospectively compare the results of single versus two stage revision THR in patients with periprosthetic infection. 2) To evaluate the results of antibiotic loaded fresh frozen cancellous graft impacted in the acetabulum defects.
Methods: A total of 52 patients with infected hip prosthesis were revised using either single or staged revision protocol. Preoperative aspiration allowed identification of the infecting organism in 33 patients who had single stage revision. In 19 patients identification of the organism was not possible preoperatively and therefore two-stage revision was performed. Impaction of antibiotic loaded

bone graft was performed in all acetabular defects. Cemented all poly cups and Wagner cementless stems (Zimmer, Warsaw, USA) were implanted in all cases. Patients were prospectively evaluated using the modified Harris Hip Score (HHS) in addition to radiologic assessment.
Results: At an average 4 years of follow-up (range 1-6) no difference was found between the single and two staged revision protocol in terms of controlling infection, 96% in the former and 97% in the latter. Acetabulum bone deficiency had progressed at least one grade up in all cases which received staged revision. Patients who had single-stage revision achieved higher HHS 85 5 than patients from the staged group 76 4 though this difference was not significant.
Conclusions: Single-stage revision THR for infection provides a similar rate of success to a staged protocol. Choosing hips with a contained infection process, i.e. without a draining sinus, preoperative identification of the organism, and impaction of antibiotic loaded fresh frozen allograft are important factors that contribute to the success of this procedure.

TWO-STAGE TREATMENT OF INFECTED TOTAL HIP ARTHROPLASTY WITH AN ARTICULATING CEMENT SPACER WHILE RETAINING A WELL-FIXED CEMENTLESS STEM

Takuya Otani[1], Yutaka Ueno[1], Hideki Fujii[1], Yasuhiko Kawaguchi[1], Tetsuo Hayama[1], Hiroshi Murakami[1], Yoshiharu Nakajima[1], Hajime Sugiyama[2], Toshiomi Abe[1], Keishi Marumo[1]
[1]Department of Orthopaedic Surgery, The Jikei University School of Medicine, Tokyo - Japan; [2]Department of Orthopaedic Surgery, Kanagawa Rehabilitation Hospital, Kanagawa - Japan

Introduction: A two-stage revision of infected total hip arthroplasty (THA) with an antibiotic-loaded articulating cement spacer (ACS) has been reported to provide both infection control and preservation of joint function. However, removal of a well-fixed cementless stem frequently causes significant damage to the femur making ACS placement difficult. From 2004 we have treated infected THAs with well-fixed stems retained in place and applied ACSs onto the acetabular sides.
Objectives: To evaluate clinical outcomes of a two-stage treatment for infected THA while retaining well-fixed stems; evaluations focused on infection control and joint function.
Methods: Since 2004, 6 cases of chronic infection after cementless THA with well-fixed stem were treated and in all cases stems were retained. The first stage procedure consisted of removal of the acetabular implants and ACS placement in the acetabular space. A hemispherical dent was made on the ACS surface and the femoral head was reduced. In the second stage, debridement was repeated and acetabular reconstruction was performed. At the final follow-up, success of infection control, complications, and hip function were assessed. The average follow-up period was 5 (2-9) years.
Results: The average interval between the first and second procedure was 3.3 months and during this period patients continued ROM exercises and PWB gait with crutches. Infection was successfully controlled without recurrence in all patients. The average function score at the final follow-up was 79/100. Dislocation was found in one patient after the second revision TAH, but no ACS dislocation was observed.
Conclusions: Our results indicate that infected cementless THA can be successfully treated even when well-fixed femoral stems are retained, although detailed method and indications need to be discussed further.

Arthroscopy

MOLECULAR CHARACTERISTIC OF THE TISSUES FROM HIPS WITH FEMOROACETABULAR IMPINGEMENT

Takaaki Fujishiro[1], Shigo Hashimoto[1], Nobuaki Chinzei[1], Shinya Hayashi[1], Noriyuki Kanzaki[1], Masahisa Hatakeyama[2], Shuhei Sakata[1], Shinsuke Kihara[1], Soshi Uchida[2], Masahiro Kurosaka[1]
[1]Department of Orthopaedic Surgery, Kobe University Graduate School of Medicine, Kobe - Japan; [2]Department of Orthopaedic Surgery, Wakamatsu hospital for University of Occupational and Environmental Health, Kitakyusyu - Japan

Introduction: Femoroacetabular impingement (FAI) has revealed to be one of the main causes of hip pain and may lead to secondary osteoarthritis (OA). However, little is known about the molecular relationships among the tissues structuring the hip with FAI.
Objective: The aim of this study is to analyse the expression of inflammatory cytokine, matrix-catabolic, and matrix-anabolic genes in tissues from FAI and OA, and to confirm the development of secondary OA in FAI molecular biologically.
Methods: Synovium, labrum, and articular cartilage were obtained from 15 FAI patients during hip arthroscopic surgery and 15 OA patients with THA. Quantitative RT-PCR was carried out to compare the relative gene expression. For the index of inflammation, the mRNA expression of IL-1β and IL-8 genes were examined in all samples. For the index of matrix-catabolism, the mRNA expression of MMP-3 in synovium and labrum, and ADAMTS-4 and MMP-13 in cartilage were examined. For the index of matrix-anabolism, collagen type alpha (COL1A1) in labrum and collagen type II alpha (COL2A1) and Aggrican in cartilage were examined.
Results: Both in synovium and laburm, the mRNA expression of IL-1β, IL-8, and MMP-3 was higher in samples from OA compared with FAI hips. And the mRNA expression of COL1A1 was also higher in labrum from OA compared with FAI. On the contrary, the mRNA expression of inflammatory cytokines, ADAMTS-4, and MMP-13 was higher in cartilage samples from FAI compared with OA, though, the mRNA expression of COL2A1 and Aggrican was higher in OA compared with FAI. The mRNA expressions of inflammatory cytokines in FAI cartilage was highest, however, there were no significant differences of the expressions in OA.
Conclusions: Our results indicate that articular cartilage may be the main focus of inflammation and degeneration in FAI. The metabolically hyperactivities in articular cartilage may also support the idea that FAI is the outrider disease to hip OA.

ARTHROSCOPIC OSTEOCHONDROPLASTY FOR CAM-TYPE FEMORO-ACETABULAR IMPINGEMENT: STANDARD CAPSULECTOMY VERSUS CAPSULE-SPARING TECHNIQUE

Luca Pierannunzii, Arturo Guarino
Gaetano Pini Orthopaedic Institute, Milan - Italy

Introduction: Hip arthroscopy is currently considered an effective and safe procedure to treat cam-type femoro-acetabular impingement (FAI). Several techniques were developed to address the femoral head-neck junction (capsulectomy, capsulotomy - repaired or not - and complete capsule preservation), but no significant evidence is provided so far to support the surgeons' choice.
Objectives: Two extreme options of capsule management for femoral osteochondroplasty are compared: "central compartment first" technique with capsulectomy versus "peripheral compartment first" technique with capsule preservation.
Methods: A total of 30 cam-type FAI cases were prospectively evaluated: 15 cases underwent anterolateral capsulectomy with "central compartment first" approach and were included in group A, while 15 cases had the capsule preserved with "peripheral compartment first" approach and mild capsular thinning and were included in group B. Exclusion criteria were: Tönnis grade of osteoarthritis >2 and coexisting pincer deformity (mixed FAI). Operative and traction time, complications, VAS and mHHS were compared both at discharge and at following visits for a minimum 6-month follow-up.
Results: Overall operative times were similar, but traction time was significantly shorter in group B (74 vs 51 minutes on average, $p = 0.029$). Pain (VAS) 48 hours after surgery was significantly lower in group B (49 vs 37 mm, $p = 0.044$). No significant differences were demonstrated for later VAS measurements nor for 1-month and 6-month mHHS. One patient of group A had a transient sciatic nerve sensory damage and another one had a femoral head scuffing injury, while no complications occurred in group B. Postoperative x-rays demonstrated undercorrection in 2 cases of group A and 3 cases of group B.
Conclusions: The 6-month scores did not show significant differences between the 2 groups, however patients who had the capsule preserved (group B) experienced less postoperative pain, and the shortened traction time in this group might justify the lower incidence of traction-related complications. Although both sample size and follow-up are limited, this is the first comparative study available so far.

DOES PRIMARY HIP ARTHROSCOPY RESULT IN IMPROVED CLINICAL OUTCOMES? A 2-YEAR CLINICAL FOLLOW-UP ON A MIXED GROUP OF 738 CONSECUTIVE PRIMARY HIP ARTHROSCOPIES PERFORMED AT A HIGH-VOLUME REFERRAL CENTRE

Timothy Jackson[1], Asheesh Gupta[2], Kevin Dunne[2], John Redmond[2], Christine Stake[2], Benjamin Domb[3]
[1]Congress Medical Associates, Pasadena - USA; [2]American Hip Institute, Westmont - USA; [3]Hinsdale Orthopaedics & American Hip Institute, Westmont - USA

Background: The purpose of this study was to evaluate clinical outcomes and patient satisfaction following primary hip arthroscopy for a single surgeon at a high-volume referral centre, with a minimum 2-year follow-up.

Methods: During the study period, April 2008 to October 2011, data were collected on all patients undergoing primary hip arthroscopy. All patients were assessed pre- and postoperatively with 4 patient-reported outcome (PRO) measures: the modified Harris Hip Score (mHHS), Non-Arthritic Hip Score (NAHS), Hip Outcome Score-Activities of Daily Living (HOS-ADL), and Hip Outcome Score-Sport Specific Subscales (HOS-SSS). Patient satisfaction was measured on a scale from 0 to 10. The number of patients who underwent revision arthroscopy, total hip arthroplasty (THA), or a resurfacing procedure during the study period is also reported.
Results: A total of 754 patients underwent primary hip arthroscopy during the study period and 611 (81%) patients had completed 2-year follow-up and were included in our study. All scores demonstrated statistically significant improvement ($p<.001$). Overall patient satisfaction was 7.86. A total of 47 (7.7%) patients required revision surgery and 56 (9.2%) patients progressed to either THA or hip resurfacing during the study period.
Conclusions: Primary hip arthroscopy resulted in improved clinical outcomes and high satisfaction at minimum 2-year follow-up.

JOINT PRESERVATION AFTER HIP ARTHROSCOPY IN PATIENTS WITH FAI. PROSPECTIVE ANALYSIS WITH A MINIMUN FOLLOW-UP OF 5 YEARS

Fernando Comba, Ali Julian, Gerardo Zanotti, Martin Buttaro, Francisco Piccaluga
Hip Surgery Unit, Institute of Orthopaedics "Carlos E. Ottolenghi", Hospital Italiano de Buenos Aires, Buenos Aires - Argentina

Purpose of this work is to evaluate the clinical results and the rate of joint preservation in a series of patients with femoroacetabular impingement (FAI) treated with hip arthroscopy at a minimum follow-up of 5 years. The predictive factors for total hip arthroplasty (THA) requirement were analysed.
Between February 2008 and February 2009, 42 consecutive patients treated with a hip arthroscopy due to FAI syndrome were included. There were 15 women and 27 men with an average age of 38 years (range 23 to 56). The surgery involved joint damage stabilisation (labral tears and/or condrolabral injuries) and correction of associated bony deformities (CAM and/or PINCER lesions). A prospective follow-up was made with no patient lost. We specifically addressed the need for THA. Predictive factors for THA were also analysed.
At a minimum follow-up of 5 years the rate joint preservation was 88.1% (CI95% 74.54%-95.27%). The probability of evolving to a THA in patients with radiographic preoperative Tönnis grades 0 and I was of 0% (CI95% 0%-14.76%). The probability of evolving to a THA in patients with preoperative Tönnis grades II and III was 33, 3% (CI 95% 14.96%-58.5%). Statistical significant difference was present between both groups ($p = 0.003$). Patients with an age of 45 years or more at the time of hip arthroscopy were at significant risk to evolve to THA ($p = 0.005$).
Hip arthroscopy for the treatment of patients with FAI syndrome presents favourable results regarding joint preservation at a minimum follow-up of 5 years. Patients with advanced preoperative radiographic signs of osteoarthritis and older than 45 years at the time of surgery have greater risk for requiring THA.

ARTHROSCOPIC TREATMENT OF FEMORO ACETABULAR IMPINGEMENT: 6 TO 8 YEARS FOLLOW-UP

Domenico Potestio, Antonio Bertino, Nicola Santori
Rome American Hospital, Rome - Italy

Our study evaluates mid-term results of arthroscopic treatment of FAI and investigates the relationship between radiographic correction and clinical outcomes. We evaluate the results of our first 77 consecutive hip arthroscopic osteoplasty for FAI performed between January 2006 and December 2008. Only Tönnis 0/1 patients were included. Mean follow-up was 7.1 yrs. Mean age was 33 years. Pre-op evaluation was based on A-P and axial x-rays, MRI, clinical examination. Alpha angle was measured on the pre-op x-rays. Intra-op chondral lesions were classified according to Outerbridge classification. Patients were evaluated, pre-op and post-op, with mHHS and NAHS. Amount and quality of osteoplasty was assessed on conventional x-rays by 3 independent observers unaware of clinical outcome and classified in 3 groups: excellent, acceptable and poor. Dynamic intra-op testing of the correction achieved was always performed. MHHS was 73 in pre-op, 88 in post-op and 92 at last follow-up. NAHS was 73.5 in pre-op, 87 in post-op and 90.5 at last follow-up. Alpha angle was measured on the AP and axial view x-ray and was always improved after resection. Radiographic correction of FAI was judged excellent in 4 hips, acceptable in 38 hips and poor in 30. Evaluation of the MHHS and NAHS of these 3 groups was made and no direct relationship between clinical outcome and quality of the osteoplasty was found. We had 2 cases of pudendal transient neurapraxia which resolved in 8 and 6 weeks. No other major complications were detected. At the beginning of our learning curve we were frequently unable to achieve a satisfactory radiographic correction of FAI deformities. Based on this mid-term follow-up we can state that arthroscopic treatment of FAI in Tönnis 0/1 patients, is an effective procedure. In this series clinical advance appear independent from the quality of post-op radiographic correction. We also report that the results are directly related to the grade of cartilage damage.

CLINICAL OUTCOMES OF HIP ARTHROSCOPY WITH MICROFRACTURE: A MATCHED-PAIR CONTROLLED STUDY WITH MINIMUM 2-YEAR FOLLOW-UP

Benjamin Domb[1], Asheesh Gupta[2], John Redmond[2], Kevin Dunne[2], Christine Stake[2]
[1]Hinsdale Orthopaedics/American Hip Institute, Westmont - USA; [2]American Hip Institute, Westmont - USA

Background: The purpose of this study is to compare 2-year clinical outcomes of patients having microfracture to a matched control group not receiving microfracture.
Methods: During the study period, June 2008 and July 2011, data were collected on all patients treated with hip arthroscopy who underwent microfracture. A matched-pair group of patients who did not undergo microfracture was selected on a 1:2 ratio. Matching criteria were age within 5 years, sex, surgical procedures, and radiographic findings. All patients were assessed pre- and postoperatively with 4 patient-reported outcome (PRO) measures. Satisfaction was measured on a scale from 0 to 10.
Results: A total of 49 hips were included in the microfracture group and 98 in the non-microfracture group. There was no significant difference in PRO scores preoperatively between the groups. Both groups demonstrated significant postoperative improvement in all scores ($p<0.05$). There was no significant different in PRO scores postoperatively between the groups. Patient satisfaction was 6.9 for the microfracture group and 7.84 for the non-microfracture group ($p<0.05$).
Conclusions: Our study demonstrated patients receiving microfracture during hip arthroscopy did not show a statistically significant difference in PRO scores when compared to a matched-pair control group. Both groups demonstrated statistically significant postoperative improvement in all scores.

Complex Primary THA

TOTAL HIP REPLACEMENT IN HIV-POSITIVE PATIENTS

Simon Matthew Graham[1], James Cruickshank[1], Nicholas Lubega[2], William J. Harrison[1], Nyengo Mkandawire[3]
[1]Department of Orthopaedic Surgery, The Countess of Chester Hospital, Chester - United Kingdom; [2]Beit CURE International Hospital, Blantyre, Malawi, Blantyre - Malawi; [3]The Department of Surgery, College Of Medicine University of Malawi, Malawi, Blantyre - Malawi

Introduction: Enhancements in the treatment of patients infected by the human immunodeficiency virus (HIV) have improved their life expectancy. This has coincided with an increase in the number of joint-replacement surgeries performed on HIV-positive patients.
Objectives: The purpose of this study is to report the short-term follow-up, functional outcome, and incidence of early and late infection in a group of HIV-positive patients, with no haemophilia or history of intravenous drug use, following total hip replacement (THR).
Methods: All patients who were HIV positive and had ever undergone THR in Malawi were included in the study. A total of 29 patients, with a mean follow-up of 3 years 6 months (range 5 months to 8 years 2 months), underwent 43 THRs. There were 10 female and 19 male patients, with a mean age of 47 years 7 months (range 21 years to 59 years 5 months). There were no early (<6 weeks) or late complications (>6weeks) following their THR. The mean preoperative Harris Hip Score (HHS) was 27 (range 6-56) and the mean postoperative HHS was 86 (range 73-91), giving a mean improvement of 59 points ($p = <0.05$, Student's *t*-test). No revision procedures had been undertaken in any of the patients and no patients had any symptoms consistent with aseptic loosening.
Conclusions: The study demonstrates that it is safe to perform THRs in HIV-positive patients, with good short-term functional outcomes and no apparent increase in the risk of early or late infection.

BILATERAL TOTAL HIP ARTHROPLASTY IN PATIENTS WITH JUVENILE RHEUMATOID ARTHRITIS: SAFE AND COST EFFECTIVE

SM Javad Mortazavi
Joint Reconstruction Research Centre, Tehran University of Medical Sciences, Tehran - Iran

Hip joints are usually affected in patients with severe destructive juvenile rheumatoid arthritis (JRA). In patients with severe hip disease, total hip arthroplasty (THA) is the only viable option. Due to systemic nature of disease and bilateral involvement, bilateral THA could be helpful.
Methods: We performed simultaneous bilateral THA in 13 patients (26 hips) with JRA. The mean age of patients at the time of surgery was 18.4. There were 8 females and 5 males. All patients underwent THA through DA approach. Both acetabular and femoral components were cementless.
Results: At an average follow-up of 36 months, all components were stable both clinically and radiographically. The Harris Hip Score improved from 35 preoperatively to 85 postoperatively ($p<.001$). SF-36 showed significant improvement and WOMAC score decreased significantly ($p<0.05$). None of the patients but one used walking aid postoperatively. No patients required blood transfusion.
Conclusions: Bilateral THA through DA approach is a good option for patients with JRA and bilateral hip involvement. As far as we know, this is the first report on bilateral THA in patients with JRA through DA approach. This approach will expedite patients' rehabilitation and improvement in quality of life in trade of minimal risk taking.

TOTAL HIP ARTHROPLASTY AFTER FAILURE OF DYNAMIC HIP SCREW FIXATION IN INTERTROCHANTER FRACTURES

Dariush Savadkoohi, Babak Siavashi, Mersad Moosavi, Arash Aalirezaei
Tehran University of Medical Sciences, Sina Hospital, Tehran - Iran

Introduction: Intertrochanteric fracture is a challenging fracture with high rate of complications. One of the most common complications is nail cutout. It seems total hip arthroplasty is a reasonable treatment of this complication.
Purpose of study: To evaluate the risks and results of total hip arthroplasty after dynamic hip screw failure.
Materials and methods: A total of 64 patients (22 male, 42 female) with a mean age of 61 years were prospectively studied after undergoing total hip replacement (long stem, distal fixation) after failed treatment of intertrochanteric fractures.
Results: Intraoperative femoral fracture occurred in 8 patients and postoperative dislocation in 6 patients. At the last follow-up, we were able to review 52 patients with arthroplasties; the other 9 patients had died. The majority had good pain relief and marked functional improvement. A total of 44 patients had either no or mild pain and 46 patients were able to walk with or without support. Almost 78% of patients had either excellent or good clinical results based on Harris Hip Score. Heterotopic ossification was noted in 8 hips.
Conclusions: Total hip arthroplasty was found in this study to be an effective salvage procedure with minimal complications after failed treatment of intertrochanteric fracture in elderly patients.

EVALUATION OF THE RESULTS OF CALCAR REPLACEMENT HIP ARTHROPLASTY IN TREATMENT OF FAILED OR NONUNITED TROCHANTERIC FRACTURES

Ahmed Matthana, Mohamed Nabil, Mohamed Radwan
Department of Orthopaedics, Suez Canal University, Ismailia - Egypt

Introduction: Hip arthroplasty after failed treatment of an intertrochanteric fracture in elderly patients is a challenging procedure. The purpose of the study was to evaluate the results of calcar replacement hip arthroplasty after failed treatment of intertrochanteric hip fractures.
Objectives: To evaluate the results of using calcar replacement hip arthroplasty in treatment of failed or nonunited trochanteric fractures.
Methods: Between January 2009 and March 2012, a prospective study was undertaken including 25 patients (19 females and 6 males) having failure of trochanteric fractures fixation or non-union. All the patients had cemented calcar-replacement hip arthroplasty (13 of them had bipolar hemiarthroplasty and 12 patients had total hip arthroplasty). Harris Hip Score was used for assessment of the outcome.
Results: After 2 years of follow-up, our mean Harris Hip Score has showed an improvement of 64 points. We found statistically significant relation between the patient age ($p = 0.001$) and the outcome. No statistically significant relationship was found between the number of previous surgeries ($p = 0.57$) and type of the original fracture ($p = 0.13$) and the outcome.
Conclusions: Calcar replacement hip arthroplasty is an effective salvage procedure after failed treatment of an intertrochanteric fracture in an older patient.

TOTAL HIP ARTHROPLASTY IN PATIENTS LESS THEN 40 YEARS OLD WITH AVASCULAR NECROSIS A CONCISE 10- TO 23-YEAR FOLLOW-UP STUDY

Stijn Ghijselings, Pieter Berger, Jean-Pierre Simon
Department of Orthopaedics, Leuven University Hospital - Pellenberg, Leuven - Belgium

Introduction: Total hip arthroplasty (THA) is an effective treatment for end-stage degenerative disease. However, it has been associated with higher failure rates and less satisfactory clinical outcome in young patients with avascular necrosis.
Objectives: The purpose of this study was to evaluate: 1) the clinical and radiographic outcomes; and 2) implant survival in patients with a THA for avascular necrosis of the femoral head less then 40 years old.
Methods: Using the institutional database for THA, 34 THA in 26 patients with a minimum follow-up of 10 years were identified. The mean follow-up was 14.8 (10-23.3) years. The average age at the time surgery was 28.3 (17-40) years. All operations were done by a single surgeon using a posterolateral approach. Six cemented and 28 cementless acetabular components were used. At the femoral side one cementless and 33 cemented stems were used.
Results: The mean Charnley modified Merle d'Aubigné Postel score was 8.9 preoperatively and improved to 16.5 at last follow-up. Five revisions of acetabular components were performed on average 12.3 (7-17) years postoperatively. Reasons for revision were aseptic loosening in 4 and polyethylene wear in 1. In 1 hip both components were revised for late infection 7 years postoperatively. Kaplan-Meier analysis demonstrated an overall implant survival of 94% at 10 years, 87% at 15 years and 71% at 20 years postoperatively. With aseptic loosening as end-point survival was 100% at 23.3 years for the femoral stem and 81.2% for the acetabular component.
Conclusions: Excellent long-term clinical outcome was seen in THA for avascular necrosis of the femoral head in young patients regardless of the aetiopathology. Using a third-generation cementing technique no femoral loosening occurred at a mean follow-up of 14.8 years. This supports the use of a cemented polished tapered stem in these patients. No conclusions could be drawn regarding the choice of the acetabular component with the available data.

ACETABULAR REINFORCEMENT RING: ONLY A REVISION IMPLANT? A MINIMUM 20-YEAR FOLLOW-UP

Pascal Haefeli[1], Marc Attinger[1], Remy Flueckiger[2], Frank Klenke[1], Klaus Siebenrock[1]
[1]Department of Orthopaedic Surgery and Traumatology, Bern - Switzerland; [2]Department of Orthopaedic Surgery and Traumatology, Thun - Switzerland

Introduction: The acetabular reinforcement ring with a hook (ARRH) was originally designed for arthroplasty revision surgery and hips with acetabular deficiency. Due to its excellent results in such difficult cases the reinforcement ring was also applied for standard primary total hip arthroplasty. This study investigated the long-term results of the ARRH used in primary total hip arthroplasty after a minimum follow-up of 20 years.
Materials and methods: A total of 210 patients (241 hips) who underwent THA with an ARRH between April 1987 and December 1991 were evaluated after a mean follow-up of 23.7 years (range 21.1–26.1). Patient history, clinical status with hip scores (Merle d'Aubigne, Harris Hip Score) and routine x-rays were obtained. Direct Cox regression analysis was used to identify independent negative predictors for failure of the primary THA (revision surgery).
Results: Out of the 241 hips, 23 hips (9.5%) were lost to follow-up and 110 patients (124 hips, 51.5%) deceased without having revision surgery after a mean of 12.8 years (range 0.3 - 24.4 years) after surgery. A total of 83 patients (93 hips, 38.6%) were available for follow-up evaluation. The mean Merle d'Aubigne increased from 8 points to 15 points (P<0.001). The HHS reached a mean of 82.3 at the minimal 20-year follow-up. Eigteen out of the 241 hips (7.5%) were revised after a mean of 15.7 years (range 7.4–24.9). Survival probability of the cup at the 20-year follow-up was 0.96 (95% confidence interval, 0.93-0.99), survival probability for the whole implant was 0.91 (95% confidence interval, 0.86-0.96). In 14 hips (77.8%) the cause for revision was aseptic loosening whereas 2 hips (11.1%) required revision due to THA infection and 2 hips (11.1%) due to recurrent dislocation. Significant independent negative predictors were patient's age at surgery of less than 50 years, acetabular protrusion and an inclination of the cup of more than 45°.
Conclusions: The 20-year survivorship data, which are comparable to modern cementless acetabular implants support the ARRH's role in primary total hip arthroplasty, especially with difficult acetabular morphology. The ARRH benefits from minimal acetabular reaming and prevention of a high hip centre and cup medialisation. Our study outlines the importance of preventing a steep inclination of the ARRH for long-term survivorship.

TOTAL HIP REPLACEMENT IN PATIENTS WITH FEMORAL DYSPLASIA USING STRAIGTH CONICAL WAGNER-TYPE STEMS

Konstantinos Bargiotas, Ioannis Antoniou, Polykarpos Kiorpelidis, Michael Hantes, Konstantinos Malizos
General University Hospital of Larissa, Larissa - Greece

Introduction: Dysplasia of proximal femur may pose technical problems during total hip replacement (THA) due to distortion of the geometry and narrowing of femoral canal. We have used conical Wagner-type stems to address this problem.
Objectives: Aim of this study is the evaluation of Wagner-type stems and the presentation of its technical and surgical differences.
Methods: Between 1997 and 2008 we implanted 64 Wagner stems. Average age was 64 years. A total of 52 patients were operated for developmental dysplasia of the hip and 12 had previous osteotomy. All patients were prospectively evaluated radiographically and clinically at annual intervals. Functional outcome was assessed with Harris Hip Score and Oxford Score.
Results: Mean follow-up was 9 years (6-16). One stem was revised because of lesser trochanter fracture and two more patients were re-operated for open reduction. Survivorship rate was 98.5%. There were no progressive radiolucent lines. Stem migration was at an average 2 mm during the first 2 years and remained stable thereafter. There was no deep infection. After the second year a dense zone is evident in all Gruen zones with a width of 2-3 mm.
Conclusions: Short conical Wagner-type stems can offer a very good alternative in patients with dysplastic femurs. They allow control of the anteversion and they are able to get a good press-fit despite the metaphyseal/diaphyseal mismatch and the femoral bowing.

IS IT NECESSARY TO DO FEMORAL OSTEOTOMY FOR TOTAL HIP ARTHROPLASTY IN DYSPLASTIC HIP DISORDER CROWE TYPE 3 AND 4 OR ONLY SOFT TISSUE RELEASE IS ENOUGH?

Dariush Savadkoohi, Babak Siavashi, Arash Aalirezaei, Mersad Moosavi
Tehran University of Medical Sciences, Sina Hospital, Tehran - Iran

Introduction: For THA in DDH cases Crowe type 3 and 4, there is a challenge to restore hip centre of rotation. For this, there are 2 techniques: femoral osteotomy and soft tissue release.
Purpose of study: To evaluate the results and complications of soft tissue release in Crowe type 3 and 4 for inserting cup in true acetabulum.
Materials and methods: In 1 group osteotomy and in the other group soft tissue release were done. Harris Hip Score, neurovascular complications, leg length discrepancy, remaining hip contractions, non-union in osteotomy site, loosening, and dislocations, bleeding are variables.
Results: Group 1 (osteotomy) there was no sciatic nerve injury, average 1 cm LLD, 2 dislocations, 3 loosening and 3 flexion contractions 1 adduction contracture. HHS average was 92. There were one nonunion in osteotomy site. Group 2 (release) one peroneal nerve injury and one femoral nerve injury, average 1.5 cm LLD, no dislocations, no loosening and no contracture. HHS average was 95.
Discussion: There is no statistically difference between two groups about HHS, LLD, nerve injury, and dislocation but operation time and contractures were significantly better in release group (p = <0.001).

FAVOURABLE RESULTS OF PRIMARY TOTAL HIP ARTHROPLASTY WITH ACETABULAR IMPACTION BONE GRAFTING FOR LARGE SEGMENTAL BONE DEFECT OF DYSPLASTIC HIP

Toshiki Iwase, Tadashi Ito, Daigo Morita
Department of Orthopaedic Surgery, Hamamatsu Medical Centre, Hamamatsu - Japan

Introduction: The value of acetabular impaction bone grafting (IBG) for large segmental defect in primary total hip arthroplasty (THA) for dysplastic hip has not been well documented.
Objectives: The purpose of the study is to assess mid-term results after acetabular IBG in THA for dysplastic hip with large acetabular bone defect.
Methods: We aimed to place the cup at the true acetabulum. If the superior acetabular segmental defect existed medially beyond the centre of the femoral head, we performed IBG after containing the defect with metal mesh. We performed 37 THAs with IBG for severe dysplastic hip in 35 patients. The average age was 61 years (33-80), and the average follow-up period was 6.5 years (2.4-9.4). For clinical assessment, the Merle d'Aubigné and Postel hip score was used. For radiological assessment, the height and the horizontal location of the femoral head centre, the cup inclination angle, and the socket centre-edge (CE) angle, and cup loosening were analysed with postoperative radiographs. Kaplan-Meier survivorships were estimated with any type of re-operation and aseptic cup loosening as endpoints.
Results: The mean Merle d'Aubigné and Postel hip score improved from 10.4 points preoperatively to 16.2 points at the final follow-up. Acute infection occurred in 1 case and the patient was treated with second-stage revision. No other cases underwent subsequent surgical treatment in the follow-up period. On radiographic assessment, the mean height and the mean horizontal location of the femoral head centre was 22.4 mm and 30.0 mm, respectively. The mean socket CE angle was -13.2°. No case was classified as loosening. Survivorship with any type of re-operation as the endpoint was 96.3%, and with aseptic acetabular loosening as the endpoint was 100% at 8 years.
Conclusions: Acetabular IBG for severe dysplastic hip provides remarkable postoperative functional improvement and favourable radiographic results in the mid-term follow-up period.

CEMENTLESS ACETABULAR RECONSTRUCTION IN DYSPLASTIC HIPS: 5-YEAR RESULTS OF TOTAL HIP ARTHROPLASTY USING THE 15 DEGREES FACE CHANGING CUP

Manoj Puthiya Veettil, Anthony Ward, Evert Smith
Avon Orthopaedic Centre, Bristol - United Kingdom

Introduction: Total hip arthroplasty for secondary OA due to developmental dysplasia remains a surgical challenge and the results vary depending on the severity of the abnormal acetabular, femoral or combined deficiencies. Methods of reconstructing the acetabular deficiencies include bulk femoral head graft or impaction bone grafting and are associated with higher rates of failure. Hartofilakidis et al advocated cotyloplasty technique and they reported 93.2% survival

at 10 years. The best results have been reported when the cup is placed in the true acetabulum with medial wall has been maintained and no more than 5 mm of the cup or less than 30% has been left uncovered. We report the medium-term outcome of using a 15° face changing cup to achieve these principles in THA secondary to acetabular dysplasia.
Patients and methods: A total of 28 hips in 26 patients with secondary OA due to acetabular dysplasia who underwent total hip arthroplasty using 15° face changing cup between September 2009 and May 2007, with a minimum 5 years follow-up. There were 20 females and 6 males with a mean age of 52 years (range 33-68). All the operations were performed by either the consultant or senior hip fellows under direct supervision. Preoperatively radiographs showed a mean centre-edge angle of 19° (9-34°), Sharp's angle of 46° (39-51°) and femoral head extrusion of 32% (20-47%). Average pre-op Harris Hip Score was 43 (13-58) and the Oxford Hip Score 16.4 (12-39). There were 2 low dislocations in the series.
Procedure: A posterior approach was used in all cases. All patients received a cementless Exceed Advanced Bearing Technology (ABT) 15° face changing cup (Biomet UK Ltd, Bridgend, United Kingdom) with a ceramic liner. The shell can be placed in 60° of abduction angle, so that the porous coated surface is fully covered by the host bone which aligns the ceramic liner in the optimal position of 45° of abduction. An uncemented Taperloc (Biomet UK Ltd.) or an Exeter (Stryker UK Ltd.) stem with a 28 or 32 mm delta ceramic head articulating with the cup was used in all cases. None of the patients received any form of bone-grafts. All patients started full weight bearing the next day.
Results: Average clinical and radiological follow-up was for 60 months (36-76). The mean Harris Hip Score improved to 94 and the Oxford Hip Score improved to 44. There were no infections or dislocations in the series. There were 100% survivorship of the hip joint for either components. There was one incidence of sciatic nerve palsy with complete recovery within 3 months. Post opeative radiographs revealed good integration of the cup no evidence of loosening or osteolysis. The mean covered acetabular lip inclination angle was 51° (range 43-61°) and the true inclination angle of the bearing was 36° (28-46°).
Discussion: The clinical results support the use of the cementless 15° face changing acetabular cup in the dysplastic acetabulum. The principle of utilising the available cancellous bone for bony ingrowth is achieved in most situations by placing the shell at 60° of abduction instead of 45°. The design of the shell positions the liner at 15° less than the acetabular shell position, which facilitates the optimal positioning of the articular surfaces and provides fixation in the shallow native acetabulum with no need for a bone graft. However, this cup is not designed or recommended to treat cases of high dislocation with a poorly developed acetabulum.

SURVIVORSHIP OF TOTAL HIP ARTHROPLASTY FOLLOWED SCHANZ OSTEOTOMY IN HIGH-RIDING CONGENITAL HIP DISLOCATION PATIENTS. LONG-TERM FOLLOW-UP

Vahit Emre Ozden[1], Goksel Dikmen[1], Burak Beksac[2], I. Remzi Tozun[2]
[1]Department of Orthopaedics and Traumatology, Acibadem Maslak Hospital, Istanbul - Turkey; [2]Department of Orthopaedics and Traumatology, Acibadem Medical Faculty, Acibadem Maslak Hospital, Istanbul - Turkey

Introduction: High-riding congenital hip dislocation (HRCHD) patients are generally younger and expect an active lifestyle.
Objectives: To evaluate the effect of surface bearings on long-term clinical and radiological results of total hip arthroplasty in HRCHD patients who previously had a proximal femoral osteotomy.
Methods: The study included 28 total hip arthroplasties (THA) that were performed by single surgeon in 21 patients (7 bilateral, 21 unilateral) with a mean age 42.6 years (26-66), from 1993 through 2008. All patients had previous Schanz ostetomy before replacement. The acetabular cup was placed at the level of true bony acetabulum and a proximal step-cut shortening osteotomy of the femur was performed in all hips. The mean follow-up time was 11 years (5-21). Two surface bearings were used; CoCr on conventional polyethylene in 11 hips and ceramic-on-ceramic bearings in 17 hips. Patients were evaluated with physical examination, Harris Hip Scores (HHS), and direct radiography findings of acetabular and femoral component loosening or osteolysis at the last follow-up.
Results: There were no statistical differences for age, preoperative limb length discrepancy, amount of shortening, postoperative improvement of HSS between 2 surface bearings. Polyethylene bearings showed statistically higher acetabular revision rates than ceramic bearings ($p = 0.016$). Any revision due to osteolysis as the end point, the 14-year cumulative survivor rate of acetabular cups were 63.6% (95% CI, 51.9-89.9%) in polyethylene bearings and 100% in ceramic surfaces. Any revision as the end point, the 14- year cumulative survivor rate of femoral components were 72.7% (95% CI, 64.6-90%) in polyethylene bearings and 94.6% in ceramic bearings.
Conclusions: Longevity of components in THA followed Schanz osteotomy in DDH patients is important as the surgical technique and pitfalls for good to excellent results. Ceramic bearings showed higher survivor rate in these patients group.

Dual Mobility

DUAL MOBILITY SOCKET IN PATIENTS WITH INCREASED RISK OF DISLOCATION

Andrea Rossi, Daniele Munegato, Giovanni Zatti
Clinica Ortopedica, Ospedale San Gerardo, Monza - Italy

Introduction: Dual mobility socket was developed in the '70s by Gilles Bousqet trying to solve the problem of recurrent dislocation after total hip replacement. Bousqet's prosthesis design, following biarticular endoprosthesis, allows to combine minor dislocation risk with great range of movement through the application of 2 biomechanical principles: increasing jump distance, the distance you need to dislocate the implant, and the recruitment phenomenal, the late contact between neck and inlay which reduces impingement risk and increases range of motion.
Objectives: The aim of the study was to evaluate the effect of dual mobility socket to prevent dislocation in patients with increased risk of dislocation
Methods: Authors present clinical, radiological and functional results of a non consecutive series of 120 patients (47 male and 73 female), mean age was 77 years (range 58-84) with increased risk of dislocation, undergone total hip replacement using a dual mobility socket. Pre-operative diagnosis was primary and post traumatic arthritis of the hip (42 cases) and femural neck fractures (78 cases). Every surgical procedure was performed by a posterolateral approach. The series counts 80 non-cemented dual mobility sockets and 40 cemented cups, the uncemented stems were 64 while cement was used in 56 patients.
Every case has been evaluated after 1, 3 and six months from the implant and then annual control with x-ray exams and Harris Hip Score (HHS).
Mean follow-up is 3 years, with a range from 12 months to 6 years now.
Results: At the present moment we did not observe any dislocation with the dual mobility cup and no revision surgery due to accelerate liner consumption had been performed. We had 3 cases of aseptic loosening of the cup (2.5%), with no dislocation of the liner and the cup. We observed 1 single acetabular fracture with still no dislocation between the liner and the socket. No limb length discrepancy beyond 1 cm.
Conclusions: Through the analysis of the scientific papers and the study of comorbidity we identified patients with increased risk of dislocation following total hip arthroplasty: muscular diseases (muscolar insufficiency, sarcopeny), neurological diseases (cognitive impairment, neurodegenerative diseases like Parkinsons and Alzheimers, peripheral neuropathy), ligament laxity in Ehler-Danlos disease or the very old people with low rehabilitation compliance. Other factors increasing dislocation risk are the female gender, age >75 years, the posterolateral approach and the pre-op diagnosis of femoral neck fracture.
Results are encouraging us to pursue the use of dual mobility cup to prevent dislocation in patients with elevated risk as a first choice to avoid the unpleasant, for the patient and the surgeon, complication of dislocation.

DUAL MOBILITY CUP IS A RELIABLE CONCEPT IN PREVENTING DISLOCATION OF THA

Jan Milbrink, Nils Hailer
Department of Orthopaedics, University Hospital, Uppsal - Sweden

Introduction: Dislocation is the most common reason for early revision after total hip arthroplasty (THA). The incidence is estimated to be 1-3% after primary and around 10% after revision THA, and the risk increases further after isolated cup revision. Dual mobility (DM) cups were introduced in late '70s in order to reduce the risk of dislocation. At the University Hospital of Uppsala we use the DM concept in high risk primary THA (hip fracture, osteonecrosis, neuromuscular disorders, failed osteosynthesis), in the treatment of recurrent dislocations, and in challenging revision THA.
Objectives: We present a follow-up study of 612 primary and revision THA operated with a DM cup. The primary endpoint was the incidence of dislocations within the first 6 months.

Methods: The Avantage (Biomet) DM cup was used in all cases, and the majority of cups were cemented with Palacos R+G (Hereus). The patients were followed prospectively in our local arthroplasty register, and medical charts were reviewed to investigate whether patients had been readmitted due to THA dislocation.
Results: There was no early dislocation in the group of primary THA, neither in the group of patients with femoral neck fractures nor in the group of high-risk patients. There were 4 dislocations in the group of revision THA, and all were original stem retroversion in cases were isolated cup revisions had been performed. There were 10 deep infections, all in the revision THA group. So far, no aseptic loosening or macroscopically visible polyethylene wear was found after maximum 6 years. We found no disassembly of the metal head and the poly liner, which has been reported previously.
Conclusions: In this rather large series of primary and revision THA using DM cups dislocations were rare. The DM cup can be regarded as a valuable and safe tool in the prevention of dislocation after THA, especially in cases where there is a high risk of dislocation. However, questions remain with respect to future polyethylene wear, especially when using the DM concept in younger patients. Further studies with longer time follow-up are therefore necessary.

DUAL-MOBILITY CUP IN TOTAL HIP REVISION SURGERY. A PROSPECTIVE STUDY OF 79 PATIENTS: DISLOCATION RISK AND CUP FIXATION AT 2 YEARS FOLLOW-UP

Jean Louis Prudhon
Clinique des Cedres, Grenoble - France

Background purposes: Dislocation is a classical complication in total hip arthroplasty (THA) revision. Mid-term cup fixation is the second concern. Since 1998 we routinely use cementless dual-mobility cup (DMC) in revision surgery. In order to know outcomes at 2 years, we prospectively followed a prospective series of 78 patients treated in our institution. Purpose of this study is to demonstrate that DMC used in revision THA is safe as regards dislocation risk and bone fixation.
Material methods: From January 2010 to January 2012 we have collected a prospective cohort of 79 cases on 78 patients. Patients have been followed at our outpatient visit with a clinical and radiographical standard examination. Mean delay between index surgery and revision was12.9 years. Mean age at revision was75.5 years. Two different types of DMC were used. A standard DMC was used in 68 cases. If severe bone loss was detected, a specific design revision cup was used in 11 cases.
Results: At 2 years follow-up, 65 patients have been reviewed. Five patients are definitely lost to follow-up. Eight patients deceased at the end of the study. One patient dislocated her hip at 1 month. Two early mechanical failures occurred.
Discussion: Purpose of this short term follow-up study is to emphasise low risk of dislocation and trustable fixation of a cementless DMC used in revision THA. Our series participated in the series presented in the SoFCOT symposium in 2012 about causes of revision primary THA. Instability is the leading cause of failure. In our series dislocation rate is 1.2% at 2 years (100% of DMC). In the symposium series dislocation rate is 4% at 3 months (60% of DMC). Two patients presented an early mechanical cup failure. Mechanical failure rate is 2.5%.
Conclusions: Considering outcomes of this series, we may assess that in this particular indications, DMC can be recommended in THA revision surgery.

DUAL VERSUS MONO-MOBILITY CUP FOR DISLOCATION PREVENTION FOLLOWING REVISION THA

Amanda Gonzalez, Placido Bartolone, Anne Lübbeke, Robin Peter, Panayiotis Christofilopoulos, Pierre Hoffmeyer
University Hospitals of Geneva, Geneva - Switzerland

Introduction: Revision total hip arthroplasty (THA) is associated with higher dislocation rates than primary THA. The use of a dual-mobility cup in revision THAs surgery has shown in case series a decrease in dislocation rates.
Objective: To compare the risk for dislocation within 6 months (m), the risk for infection within 12 m and all cause revision after revision THAs with dual-mobility cup compared to revision THAs with mono-mobility cup.
Methods: We conducted a prospective cohort study including all THA revisions totally or only with the cup revised and performed from January 2004 to December 2012. The cups used for revision were either a dual-mobility or a mono-mobility; the choice was made according to surgeon's preference.
Results: Overall 250 revision THAs were included, 103 (41%) with dual-mobility cup (group 1), the mean follow-up (FU) was 33 m; and 147 (59%) with mono-mobility cup (group 2) and a mean FU of 49 m. At baseline the 2 groups (group 1 vs 2) differed in age at revision (75 vs 69 yrs.), comorbidities (16.5% vs 10.2% with diabetes) and indication for revision (34 vs 8.7% dislocation; 35 vs 59.2% aseptic loosening). A previous revision THA surgery already occurred in 31.1% in group 1 and 16.8% in group 2. The risk of dislocation was lower with the dual-mobility cup, respectively 1.9 and 8.2%. The number needed to treat to prevent 1 case of dislocation was 16. Risk for infection within 12 m was slightly lower in the mono-mobility group, unadjusted risk difference was 1.8, The survival at 60 months was similar in both groups, 91.4% respectively 93.1%.
Conclusions: Our study showed good short-term results with dual-mobility cup in revision THA compared to mono-mobility cup. The risk of dislocation was substantially lower in the dual-mobility group.

DOES THE DUAL-MOBILITY HIP PROSTHESIS PRODUCE BETTER JOINT MECHANICS DURING INCLINE WALKING TASKS?

Mario Lamontagne[1], Robert Little[1], Paul Beaulé[2], Sarah Reynolds[3]
[1]Department of Human Kinetics; [2]Department of Orthopaedic Surgery; [3]Human Movement Biomechanics Laboratory, University of Ottawa, Ottawa - Canada

Introduction: Dual-mobility (DM) hip prostheses have been shown to increase range of motion and reduce dislocations following total hip arthroplasty (THA); however, there are few comparisons between the DM prosthesis to conventional models (CC) during functional activities.
Objectives: To compare lower-limb gait patterns among THA patients with either a DM or CC prosthesis during inclined walking.
Methods: Gait analyses were conducted with 19 THA patients (DM = 9, CC = 10) at 1.0 ± 1.3 months pre-op and 6.2 ± 0.5 months post-op. Control participants (n = 10) were matched with THA participants for age and BMI. Motion analysis was conducted using 10 Vicon cameras and 2 force plates with a 4 metre walkway set at a 12.5% incline. Improvement scores for each surgical group were calculated using the RMSE between controls and THA patients for pre- and post-op gait parameters. Post-op RMSE values were subtracted from the pre-op RMSE to obtain an overall residual score (RS) for each THA group. Peak kinematic and kinetic values were also compared between surgical and control groups. All RS and peak value differences were compared with one-way ANOVAs.
Results: No significant differences were found between DM and CC groups for RS values. Both the DM and CC groups exhibited reduced peak hip extension angles compared to controls; however, this only reached significance ($p = 0.03$) for the DM group. Both DM and CC groups also had significantly smaller hip abduction angles ($p = 0.032$; $p = 0.028$ respectively) and abduction moments ($p = 0.3$, $p<0.01$respectively) compared to controls.
Both surgical groups had reduced peak knee flexion angles and moments, and significantly smaller abduction moments compared to controls.
Conclusions: Neither the CC nor DM prosthesis restored gait patterns to those of the control group at six months post-op. However, both groups exhibited similar improvements in gait mechanics. There may be further improvements after the 6-month point, which merits a longer-term analysis.

LOW EARLY COMPLICATION RATE WITH MODERN DUAL-MOBILITY HIP PROSTHESIS

Manoshi Bhowmik-Stoker[1], Kristin Robinson[2], Jim Nevelos[1], Kipling Sharpe[3], Geoffrey Westrich[4], Hanna Schlyter[5]
[1]Stryker Orthopaedics, Mahwah - USA; [2]Stryker, Mahwah - USA; [3]Banner Hospital, Mesa - USA; [4]Hospital for Special Surgery, New York - USA; [5]Stryker, Malmo - Sweden

Introduction: While dual-mobility bearings have been used in Europe for several decades, adoption is more recent in the USA. The purpose of this work was to investigate 3D jump height of a modern dual-mobility bearing in a computer model and report on early complications of patients with the same device in a clinical study.
Methods: The Posterior horizontal dislocation distance (PHDD) was measured as previously reported. The pelvis was oriented with 26° of pelvic tilt representing a low chair rise. Different cup orientations were tested for 4 different bearings: 1) 28 mm and 2) 36 mm convention bearings, 3) a resurfacing shell with a 3 mm offset bore, and 4) an ADM cup with a 54 mm outside diameter with a 48 mm mobile polyethylene insert with a 28 mm captured head.
A prospective, multicentre study was conducted. A total of 167 ADM acetabular with X3 polyethylene components (Stryker, Mahwah, NJ) were implanted. Adverse events (AEs) were recorded intra- and postoperative. Harris Hip Score (HHS), Lower Extremity Activity Scale (LEAS), Short Form-12 (SF) were collected at pre-op, 6 weeks and 1 year postoperative.

Results: The computer model showed that the 54 mm ADM cup had the highest PHDD in all orientations with double the PHDD compared to a 36 mm head with the cup oriented at 45°of inclination and 10° of anteversion.
Patient reported outcome measures indicated improvement in all pain and function scores at 1 year (mean HHS 94.8, LEAS 11, SF MCS 54.8, SF PCS 47.6). Two AEs resulted in revision or reoperation but the ADM shell was retained in both cases (1 subtrochanteric fracture, 1 periprosthetic calcar fracture).
Discussion: Early clinical data confirms that this dual-mobility bearing has a very low early complication rate without dislocations in this series.
Conclusions: The combination of highly cross linked polyethylene and a dual-mobility bearing may therefore provide a bearing with low wear and high stability in an American patient population.

SHORT TERM COMPLICATIONS AFTER REVISION HIP ARTHROPLASTY WITH A MODULAR DUAL-MOBILITY PROSTHESIS

Erik Schnaser, Geoffrey Westrich, Mathias Bostrom
Hospital For Special Surgery, New York, NY - USA

Introduction: Dual-mobility constructs have been used in Europe for several years. Due to their large jump distance, perceived enhanced stability, and modularity allowing multiple screw fixation, there has been significant interest for using these devices in a revision setting. These devices recently were approved in the United States and there is a paucity of information regarding their success in the revision setting.
Objectives: The main purpose of this study is to evaluate the short-term complications associated with the modular dual mobility (MDM) prosthesis used for revision total hip arthroplasty at a single institution.
Methods: We conducted a retrospective review of all revision procedures done at our institution using the MDM device (Stryker). Difficult total hip procedures such as fusion take downs, excision of heterotopic ossification, and hip fracture conversions with existing hardware were also included. All inpatient and outpatient records were reviewed for complications.
Results: Our institution began using MDM prosthesis in 2011. We identified 134 MDM prostheses used between 2011 and 2013 for revision hip arthroplasty. A total of 11 (8.2%) patients required further surgery after revision. The most common indication for further surgery was recurrent instability (n = 5, 3.7%), infection (n = 3, 2.2%), acetabular loosening (n = 2, 1.4%), and facial dehiscence (n = 1, 0.07%). The average follow-up was 7.7 months (range 0-30). The most common indication for revision was instability (n = 56). Two (3.5%) of the 56 patients who had pre-revision instability had postoperative instability and required further surgery.
Conclusions: The MDM prosthesis appears to have an acceptable short-term complication profile following revision total hip arthroplasty. When used in the setting of recurrent instability, the failure rate was observed to be very low (3.5%) compared to historical controls. These devices will need to be further monitored for long-term issues that may arise.

Particles

THE METAL-ON-METAL HIP REPLACEMENT RECALL - OUR EXPERIENCE WITH OVER 700 CASES

Nijil Lal Vasukutty[1], Vishal Rajput[1], Anees Shaikh[1], Chika Uzoigwe[2], Mandy Howes[1], Hasnat Minhas[1]
[1]Pilgrim Hospital, Boston - United Kingdom; [2]Leicester Royal Infirmary, Leicester - United Kingdom

Introduction: There has been widespread concern regarding adverse soft tissue reaction to metal debris (ARMD) after total hip replacement with metal-on-metal bearings. The Medicines and Healthcare Products Regulatory Agency (MHRA) of the UK have published guidelines for annual follow-up and ongoing care of these patients.
Methods: We are presenting our experience with 718 total hip replacements (594 stemmed hips and 124 resurfacing) with metal-on-metal bearing, implanted between April 1999 and August 2010. Patients were reviewed in dedicated clinics with clinical and radiological assessment along with assessment of serum metal ions. Magnetic Resonance Imaging was done as per MHRA guidelines. Survival was calculated using Kaplan Meier analysis.
Results: A total of 22 hips had already been revised at the start of recall. Mean follow-up was 108 months (180-44). Forty-four patients had deceased and 47 were lost to follow-up. 6% of patients had high metal ion levels and radiological analysis showed that 22% of cups were outside the Lewinnek's safe zone. Fifteen months into the recall process a total of 41 hips have been revised.
Discussion: Our revision rates are similar to that reported in literature thus far but this could be just the tip of the iceberg. Instability arising due to the extensive soft tissue damage seen in such patients could become a major concern and arthroplasty units should be prepared to deal with this.

CUP IMPINGEMENT AND WEAR DAMAGE WITH HIP RESURFACING IS SIMILAR TO THAT IN RETRIEVED TOTAL HIP ARTHROPLASTY

Alun John[1], Ian Clarke[2], Evert Smith[3], Thomas K. Donaldson[4], Christina Savisaar[5], John G. Bowsher[5]
[1]Department of Orthopaedics, University of Cardiff, Cardiff - United Kingdom; [2]Department of Orthopaedics, Loma Linda University, Loma Linda - USA; [3]Department of Orthopaedics, University of Bristol, Bristol - United Kingdom; [4]Empire Orthopaedics, Colton CA - United Kingdom; [5]Food and Drug Administration, Silver Spring MD - USA

Introduction: Femoral heads from metal-on-metal (MoM) retrievals in hip arthroplasty (THA) revealed stripe damage - created by cup rims during impingement/subluxation. Indications were that released metal particles provoked abrasive wear. Resurfacing arthroplasty (RSA) retains the natural neck and lacks modularity - thus should release minimal debris.
Objective: We compared wear damage on RSA to THA retrievals.
Materials: Twelve each RSA and THA were followed 1-6 years, as revised for pain, cup loosening. *in vivo* positioning was determined by wear patterns. Graphical models provided RSA geometry and revealed damage sites *in vivo*.
Results: Normal wear patterns were similar on RSA and THA heads, as were sites of polar stripes. RSA basal stripes had greater angulations as a consequence of thicker necks. However cup wear patterns and "edge wear" angles proved larger than for THA. Thus RSA impinged at extremes of motion similar to THA.
Discussion and conclusions: RSA and THA demonstrated similar evidence of normal and stripe wear. Impingement/subluxation effects were implicated– releasing CoCr particles to trigger 3rd-body wear. This explains why an RSA design could perform well in some cases for more than a decade and yet provoke aggressive articular reactions to metal debris (ARMD) with short follow-up.

METAL ION LEVELS AND FUNCTIONAL RESULTS FOLLOWING RESURFACING HIP ARTHROPLASTY VERSUS CONVENTIONAL HIP ARTHROPLASTY; 5-YEAR FOLLOW-UP OF A RANDOMISED CONTROLLED TRIAL

José Smolders, Pepijn Bisseling, Annemiek Hol, Job van Susante
Department of Orthopaedics, Rijnstate Hospital, Arnhem - The Netherlands

Introduction: Hip resurfacing arthroplasty (RHA) is an attractive treatment option for young patients, however concern for adverse soft tissue reactions from increased metal ion release has discredited its use.
Objectives: We present an update of a randomised controlled trial comparing RHA and a 28 mm total hip arthroplasty (THA).
Methods: A total of 71 patients (<65 years) were randomly assigned to receive either a RHA (n = 38) or cementless 28 mm metal on-metal MoM THA (n = 33). Cobalt and chromium levels and functional outcome scores were analysed preoperative and at 6, 12, 24, 36 and 60 months. Mean follow-up was 58 months (SD 8.1).
Results: All functional outcome scores improved highly significant for both groups. The median University of California at Los Angeles activity (UCLA) score and satisfaction were similar between groups after 24 months. Oxford Hip Score (OHS) remained slightly better for RHA patients at 24 and 36 months ($p<0.03$). Median cobalt and chromium remained below 1.3 µg/L throughout follow-up for unilateral implants in both groups. Chromium concentrations were significantly higher for RHA at all follow-up intervals, whereas cobalt concentrations were equalised for both groups after 36 months. Three revisions (1 MoM THA, 2 RHA) were performed for pseudotumour formation.
Conclusions: At 5-year follow-up no clear shifts in relatively good outcome was encountered between RHA and 28 mm MoM THA. Metal ion levels, cobalt in particular, appear to equalise between groups after 3 years. Revision surgery was performed occasionally for pseudotumour formation, this also applied to the MoM THA group. These results are relatively reassuring as compared to other more disturbing reports, the reason may be implant related.

LARGE VARIATION IN PSEUDOTUMOUR DEVELOPMENT AFTER METAL-ON-METAL HIP RESURFACING OBSERVED WITH THREE SEQUENTIAL MARS-MRIS

Walter van der Weegen[1], Jorgen Wullems[1], Koen Brakel[2], Peter Pilot[3], Dirk Das[1], Rob Nelissen[4]
[1]Department of Orthopaedic Surgery; [2]Department of Radiology, St Anna hospital, Geldrop - The Netherlands; [3]Department of Orthopaedic Surgery, Reinier de Graaf Gasthuis, Delft, Delft - The Netherlands; [4]Department of Orthopaedic Surgery, Leiden University, Leiden - The Netherlands

Introduction: Data on the natural course of unrevised pseudotumours after metal-on-metal (MoM) hip arthroplasty is scarce. Guidelines on treatment of patients diagnosed with a pseudotumour are still based on limited evidence and many patients are revised with usually only one cross-sectional investigation available. There are no studies reporting the natural course of pseudotumours after MoM hip arthroplasty with three MARS-MRI investigations over a course of 2 years.
Objectives: To describe the 2-year natural history of unrevised pseudotumours using 3 repeated MARS-MRI's for each case.
Methods: We prospectively followed up 18 MoM hip resurfacings (15 patients) diagnosed with a pseudotumour at baseline MARS-MRI, 4.4 years after index surgery. All patients are part of a larger cohort of patients. Based on clinical outcomes, metal-ion levels and MARS-MRI these patients were currently not considered for immediate revision surgery. Each case was followed with 2 subsequent MARS-MRI's, metal-ion analysis and clinical outcomes. Maximum pseudotumour size, pseudotumour details and position were recorded.
Results: Mean time to second MRI was 0.6 years and 1.1 years between second and third MRI. Ten different pseudotumour patterns were noted. Pseudotumour dimensions increased and then remained stable in 5 patients. Three pseudotumours did not show any change. Five pseudotumours showed a decrease in size between 2nd and 3th MRI. Each remaining pseudotumour (n = 5) showed a distinctly different pattern over time. One of these 5 pseudotumour increased and migrated on each MRI, created a fistula through the skin and was revised.
Conclusions: The natural course of pseudotumours observed with MARS-MRI shows a large variation with sometimes unexpected patterns. The decision to revise a MoM hip arthroplasty should not be based on patient review at a single time-point. Wait and see policy might be a good option before revision surgery is performed.

PSEUDOTUMORS ALSO A COMMON FINDING AFTER CONVENTIONAL CERAMIC-ON-POLYETHYLENE TOTAL HIP ARTHROPLASTIES (THA); AN MRI SCREENING IN A RANDOMISED CONTROLLED TRIAL OF RESURFACING AND METAL-ON-METAL (28 MM) THA VERSUS A MATCHED-CONTROL GROUP OF CERAMIC-ON-POLYETHYLENE THA

Pepijn Bisseling[1], Bart de Wit[2], Maarten van Gorp[2], Wim Schreurs[3], Job van Susante[1]
[1]Department of Orthopaedics; [2]Department of Radiology, Rijnstate Hospital, Arnhem - The Netherlands; [3]Department of Orthopaedics, Radboud University Medical Centre, Nijmegen - The Netherlands

Introduction: Numerous studies have reported on pseudotumour formation after resurfacing hip arthroplasty (RHA) and other metal-on-metal (MoM) THA. There is no consensus on the true prevalence and clinical relevance of these MRI findings.
Objectives: To determine the prevalence of pseudotumour formation in patients with a MoM hip arthroplasty (RHA versus 28 mm THA) from an ongoing randomised trial compared to the prevalence in a matched control group of asymptomatic patients with a ceramic-on-polyethylene (CoP) THA.
Methods: Patients from a trial comparing RHA (n = 38) versus MoM THA (n = 33) were screened with MARS-MRI for the presence of a pseudotumour at a mean follow-up of 55 months (40-72) according to 3 different MRI-classification systems. In addition, a matched control group of asymptomatic patients with a CoP (32 mm) THA (n = 33) were screened similarly. Metal ion levels and clinical scores were available for the MoM bearing patients at regular intervals.
Results: Six patients from the RHA group (16%), 1 patient in the MoM THA group (4%) and 6 patients in the CoP control group (18%) were diagnosed with a pseudotumour (mean volume 16 mL [1.5-35.9]). MRI sub-classification revealed pseudotumors grade II to V without clear differences between the groups. Two patients in the RHA group and 1 in the MoM THA group had been revised for a pseudotumour. Patients with a pseudotumour had a mean Harris Hip Score of 92 (59-100). Serum cobalt and chromium levels were 4.4 (0.6-21.2) and 3.9 (0.1-16.0) ng/mL. The differences with non-pseudotumour patients were non-significant.
Conclusions: On MRI screening pseudotumor formation is also a common finding after conventional CoP THA. In spite of the fact that pseudotumor formation after MoM hip arthroplasties remains a serious concern, MRI screening probably overestimates the prevalence of clinically significant pseudotumour formation after MoM hip arthroplasties. Care should be taken to avoid revision solely based on MRI findings.

REPEATED MAGNETIC RESONANCE IMAGING IN PATIENTS WITH LARGE-DIAMETER METAL-ON-METAL HIP REPLACEMENT

Aleksi Reito, Petra Elo, Timo Puolakka, Jorma Pajamäki, Jyrki Nieminen, Antti Eskelinen
Coxa Hospital for Joint Replacement, Tampere - Finland

Background and purpose: US Food and Drug Administration and UK Medicines and Health Regulation Agency recommend using MRI in the evaluation of patients with large diameter LD-MoM hips. Recommendations do not take into account relevance of repeated cross-sectional imaging. Our primary aims were 1) to investigate the natural course of pseudotumours (PTs) in patients with LD-MoM hip replacements who had not required revision surgery using MRI, and 2) to see whether any new PTs emerged in this cohort during the follow-up. Secondary aim was to report the temporal changes in these patients regarding MRI findings, clinical outcomes and whole blood (WB) chrome (Cr) and cobalt (Co) levels.
Methods: Of the 888 ASR patients (1036 hips) 674 patients (798 hips) have undergone 2 follow-up visits at our institution. Of these we identified 124 patients (154 hips) who had undergone repeated clinical assessment including MRI and WB metal ion assessment.
Results: A significant change in imaging findings between the two MRIs was seen in 17 of the 154 hips (11%). In 13 (8.4%) hips, a significant progression of the PT was evident, while in 4 (2.6%) hips there was a retrogressive change. Ten of the 13 hips with significant PT progression had normal first MRI. Seven of them revealed a cystic PT and 3 a thick-walled PT in the second scan. Patients with a progressive change in the scans did not differ from those without a significant change in MRI in respective to follow-up time, time interval between MRIs, or changes in WB Cr and Co levels between assessments.
Interpretation: As a conclusion, a significant change was rare considering that all patients had a clinical indication for repeated imaging. Progression of the findings does not seem to correlate clearly with symptoms or WB metal values although change in imaging finding was more prevalent in the latter group.

ARE ADVERSE REACTIONS TO METAL DEBRIS MORE COMMON AFTER METAL-ON-METAL TOTAL HIP ARTHROPLASTY THAN IN METAL-ON-METAL HIP RESURFACING? RESULTS FROM A LARGE MATCHED COHORT SCREENED WITH MRI

Dirk Das[1], Jorgen Wullems[2], Koen Brakel[3], Peter Pilot[4], Rob Nelissen[5], Walter van der Weegen[1]
[1]Department of Orthopaedic Surgery, [3]Department of Radiology, St Anna hospital, Geldrop - The Netherlands; [2]Department of Orthopaedic Surgery, Leiden University, Geldrop - The Netherlands; [4]Department of Orthopaedic Surgery, Reinier de Graaf Gasthuis, Delft - The Netherlands; [5]Department of Orthopaedic Surgery, Leiden University, Leiden - The Netherlands

Introduction: Both resurfacing and large diameter metal-on-metal (MoM) hip arthroplasties release metal ions. This metal ion release can lead to adverse reactions to metal debris (ARMD). ARMD risk might be higher for the large diameter MoM total hips (MoMTH), since additional metal ions might be released from the taper junction, which is absent in MoM hip resurfacing arthroplasty (MoMHRA). If there is increased risk, surveillance of MoMTHA might need to be more extensive than with MoMHRA.
Objective: To assess if ARMD, diagnosed using metal ion levels and MRI, is more common in large diameter MoMTH compared to MoMHRA from a large cohort of well documented patients from one single hospital.
Methods: All living non-revised MoMTH patients (34 hips) were matched for gender, follow-up (FU) (±0.5yr), age (±5yrs), head size (±1 sizes) and acetabular inclination (Risk +/-) by 1 observer, blinded to the clinical outcomes, from a large cohort of well-documented MoMresurf. Each MoMTH was matched with 2 MoMHRA cases. For each case clinical outcomes, metal-ion analysis and one MRI was available. Pseudotumour severity was graded using the Anderson classification.
Results: Gender distribution, mean FU, age, median femoral component size and cup inclination risk were identical between groups (MoMTHA: 59% females, mean FU 4.8yrs, mean age 57 years, 52 mm median head size, 35% cups >50^0.

MoMHRA: 62% females, mean FU years 4.7 years, mean age 55 years, 48 mm median head size and 54% cups >50^0. Median metal ion concentrations in the MoMTHA group for chromium were 57nmol/L and 40 nmol/L for Cobalt, compared to 40 nmol/L and 28 nmol/L in the MoMHRA group. In the MoMTHA group, 64% of all MRIs were normal (Anderson A), 18% showed a mild pseudotumour (Anderson C1) and 18% were moderate (Anderson C2). In the MoMHRA this was 66%, 25% and 9%. There was only one symptomatic MoMTHA (3%), compared to 11% in the MoMHRA group.
Conclusions: There were more symptomatic MoMHRA than MoMTHA cases but metal ion concentrations were higher in the MoMTHA group. Pseudotumour prevalence was equal in both groups, but there were more severe pseudotumours in the MoMTHA group.

METAL-ON-METAL DISEASE COURSE OBSERVED IN 111 HIP RESURFACINGS USING CLINICAL OUTCOMES, METAL ION LEVELS AND MRI AT TWO TIME POINTS

Walter van der Weegen[1], Koen Brakel[2], Peter Pilot[3], Henricus Das[1], Rob Nelissen[4]
[1]Department of Orthopaedic Surgery; [2]Department of Radiology, St Anna Hospital, Geldrop - The Netherlands; [3]Department of Orthopaedic Surgery, Reinier de Graaf Gasthuis, Delft, Delft - The Netherlands; [4]Department of Orthopaedic Surgery, Leiden University, Leiden - The Netherlands

Introduction: International guidelines on the optimal treatment of metal-on-metal (MoM) disease after hip arthroplasty are put forward by different organisations. Most important are clinical findings and metal ion analysis, with Metal-Artefact Reducing Sequence Magnetic Resonance Imaging (MARS-MRI) indicated for symptomatic patients. Evidence on how to follow-up diagnosed pseudotumours including the use of MRI is limited, since routine use of MRI would increase the burden on health care systems enormously. But data from sequential MRI results, combined with metal ion levels and clinical outcomes might assist in further developing guidelines for MoM disease.
Objectives: To present results of a large cohort (n = 11) MoM hip resurfacings followed up with MRI, metal ion levels and clinical outcome at 2 different timepoints.
Methods: Of a cohort of 243 hip resurfacings, at this time, 111 MoM hip resurfacings were available (97 patients) with clinical outcome, metal ions and MRI at 2 time points. A total of 78 had pseudotumour formation (70.3%) with first MRI. The Anderson classification was used to grade MRI results. We compared differences in pseudotumor severity, metal ion concentrations and clinical outcomes between 2 time points.
Results: Mean time between first and second MRI was 11 months. A total of 81 patients had no change in pseudotumour severity (73%), 8 increased (7.2%) and 22 decreased (19.8%) on MRI. Of these, 7 (6.3%) were a new pseudotumour observed with second MRI. Chromium concentration decreased 36.7% in the group which had stable MRI findings (similar Anderson score), increased 6.1% in the group with better Anderson score, and increased 20.2% in the group with a worse Anderson score.
Conclusions: Although the majority of pseudotumours remain stable, we detected 6.3% new cases with repeated MRI at 1-year follow-up. A higher percentage showed decrease in pseudotumour severity rather than increase. Using change in metal ions to monitor MoM disease might be of limited value.

A RANDOMISED CONTROLLED TRIAL COMPARING WEAR OF OXIDISED ZIRCONIUM AND COBALT-CHROME ON STANDARD AND CROSS-LINKED POLYETHYLENE

Zachary Morison[1], Sunit Patil[2], Habeeb Khan[3], Earl Bogoch[4], Emil Schemitsch[4], James Waddell[4]
[1]Orthopaedic Research, [3]Division of Orthopaedics, St. Michael's Hospital, Toronto - Canada; [2]University Hospital of Coventry and Warwickshire, Coventry - United Kingdom; [4]Division of Orthopaedic Surgery, University of Toronto, Toronto - Canada

Introduction: Bearing surface wear remains a barrier to long-term success of hip arthroplasty.
Objectives: To investigate 4 bearing surfaces in total hip replacement surgery.
Methods: A total of 91 hip arthroplasties done between November 2004 and October 2007 were randomised: 1) cobalt-chrome (CoCr) and standard polyethylene, 2) CoCr and XLPE, 3) Oxinium and standard polyethylene, 4) Oxinium and XLPE. All patients received identical components with 28 mm heads. Radiographs were taken at each follow-up visit and wear was measured in a blinded fashion.
Results: A total of 42 men and 38 women participated; mean age was 52 years (range 22-67). The mean follow-up was 6.8 years (range 2-8.3). There were no differences in the SF-12 or WOMAC scores. The linear wear rate for groups 1 and 2 were 0.241 mm/yr and 0.076 mm/yr respectively (p = 0.00) and groups 3 and 4 were 0.238 mm/yr and 0.061 mm/yr (p = 0.00). There was no statistical difference in wear rates between Oxinium and CoCr when used with the same polyethylene liner (p>0.24). There was no correlation between abduction angle and wear (r < 0.2).
Conclusions: There is a significant difference in the linear wear rate between cohorts with the UHMWPE and HXLPE. There was no difference in wear rates between head types.

SYSTEMIC METAL ION LEVELS IN PATIENTS WITH MODULAR NECK TOTAL HIP ARTHROPLASTIES: A PROSPECTIVE COHORT STUDY

Jonathan Laurençon[1], Georgios Gkagkalis[1], Marc Augsburger[2], Hassen Hassani[1], Fabio Becce[3], Hannes A. Rüdiger[1]
[1]Department of Orthopaedics; [3]Department of Radiology, University of Lausanne - CHUV, Lausanne - Switzerland; [2]Department of Toxicology and Forensic Chemistry, Centre Hospitalier Universtaire Vaudois CHUV, Lausanne - Switzerland

Background: Modular-neck stems are prone to corrosion-related complications. Recent studies showed elevated metal ions levels and occasional pseudotumour formation in patients with such implants.
The purpose of this study was to compare systemic metal ion levels in patients after primary THA with modular neck stems to those of patients after non-modular implants. To our knowledge, this is the first cohort study including a control group, THA without CoCr heads and dry-assembled neck-stem connections.
Methods: A total of 50 patients after THA at a minimum follow-up of 1 year have been selected for the study. Patients with multiple prosthesis or other implants have been deselected. A cementless SPS stem from Symbios (Ti6Al4V) was used in all cases (40 modular, 10 non-modular). A ceramic head was used in all cases to minimise other sources of CoCr ion release. In the modular group, the neck was chosen preoperatively based on a 3D planning, allowing for a dry assembly of the stem and neck on the back table before implantation. Complete elementary quantification was performed separately in blood and serum.
Results: Mean cobalt serum levels were 1.54 µg/L in the modular group vs. 32 µg/L in the monobloc group (p<.001). Respective values for Cr, Ti and Mo were 1.12 µg/L, 31 µg/L and.96 µg/L in the modular group vs.60 µg/L, 22 µg/L and.74 µg/L in the monobloc group (p for Cr and Ti <.001, for Mo p = .254). Whole blood levels were comparable to serum levels.
2/40 patients had Co levels above 7 µg/L and 11/40 were above 1 µg/L, which is by some considered as relevant. No difference was found in terms of neck geometry (e.g. short vs long necks).
Conclusions: Serum levels of Co, Cr and Ti ions were significantly higher in patients with modular neck stems compared to patients with monobloc stems. These results have contributed to our decision to abandon the use of modular neck stems. Routine follow-up including annual measurements of serum Co Cr concentrations should be considered.

INFLUENCE OF FLUID-FILLED METAL CUPS ON A SECURE CONICAL FIXATION IN MODULAR ACETABULAR SYSTEMS DURING HIP SURGERY

Thomas Pandorf, Hendrik Bertmaring
CeramTec GmbH, Plochingen - Germany

Introduction: In order to obtain a secure taper connection every surgeon is advised to clean and dry the metal cup before assembling a ceramic insert. A slight axial tap using a plastic impactor completes the insertion.
There are a few reported cases that the taper connection failed intraoperatively although it was inserted and impacted as recommended. A conceivable reason seems to be a high amount of fluid in the gap between insert and cup preventing the insert from being securely fixed.
Objectives: The investigations have been performed in order to determine to what fluid content in a metal cup ceramic inserts may be safely implanted.
Methods: Cups embedded in a cast resin have been used in an appropriate impaction test setup. Four different amounts of 1.75% polyvinyl pyrrolidone solution with comparable viscosity to that of blood were filled into the metal cups. Three different *in vivo* like test conditions were considered: The fluid
cannot escape from the gap;
can permeate through a low permeable screen cloth;
can permeate through a high permeable screen cloth.
To assess the connection strength after impaction, the push-out forces have been measured.

Results: The values of condition 1 showed higher impaction forces at higher fill levels. In contrast, the values for condition 3 decrease at a higher fill rate (100%, p = 0.03). The standard deviations of the impaction forces increased with increasing fill level.
At 90% and 100% fill level the push-out forces were very low. Condition 1 even showed a push-out force of 0N (fill rate 100%). All values also showed very high standard deviations.
Conclusions: The results show that a low level of fluid only has a minor influence on impaction and push-out forces. The results also show that impacting against a high level of fluid (fill rate 90-100%) will not lead to a sufficient connection strength. The possibility of drain through the cup holes reduces the risk of insecure connection strength.
In conclusion, it is necessary to clean and dry the cup intraoperatively before assembling the insert. Additionally, or proper handling of the ceramic components, the Instructions for Use of the manufacturer have to be followed.

The 9 Best Abstracts

OSTEOCLASTOGENESIS-RELATED CYTOKINES IN REVISION METAL-ON-METAL TOTAL HIP REPLACEMENT; COMPARISONS BETWEEN PATIENTS WITH AND WITHOUT PERI-PROSTHETIC OSTEOLYSIS

Sarah Eastwood[1], Alun John[1], Stephen Jones[1], Helen Hodgson[1], Debbie Mason[2], Rachel Waddington[3], Xiaoqing Wei[3]
[1]Department of Trauma and Orthopaedics, University Hospital of Wales, Cardiff - United Kingdom; [2]School of Biosciences, Cardiff University, Cardiff - United Kingdom; [3]Tissue Engineering and Reparative Dentistry, Cardiff University, Cardiff - United Kingdom

Introduction: A variety of cytokines have been identified that may have a role in the pathogenesis of peri-prosthetic osteolysis. Adverse reactions to metal ions from metal-on-metal (MoM) total hip replacements (THR) have caused an increase in revision procedures. As well as adverse metal reactions, radiographic evidence of peri-prosthetic osteolysis is seen in some patients.
Objectives: This study aimed to analyse levels of osteoclastogenesis-related cytokines in the serum and synovial fluid (SF) of patients with and without osteolysis undergoing revision MOM THR.
Methods: Serum and SF samples had been obtained at revision of a unilateral MOM THR. The cytokines IL-6, IL-18, M-CSF, sRANKL and OPG were measured by sandwich ELISA. Preoperative x-rays were reviewed for osteolysis around either component. Results were analysed with linear regression and *t*-tests.
Results: Samples from 36 patients (18 with osteolysis, 18 without osteolysis) were analysed. There was wide variation in the detectable levels of cytokines; only IL-6 and OPG were detected in all SF samples and only OPG in all serum samples. IL-6, IL-18 and M-CSF were detected in few serum samples (across both groups). No significant differences were seen between patients with and without osteolysis in mean SF levels of IL-6 (p = 0.863), IL-18 (p = 0.324), M-CSF (p = 0.508), sRANKL (p = 0.884), OPG (p = 0.776) or mean serum OPG (p = 0.993) or sRANKL (p = 0.565) levels. A correlation was found between SF IL-6 and OPG levels in patients without osteolysis (r^2 = 0.618, p<0.001) but not with osteolysis (r^2 = 0.0004).
Conclusions: Previous research has found increased levels of some cytokines associated with peri-prosthetic osteolysis. This study has compared levels of 5 cytokines between patients with and without osteolysis undergoing revision MOM THR. No significant differences were found. This may indicate that these cytokines are not major determinants of peri-prosthetic osteolysis. Further research is needed to clarify this.

PLATELET-RICH PLASMA IS MORE EFFECTIVE FOR CHRONIC SEVERE GREATER TROCHANTERIC BURSITIS THAN CORTISONE

Raymond Monto
Nantucket Cottage Hospital, Nantucket, Massachusetts - USA

Introduction: Chronic greater trochanteric bursitis is a common but sometimes difficult condition to successfully treat. Platelet rich plasma (PRP), a concentrated bioactive component of autologous blood that is rich in cytokines and other growth factors, was compared with cortisone injection in the treatment of severe cases of greater trochanteric bursitis resistant to traditional non-operative paradigms.
Methods: Forty patients (12 males, 28 females) with severe chronic greater trochanteric bursitis who had failed a minimum of 6 months of traditional non-operative treatment (rest, PT, NSAIDS, local modalities) were randomised into 2 study groups and blindly evaluated prospectively. All patients had pre-treatment MRI and ultrasound studies consistent with greater trochanteric bursitis. Group 1 was treated with a single ultrasound-guided injection of 40 mg methylprednisolone at the injury site and Group 2 was treated with a single ultrasound-guided injection of autologous PRP at the injury site. All patients were allowed to immediately return to normal activities as tolerated and without support.
Results: Group 1 (steroid) had 7 males and 13 females with an average age of 64 (43-74) and had failed 10 months (6-21) of standard non-operative management and had pre-treatment Harris Hip Scores of 52 (43-54) and WOMAC scores of 58 (54-66). Group 2 (PRP) had 5 males and 15 females an average age of 66 (47-77) and had failed 11 months (7-33) of standard non-operative management and had pre-treatment Harris scores of 51 (49-53) and WOMAC scores of 59 (55-61). Post-treatment HHS in Group 1 initially improved to 75 (62-84) and WOMAC scores of 83 (61-87) at 3 months but decreased at 6 months to HHS of 68 (54-84) and WOMAC scores of 74 (61-83) and dropped further to near baseline HHS of 59 (53-77) and WOMAC scores of 63 (58-79) at 12 months follow-up. Post-treatment clinical scores in Group 2 were much better with HHS of 84 (77-92) and WOMAC scores of 91 (80-97) at 3 months, HHS of 87 (82-92) and WOMAC scores of 90 (83-97) at 6months and had HHS of 87 (81-92) WOMAC scores of 89 at 12 months follow-up (83-96) (CI 95% p = 0.001). No patients were lost to follow-up.
Discussion and Conclusions: This level 1 study suggests that platelet rich plasma injection is significantly more effective and durable than cortisone injection for the treatment of severe chronic greater trochanteric bursitis refractory to traditional non-operative management.

RADIOGRAPHIC AND CLINICAL RISK FACTORS FOR THE EXTENT OF LABRAL INJURY AT THE TIME OF HIP ARTHROSCOPY

John Redmond[1], Jon Hammarstedt[1], Christine Stake[1], Kevin Dunne[1], Benjamin Domb[2], Sivashankar Chandresekaran[1]
[1]American Hip Institute, Westmont - USA; [2]Hinsdale Orthopaedics/American Hip Institute, Westmont - USA

Background: Femoroacetabular impingement and dysplasia are morphologic bony abnormalities that often lead to hip pain in young adults. Early chondrolabral damage precedes joint space narrowing, and multiple radiographic parameters have been proposed as possible predictors of chondrolabral injury.
Objective: The purpose of this study was to investigate the influence of multiple clinical and radiographic findings related to the amount of chondrolabral injury identified at the time of hip arthroscopy.
Materials and methods: At the time of surgery labral tear size was documented for 402 patients using traditional acetabular clock face nomenclature for sizing. A multivariate logistic regression was then performed to assess the correlation of radiographic and demographic findings with the size of the labral tear.
Results: Multivariate regression analysis displayed statistical significance for gender, age, alpha angle, Tönnis grade, and neck-shaft angle with labral tear size. No correlation between labral tear size was seen for LCEA, ACEA, acetabular inclination, or extent of crossover sign.
Conclusions: Predictors identified related to extent of labral injury were male gender, age, and alpha angle. Labral tears were larger in females with higher Tönnis grades and lower neck shaft angles. Measurements of acetabular coverage and version showed no correlation with labral tear size.

FACTORS THAT INFLUENCE TAPER CORROSION: LEARNING FROM A 18-YEAR RETRIEVAL DATABASE

Jacob Cartner, Patrick Aldinger, Chenxi Li, Megan Fessenden
Smith & Nephew, Memphis - USA

Introduction: The use of tapered junctions in primary hip arthroplasty has excellent long-term results. The prevalence of larger heads, coupled with recent findings regarding corrosion artifacts at tapered surfaces, has spurred growing interest. Visual and quantitative scoring methods have been used to assess the level of fretting and corrosion of tapered junctions.
Objectives: The purpose of this study was to determine if correlations exist between severity of corrosion artifacts and head size, head offset, time *in vivo*, or head material in an 18-year retrieval database.
Methods: Retrieved hip arthroplasty devices with Cobalt-Chromium-Molybdenum (CoCrMo) or Oxidised Zirconium (OxZr) femoral heads revised from 1997 to 2014 were investigated. Tapered surfaces were scored independently according to the Goldberg Score (GS). Exclusion criteria included less than 1 week *in vivo*, ceramic taper, and modular proximal stem sleeves. Vertical straightness

profile (VSP) measurements were taken by measuring depth of material loss. For each measured taper, 8 vertical straightness profiles were taken at 45° intervals around the circumference.
Results: A total of 204 retrievals met the inclusion criteria (CoCrMo, n = 166; OxZr, n = 37). Time *in vivo* ranged from 1 week to 10 years. There were 103 heads 36 mm or greater. Head size did not correlate to higher GS (n = 196, R^2 = 0.24). There was a parabolic correlation between head offset and GS (n = 169, R^2 = 0.88), with the more negative and positive offsets exhibiting higher scores. There was no correlation between time *in vivo* and GS (n = 114, R^2 = 0.10). There was a correlation between head material and GS, with OxZr having a lower score as compared to CoCrMo heads (1.8 ± 0.6 vs 2.5 ± 0.9, p<0.001). VSP measurements were taken on heads with a GS of 3 (CoCrMo, n = 20; OxZr, n = 3) and 4 (CoCrMo, n = 5; OxZr, n = 0). Measureable material loss was found on 13 heads (CoCrMo, n = 13; OxZr, n = 0). Maximum material loss for CoCrMo heads ranged from 1 to 103 µm. There was a general trend that tapers with a higher GS had a higher maximum depth of material loss on average (GS:3 = 2 µm, GS:4 = 29 µm).
Conclusions: CoCrMo heads have 20+ years of clinical success, but as shown in this study are still associated with quantifiable taper corrosion. Though impaction force, taper cleanliness, patient factors and other myriad multi-factorial issues may contribute to taper corrosion, in this study no correlation was observed for head size or time *in vivo* and corrosion. An OxZr head material exhibited decreased corrosion as compared to CoCrMo heads.

OXINIUM BEARING SURFACE COUPLING IN TOTAL HIP ARTHROPLASTY. A 10-YEAR PROSPECTIVE *IN VIVO* WEAR STUDY

Theofilos Karachalios, G. Karydakis
Orthopaedic Department of University of Thessalia Centre of Biomedical Sciences (CERETETH), Larissa - Greece

Wear of conventional bearing surfaces in THA is a major problem. New alternative bearing surfaces are now available such as metal-on-metal, ceramic-on-ceramic and new ceramic materials on highly cross-linked polyethylene. In a prospective randomised trial we compare *in vivo* wear of new bearing surfaces of ceramic and polyethylene. From March 2003 to September 2006, 202 patients (244 hips), 65 men and 137 women, underwent THA for hip osteoarthritis. In all patients a Synergy stem and a Reflection cup had been implanted. Patients were randomly divided into 5 groups: Group A ceramic on PE (48 hips), Group B ceramic on XLPE (50 hips), Group C oxinium (28mm) on XPLE (50 hips), Group D oxinium (32 mm) on XLPE (46 hips) and Group E ceramic on ceramic (50 hips). All patients were followed up prospectively (pre and postoperatively in 3 and 6 weeks, 3 and 6 months, 1 year and then every year) by the registration of subjective and objective scales of clinical outcome and an objective system of radiological evaluation. Additionally, the computerised system Polyware® was used to evaluate the wear of polyethylene in standardised A-P pelvic radiographs.
When we evaluated the parameters 2D linear wear (mm), 3D volumetric wear (mm3) and 3D volumetric wear rate, an initial bedding in phenomenon with increased wear was observed in all groups. At 10 years ceramic on PE showed comparable wear to historical controls, ceramic on XLPE showed unexpectedly high wear and both oxinium heads showed satisfactory wear rates. 3D volumetric wear rate following bedding in oxinium on XLPE showed the lowest (s.s.) wear rates which were better (s.s.) than ceramic on PE (Fig. 1).

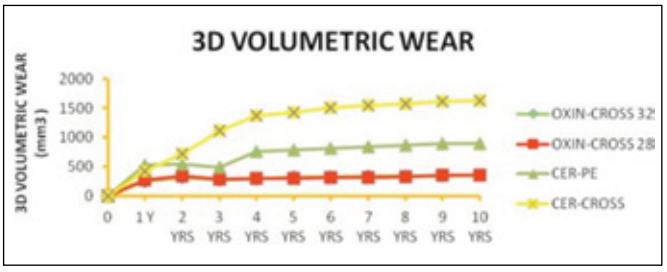

Fig. 1 - *No differences between the 2 sizes of oxinium heads were found. Polyware failed to calculate wear rates when ceramic on ceramic couplings were used. In conclusion, after the second postoperative year, the wear rate of oxinium on highly cross-linked polyethylene was estimated at the lowest level amongst the bearing surfaces tested.*

THE RESULT OF TRANSMUSCULAR VERSUS TRANSOSSEOUS REPAIR OF THE POSTERIOR CAPSULE ON EARLY DISLOCATIONS IN PRIMARY TOTAL HIP ARTHROPLASTY

Elsa Spaans, Joost van den Hout, Stefan Bolder
Department of Orthopaedic Surgery, Amphia Hospital, Breda - The Netherlands

Introduction: Dislocation is a concerning complication of the posterolateral approach for total hip arthroplasties (THA). Use of a larger size femoral head and a correct repair of the posterior structures can reduce the risk on dislocation of the hip prosthesis.
Objectives: To investigate if there is a difference in dislocation rate between transmuscular and transosseous repair of the posterior soft tissues with use of 36 mm heads.
Methods: A power analysis showed that in a comparable study with standardised effect size of 0.3, each group should include at least 174 patients. In the period of January 2010 until December 2011, 465 consecutive primary THAs with a posterolateral approach were performed in patients with primary osteoarthritis by 3 orthopaedic surgeons. A total of 246 patients were operated using transmuscular repair, the other 219 by using transosseous repair. All patients were given the same prostheses.
Results: Dislocation rate was 1.7% in all patients with at least 1-year follow-up. No significant difference was found in dislocation between both reconstruction techniques. Clinical outcome scores were comparable between the groups.
Conclusions: After 1-year follow-up and with use of a posterolateral approach, the risk of dislocation in 36 mm femoral heads is lower than reported values in previous studies which used smaller femoral heads. Transosseous and transmuscular repair were equally effective techniques in closing the posterior soft tissues after THA through the posterolateral approach, without difference in complication rate.

PRESENCE OF ACETABULAR DYSPLASIA INCREASES RISK FOR MALPOSITIONING OF THE ACETABULAR COMPONENT IN PRIMARY HIP ARTHROPLASTY

Kirill Gromov[1], Meridith Greene[2], Christopher Barr[2], James Huddleston[3], Roger Emerson[4], Eduardo Garcia-Cimbrelo[5], Peter Gebuhr[1], Henrik Malchau[2], Anders Troelsen[1]
[1]Department of Orthopaedic Surgery, Copenhagen University Hospital Hvidovre, Copenhagen - Denmark; [2]Harris Orthopaedic Laboratory, Massachusetts General Hospital, Boston - USA; [3]Department of Orthopaedic Surgery, Stanford University Medical Center, Standford - USA; [4]Texas center for Joint Replacement, Plano - USA; [5]Department of Orthopaedics, Hospital La Paz, Madrid - Spain

Introduction: Correct placement of the acetabular component in primary THA plays a significant role and is important for long-term survival, as malpositioning of the acetabular component have been linked to higher rates of wear, dislocation and impingement. Persistent acetabular dysplasia (AD) following periacetabular osteotomy (PAO) has been hypothesised to increase the risk for malpositioning of the acetabular component.
The purpose of this study was to investigate: a) whether acetabular dysplasia is a risk factor for cup malpositioning; and b) other independent risk factors for malpositioning of the cup.
Methods: A total of 945 patients from 16 centres in the USA and Europe are enrolled into a prospective 10-year outcome study. All patients were operated using an uncemented RingLoc® or Regenerex® cup and a Biomet® stem of surgeons choice. A total of 839 patients had pre- and postoperative pelvic AP radiographs, and were included in this study. Presence of AD was assessed by measuring lateral centre-edge (LCE) angle. AD was defined as LCE >25°. Osteoarthritis (OA) was determined as Joint Space Width (JSW). Cup positioning was determined on postoperative AP pelvic images using Martell Hip Analysis Suite. Acceptable ranges were defined as 30-45° abduction and 5-25°version.
Results: A total of 507 (60%) acetabular cups were within the abduction range, 474 (56%) were within the version range and 296 (35%) were within the range of both. Skin approach, presence of AD and JSW >0 independently predicted malposition of the acetabular component.
Skin approach (direct lateral vs posterolateral), JSW >0 and AD resulted in 1.77 fold (1.07-2.93), 1.43 fold (1.03-1.99) and 1.59 fold (1.17-2.15), increase in risk for malposition of the acetabular component, respectively.
Conclusions: Presence of AD, defined as LCE angle >25°, is an independent risk factor for malposition of the acetabular component during primary THA. Skin approach and radiological grade of OA were also independently correlated to malpositioned cups.

HIGH PROXIMAL MIGRATION OF THE REVISED ACETABULAR COMPONENT PREDICTS ASEPTIC LOOSENING, 352 ACETABULAR REVISIONS FOLLOWED 2-20 YEARS

Tina Klerken, Maziar Mohaddes, Johan Kärrholm
Department of Orthopaedics, Sahlgrenska University Hospital, Gothenburg - Sweden

Introduction: Radiostereometric analysis (RSA) allows precise and accurate measurements of early prosthetic movements (Kärrholm et al 1994). In a recent meta-analysis, Pijls et al (2012) concluded that every mm of proximal migration increases the risk of revision by 10% in primary cups.
Objective: In this study we aimed to evaluate the influence of early proximal migration of the revised acetabular component on the risk of late cup loosening.
Patients and methods: A total of 312 patients (352 hips), 125 males and 187 females, operated with acetabular revision surgery between June 1993 and December 2011, with a minimum of 2 years follow-up, were included in this analysis. The mean age was 65 (33-87) years. The endpoint of the study was death (n = 72), exchange or removal of the cup (re-revision, n = 45). The mean follow-up was 8.3 years. The proximal migration measured at 6 months, 1 year and 2 years postoperatively were analysed respectively. Cox regression analyses adjusted for different covariates were performed. Aseptic cup loosening, defined as re-revision due to loosening or radiological loosening, was used as end-point.
Results: The risk for aseptic loosening increased with 40% (relative risk [RR] = 1.39; 95% confidence interval [C.I.]: 1.09-1.77) for every mm of proximal migration recorded at 6 months postoperative. This increased risk was not significantly altered after adjusting for covariates (RR = 1.37, C.I.: 1.03-1.80). Corresponding adjusted/unadjusted values for 1 year and 2 years postoperative were: (RR = 1.99, CI 1.56-2.54)/(RR = 2.54, CI 1.83-3.53) and (RR = 1.35, CI 1.21-1.51)/(RR = 1.49, CI 1.29-1.73).
Conclusions: Proximal migration of the cup, measured with RSA, during the first 2 postoperative years is a predictor of later aseptic loosening of the acetabular component. Based on our findings we suggest that RSA should be considered as one of the first steps in quality assessment of new implants used in acetabular revision surgery.

SKIN STAPLES VERSUS SUBCUTICULAR WOUND CLOSURE FOLLOWING PRIMARY HIP ARTHROPLASTY: A PROSPECTIVE, RANDOMISED TRIAL INCLUDING 231 CASES

Martin Buttaro, Mauricio Quinteros, Gabriel Martorell, Fernando Comba, Gerardo Zanotti, Francisco Piccaluga
Hospital Italiano de Buenos Aires, Buenos Aires - Argentina

Introduction: Subcuticular wound closure is controversial in primary total hip arthroplasty. Randomised, controlled trials in wound closure following a total hip arthroplasty (THA) are scarce.
Objectives: Our hypothesis was that skin staples closure would be related to a similar complication rate as subcuticular closure with polypropilene.
Methods: From September 2011 to May 2012, 231 THAs in 219 patients with an average age of 62 years old (range 21-91) were performed. No differences were observed in both groups according to sex, age, BMI and comorbidities (p = 0.82). Cases were divided into 3 groups according to medical factors that influence wound healing: group 1 (no medical history, 70.5%), group 2 (diabetes, tobacco, obesity, corticoids, rheumatoid disease, 25%) and group 3 (organ transplantation, neoplastic patients or 2 or factors of group 2, 4.5%). Once randomised using a computer-generated method, all patients remained within the group to which they were allocated to wound closure with skin staples (Leukosan® SkinStapler PTW-35, BSN, Germany) that were used in 112 THAs in 105 patients (48%), or continuous 3.0 subcuticular non-absorbable polypropylene suture (Prolene™ 0, Ethicon Inc. Somerville, New Jersey, USA) in 119 THAs in 115 patients (52%).
Results: A 3.8% wound complication rate was observed in this series, with a 2.1% complication rate for the group that was closed with skin staples and a 1.7% rate for the group with subcuticular suture (p = 0.7). All the complications were treated conservatively except for one acute deep infection (0.4%) that was successfully treated with debridement, component retention and intravenous antibiotics. There were no differences in both groups related to operative time or wound length.
Conclusions: In these series of primary elective THAs, skin staples were associated to a similar complication rate as subcuticular closure.

Authors Index